18th International Congress of Anesthesiology, Critical Care and Pain

Common and Rare Complications of Labor Analgesia

Dr.Alireza Kamali

Professor of Anesthesiology · Arak University of Medical Sciences

18–20 November 2026 · Tehran, Iran · From Innovation to Resilience



- Arak University of Medical Sciences
- Professoer of Anesthesiology

1. Neuraxial Labor Analgesia: Anatomy and Technique

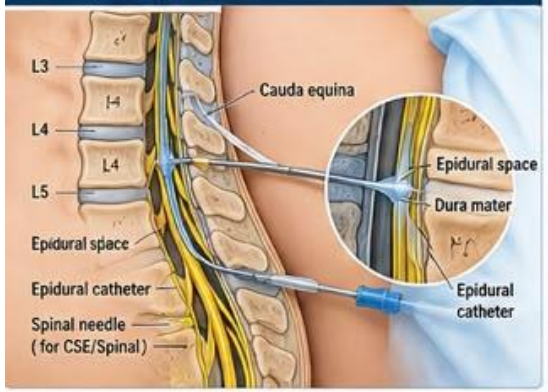

2. Common Complications – Overview



- Maternal hypotension
- Nausea and vomiting
- Pruritus
- Urinary retention
- Fever (intrapartum)
- Motor block
- Prolonged second stage of labor
- Instrumental delivery (in some studies)

3. Maternal Hypotension



Incidence: 10–30%

Sympathetic blockade (↓ SVR, venous pooling)

↓

Maternal hypotension

↓

Decreased uteroplacental perfusion

↓

Fetal consequences (bradycardia, acidosis)

4. Urinary Retention



Incidence: 5–15%

- Due to autonomic blockade (↓ bladder sensaation and detrusor contraction)
- Risk factors: high block, prolonged labor, opioid use, instrumental delivery

5. Pruritus, Nausea and Vomiting



- Pruritus: 10–30% (more with neuraxial opioids, e.g., fentanyl, morphine)
- Nausea and vomiting: 5–15% (often related to hypotension or opioids)
- Usually self-limited and mild

6. Intrapartum Fever



Incidence: 15–25%

- Sterile inflammatory response
- Not usually due to infection
- Associated with longer labor and higher rate of antibiotic use and cesarean delivery

7. Post-Dural Puncture Headache (PDPH)



Incidence: 0.1–1% (higher with large needles)

- Postural headache (worse sitting/standing, improves lying down)
- May be associated with neck stiffness, tinnitus, photophobia
- Treatment: conservative (fluids, caffeine, analgesics) or epidural blood patch

8. High or Total Spinal Block (Rare)



Incidence: < 0.1%

- Extensive cephalad spread of local anesthetic
- Profound motor and sensory block
- Hypotension, bradycardia
- Respiratory failure
- Loss of consciousness

Requires immediate airway management and hemodynamic support

9. Local Anesthetic Systemic Toxicity (LAST)

Incidence: < 0.1% (but potentially fatal)

Early CNS symptoms
- Perioral numbness
- Tinnitus
- Metallic taste
- Agitation, seizures

Cardiovascular toxicity
- Arrhythmias
- Myocardial depression
- Cardiac arrest

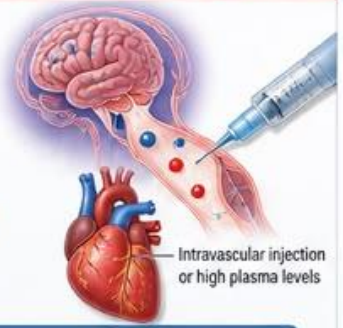

Treatment: immediate lipid emulsion therapy, seizure control, advanced cardiac life support

10. Spinal/Epidural Hematoma (Very Rare)



Epidural hematoma compressing spinal cord (MRI)

Incidence: 1:150,000 – 1:220,000

- **Risk factors:** coagulopathy, anticoagulation, traumatic needle placement, multiple attempts
- **Presenting symptoms:** severe back pain, progressive neurologic deficit (motor weakness, sensory loss, bowel/bladder dysfunction)
- **Requires urgent MRI** and decompressive surgery (ideally within 8–12 hours)

11. Neurologic Complications



Incidence: 0.01–0.1%

- Transient neurologic symptoms: 0.1–1% (resolves within weeks)
- **Persistent neurologic deficit:** 0.0001–0.01%
- **Causes:** nerve injury, hematoma, infection, direct trauma, neurotoxicity
- **Red flags:** persistent numbness, weakness, bowel/bladder dysfunction → urgent evaluation

12. Epidural Infection (Rare)



Incidence: 1:10,000 – 1:100,000

- Epidural abscess, meningitis, discitis, osteomyelitis
- Risk factors: prolonged catheterization, immunosuppression, breaches in aseptic technique
- **Presenting symptoms:** back pain, fever, neurologic deficits
- **Management:** urgent MRI, antibiotic therapy, surgical drainage if needed

1. Neuraxial Labor Analgesia: Anatomy

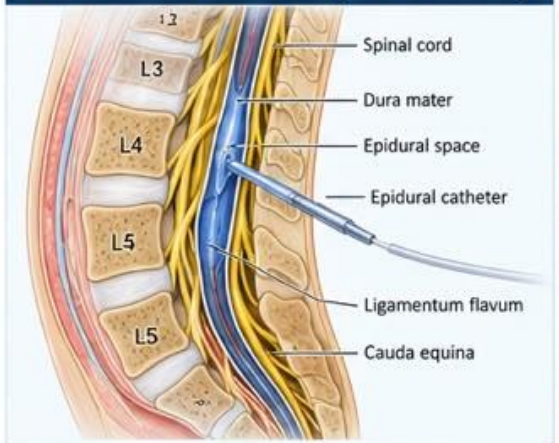

2. Common Complications Overview



Common complications (1–10%)

- Maternal hypotension
- Nausea and vomiting
- Pruritus
- Urinary retention
- Fever
- Prolonged second stage
- Motor block

Rare but serious complications (<0.1%)

- Post-dural puncture headache
- High or total spinal block
- Local anesthetic systemic toxicity (LAST)
- Spinal/epidural hematoma
- Infection (epidural abscess, meningitis)
- Neurologic injury

3. Maternal Hypotension and Fetal Effects



Sympathetic block
↓
Decreased SVR and venous return
↓
Maternal hypotension
↓
Uteroplacental hypoperfusion
↓
Fetal effects: fetal heart rate changes (bradycardia, variable decelerations)

4. Post-dural Puncture Headache (PDPH)



Typical features:

- Postural headacke (worse sitting/standing)
- Occipital or frontal
- Neck stiffness
- Nausea, photophobia
- Onset: 24–72 hours after dural puncture

5. High or Total Spinal Block

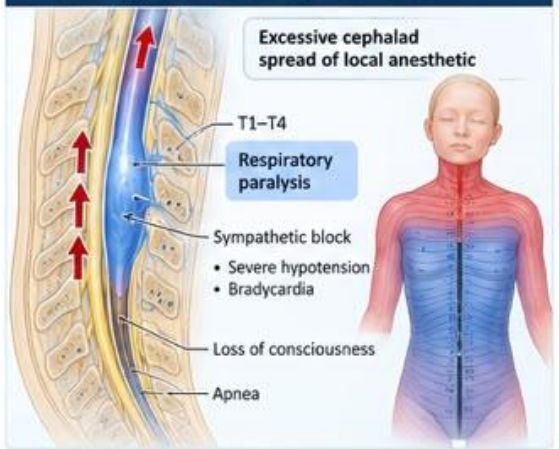

6. Local Anesthetic Systemic Toxicity (LAST)

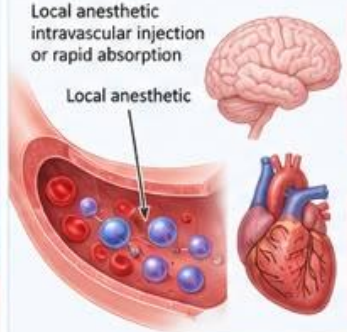

CNS symptoms:

- Circumoral numbness
- Tinnitus
- Metallic taste
- Agitation, seizures
- Loss of consciousness

Cardiovascular symptoms:

- Arrhythmias
- Conduction block
- Severe hypotension
- Cardiac arrest

Treatment:
Immediate 20% lipid emulsion therapy

7. Neuraxial Hematoma (Rare)

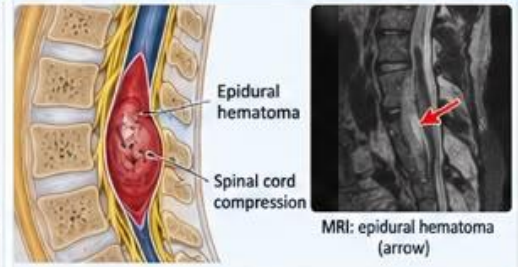

Risk factors:

- Coagulopathy / anticoagulation
- Traumatic or multiple attempts
- Advanced age

Clinical features:

- Severe back pain
- Progressive motor and sensory deficit
- Bladder/bowel dysfunction

→ Urgent neurosurgical decompression

8. Infection: Epidural Abscess / Meningitis (Rare)



Clinical features:

- Back pain
- Fever
- Neurologic deficits (motor/sensory)
- Elevated inflammatory markers (WBC, CRP)

9. Urinary Retention (Common)

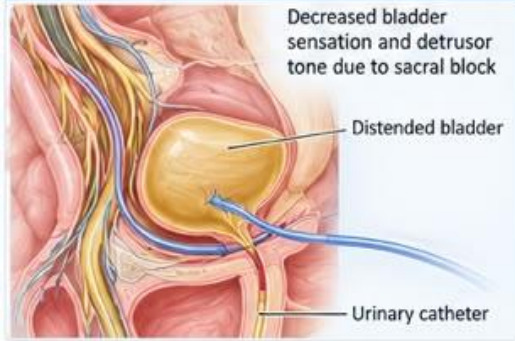

10. Labor and Delivery Effects



Potential effects:

- Prolonged second stage of labor
- Increased rate of instrumental delivery (forceps/vacuum)
- Possible increased risk of cesarean section (varies by study)

11. Neurologic Complications (Rare)

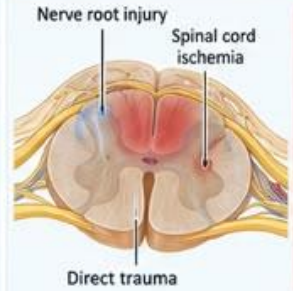

Red flags:

- Persistent motor block > 4 hours
- New sensory deficit
- Severe back pain
- Radicular pain
- Bowel or bladder dysfunction
- Progressive neurologic signs

12. Prevention and Management Principles

- Use appropriate technique and test dose
- Monitor maternal blood pressure and fetal heart rate
- Aspirate before injection to avoid intravascular injection
- Use lowest effective dose of local anesthetic
- Early recognition of complications
- Prompt intervention (vasopressors, lipid therapy, antibiotics, neurosurgical consultation)

Common and Rare Complications of Labor Analgesia

Neuraxial techniques: epidural and combined spinal–epidural (CSE)

1-Focus: common adverse effects, rare emergencies, recognition, and initial management.

2- Audience: anesthesia, obstetrics, midwifery, and postgraduate trainees.

3- Core principle: early recognition of hemodynamic instability or new neurologic deficits can limit harm.

1. Clinical Framework and Monitoring

Safety begins before needle placement and continues after each significant dose

- **Pre-procedure: assess airway, baseline hemodynamics, anticoagulant timing/coagulation risk, infection, and pre-existing neurologic findings.**
- **After initiation or significant boluses: monitor blood pressure frequently; assess sensory level and motor block at appropriate intervals.**
- **Monitor fetal heart rate according to local policy; NICE recommends CTG during establishment of regional analgesia and after boluses of 10 mL or more.**
- **Ensure IV access, resuscitation equipment, vasopressors, and a clear escalation pathway are available.**

Recognition: complication and red flags

Complication	Key clues	Priority response
Common: hypotension / PDPH	BP fall or postural headache	Assess mother/fetus; investigate red flags
Rare: high block / LAST / hematoma	Respiratory or CV instability; progressive deficit	Emergency response; urgent specialist escalation
Content	Content	Content

Take-home messages

1

Common does not mean trivial

Monitor hemodynamics, motor block, bladder function and fetal status.

2

Do not miss rare emergencies

High block and LAST require immediate resuscitation response.

3

Escalate neurologic red flags

Progressive weakness, saddle anesthesia or sphincter symptoms require urgent assessment.

- **Mechanism: reduced sympathetic tone and venous return; uterine activity and maternal position may also contribute.**
- **Features: fall in blood pressure from baseline, nausea, pallor, sweating, dizziness, or fetal heart-rate abnormalities**
- **Pruritus, nausea, shivering, and intrapartum fever; fever requires assessment for infectious and non-infectious causes.**

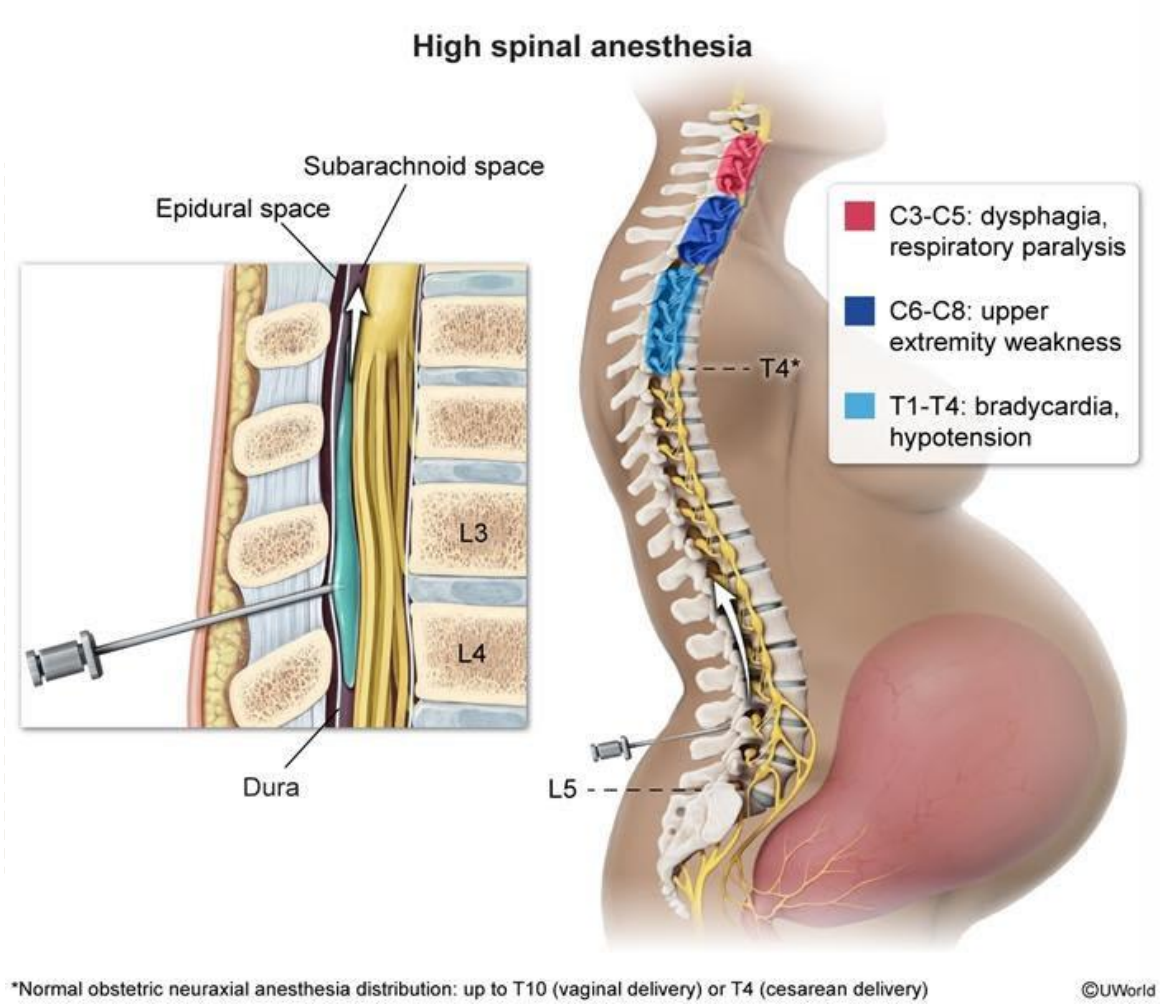

2. Common or Relatively Common Adverse Effects

Most are manageable with surveillance and timely interventio

Hypotension: sympathetic blockade may cause nausea, dizziness, or fetal heart-rate changes.

Motor block, leg heaviness, and reduced mobility; severity depends on drug concentration and dose.

Urinary retention and reduced bladder sensation; assess voiding and bladder distension

Pruritus, nausea, shivering, and intrapartum fever; fever requires assessment for infectious and non-infectious causes.

Inadequate, unilateral, or patchy analgesia; may require catheter adjustment, replacement, or an alternative technique.

3. Maternal Hypotension and Fetal Effects

A clinically important and often treatable complication

- **Mechanism: reduced sympathetic tone and venous return; uterine activity and maternal position may also contribute.**
- **Features: fall in blood pressure from baseline, nausea, pallor, sweating, dizziness, or fetal heart-rate abnormalities.**
- **Initial response: assess mother and fetus, optimize position, consider IV fluid therapy when indicated, and administer a vasopressor according to local protocol.**
- **Persistent fetal heart-rate changes require prompt assessment for both anesthetic and obstetric causes.**

4. Post-Dural Puncture Headache (PDPH)

Consider accidental dural puncture, but do not assume every postpartum headache is PDPH

- **Often develops within days after dural puncture; a postural pattern is typical but not universal.**
- **Differential diagnosis includes pre-eclampsia, cerebral venous sinus thrombosis, intracranial hemorrhage, meningitis, and primary headache disorders.**
- **Assess severity, postural features, blood pressure, and neurologic signs; atypical or red-flag symptoms warrant further investigation.**
- **Severe or persistent symptoms merit anesthesia review; an epidural blood patch may be indicated after clinical assessment.**

5. Rare, Life-Threatening Emergencies

Recognize early and activate the emergency response

- **High or total neuraxial block:** ascending weakness, severe hypotension, bradycardia, dyspnea, or reduced consciousness.
- **Local anesthetic systemic toxicity (LAST):** neurologic symptoms, seizures, arrhythmias, or cardiovascular collapse.
- **Spinal/epidural hematoma:** severe back pain, progressive weakness, or sphincter dysfunction; time-critical diagnostic and treatment emergency.
- **Epidural abscess or meningitis:** fever, localized spinal pain, and/or neurologic signs; presentation may be delayed.
- Persistent neurologic injury, cauda equina syndrome, and very rare cardiorespiratory complications.

6. Postpartum Neurologic Red Flags

Do not attribute unexpected or progressive deficits to residual local anesthetic without assessment

- **Severe, asymmetric, progressive, or unexpectedly persistent motor weakness.**
- **Saddle anesthesia, new urinary retention, or bowel/bladder incontinence.**
- **Severe back pain accompanied by neurologic deficit, fever, or focal tenderness.**
- **Urgent anesthetic assessment and neurology/neurosurgical input are required; suspected compressive hematoma warrants emergency imaging and immediate specialist escalation.**

7. Prevention and Risk Management

Safety depends on patient selection, technique, medication, monitoring, and escalation

- **Check anticoagulant exposure and timing against current neuraxial guidelines and institutional policy.**
- **Use appropriate dilute local anesthetic–opioid solutions per protocol; administer incrementally and reassess after dosing.**
- **After each dose, reassess blood pressure, sensory level, respiration, consciousness, and fetal status as indicated.**
- **Maintain written algorithms for high block, LAST, hypotension, and progressive neurologic symptoms.**
- **Document dose/time, symptoms, examination findings, interventions, and escalation.**

8. Key Takeaways and Selected References

Educational summary — apply local protocols and individual clinical judgment

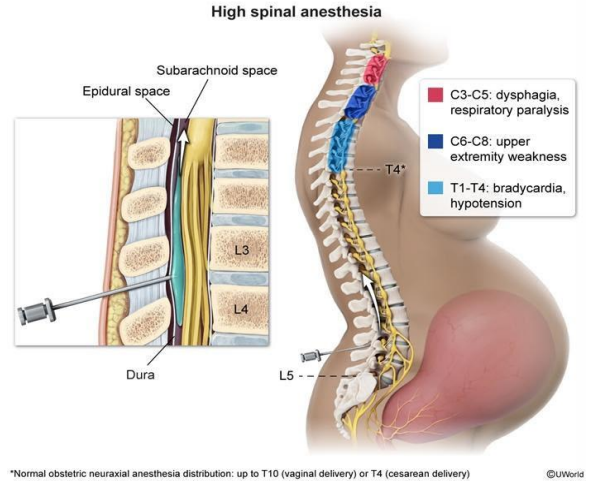

- **Common: hypotension, motor block, urinary retention, pruritus/nausea, fever, and inadequate analgesia.**
- **Rare but critical: high neuraxial block, LAST, neuraxial hematoma, deep infection, and serious neurologic injury.**
- **Any new or progressive neurologic deficit after childbirth requires urgent assessment; do not assume it is simply residual block.**
- **Selected references: NICE Guideline NG235, Intrapartum care (2023); American Society of Anesthesiologists, Statement on Post-Dural Puncture Headache Management (2021).**
- **This presentation is for education and does not replace current guidelines, specialist assessment, or local emergency protocols.**

1. Neuraxial Labor Analgesia: Anatomy

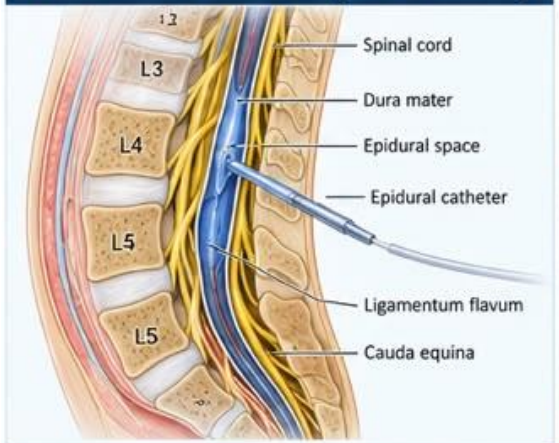

2. Common Complications Overview



Common complications (1–10%)

- Maternal hypotension
- Nausea and vomiting
- Pruritus
- Urinary retention
- Fever
- Prolonged second stage
- Motor block

Rare but serious complications (<0.1%)

- Post-dural puncture headache
- High or total spinal block
- Local anesthetic systemic toxicity (LAST)
- Spinal/epidural hematoma
- Infection (epidural abscess, meningitis)
- Neurologic injury

3. Maternal Hypotension and Fetal Effects



Sympathetic block
↓
Decreased SVR and venous return
↓
Maternal hypotension
↓
Uteroplacental hypoperfusion
↓
Fetal effects: fetal heart rate changes (bradycardia, variable decelerations)

4. Post-dural Puncture Headache (PDPH)



Typical features:

- Postural headacke (worse sitting/standing)
- Occipital or frontal
- Neck stiffness
- Nausea, photophobia
- Onset: 24–72 hours after dural puncture

5. High or Total Spinal Block

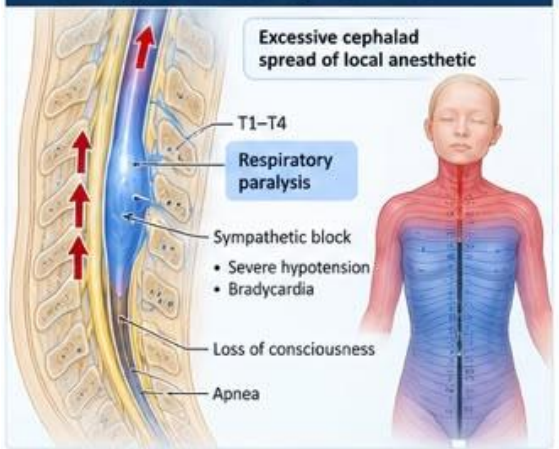

6. Local Anesthetic Systemic Toxicity (LAST)

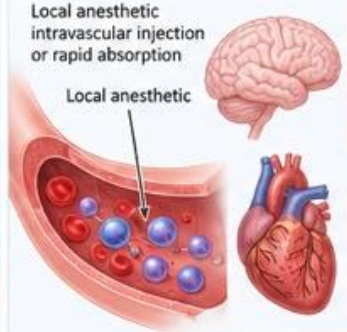

CNS symptoms:

- Circumoral numbness
- Tinnitus
- Metallic taste
- Agitation, seizures
- Loss of consciousness

Cardiovascular symptoms:

- Arrhythmias
- Conduction block
- Severe hypotension
- Cardiac arrest

Treatment:
Immediate 20% lipid emulsion therapy

7. Neuraxial Hematoma (Rare)

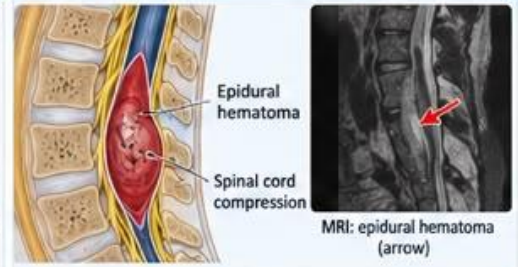

Risk factors:

- Coagulopathy / anticoagulation
- Traumatic or multiple attempts
- Advanced age

Clinical features:

- Severe back pain
- Progressive motor and sensory deficit
- Bladder/bowel dysfunction

→ Urgent neurosurgical decompression

8. Infection: Epidural Abscess / Meningitis (Rare)



Clinical features:

- Back pain
- Fever
- Neurologic deficits (motor/sensory)
- Elevated inflammatory markers (WBC, CRP)

9. Urinary Retention (Common)

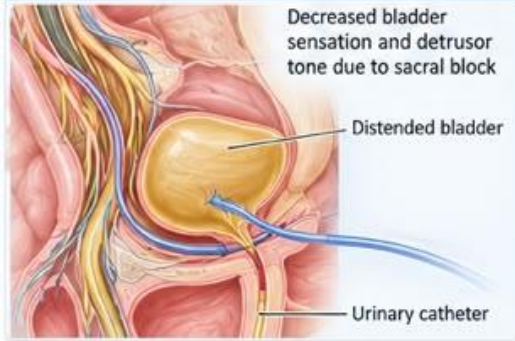

10. Labor and Delivery Effects



Potential effects:

- Prolonged second stage of labor
- Increased rate of instrumental delivery (forceps/vacuum)
- Possible increased risk of cesarean section (varies by study)

11. Neurologic Complications (Rare)

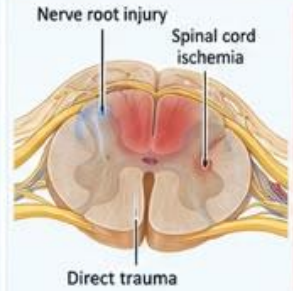

Red flags:

- Persistent motor block > 4 hours
- New sensory deficit
- Severe back pain
- Radicular pain
- Bowel or bladder dysfunction
- Progressive neurologic signs

12. Prevention and Management Principles

- Use appropriate technique and test dose
- Monitor maternal blood pressure and fetal heart rate
- Aspirate before injection to avoid intravascular injection
- Use lowest effective dose of local anesthetic
- Early recognition of complications
- Prompt intervention (vasopressors, lipid therapy, antibiotics, neurosurgical consultation)

References:

1. Neal JM, Neal EJ, Weinberg GL. ASRA LAST checklist: 2020 version. Reg Anesth Pain Med. 2021;46:81–82. doi:10.1136/rapm-2020-101986.

2. American Society of Regional Anesthesia and Pain Medicine. Checklist for Treatment of Local Anesthetic Systemic Toxicity (LAST). 2020. https://asra.com/…/checklist-for-treatment-of-local-anesthetic-systemic-toxicity

3. Lawrence H, Morton A. Postpartum complications following neuraxial anaesthesia for obstetric physicians. Obstet Med. 2023. https://pmc.ncbi.nlm.nih.gov/articles/PMC10504890/

4. American Society of Anesthesiologists. Statement on Post-Dural Puncture Headache Management. 2021. https://www.asahq.org/standards-and-practice-parameters/statement-on-post-dural-puncture-headache-management

5. NICE. Intrapartum care. Guideline NG235. 2023. https://www.nice.org.uk/guidance/ng235/chapter/Recommendations

Thank You for Your Attention

Questions and Discussion

drkamali.ar@gmail.com