Acute Coronary Syndrome in Critically Ill Patients

Diagnostic challenges, therapeutic dilemmas, and an ICU-first approach

Seyed Hossein Ardehali MD

s

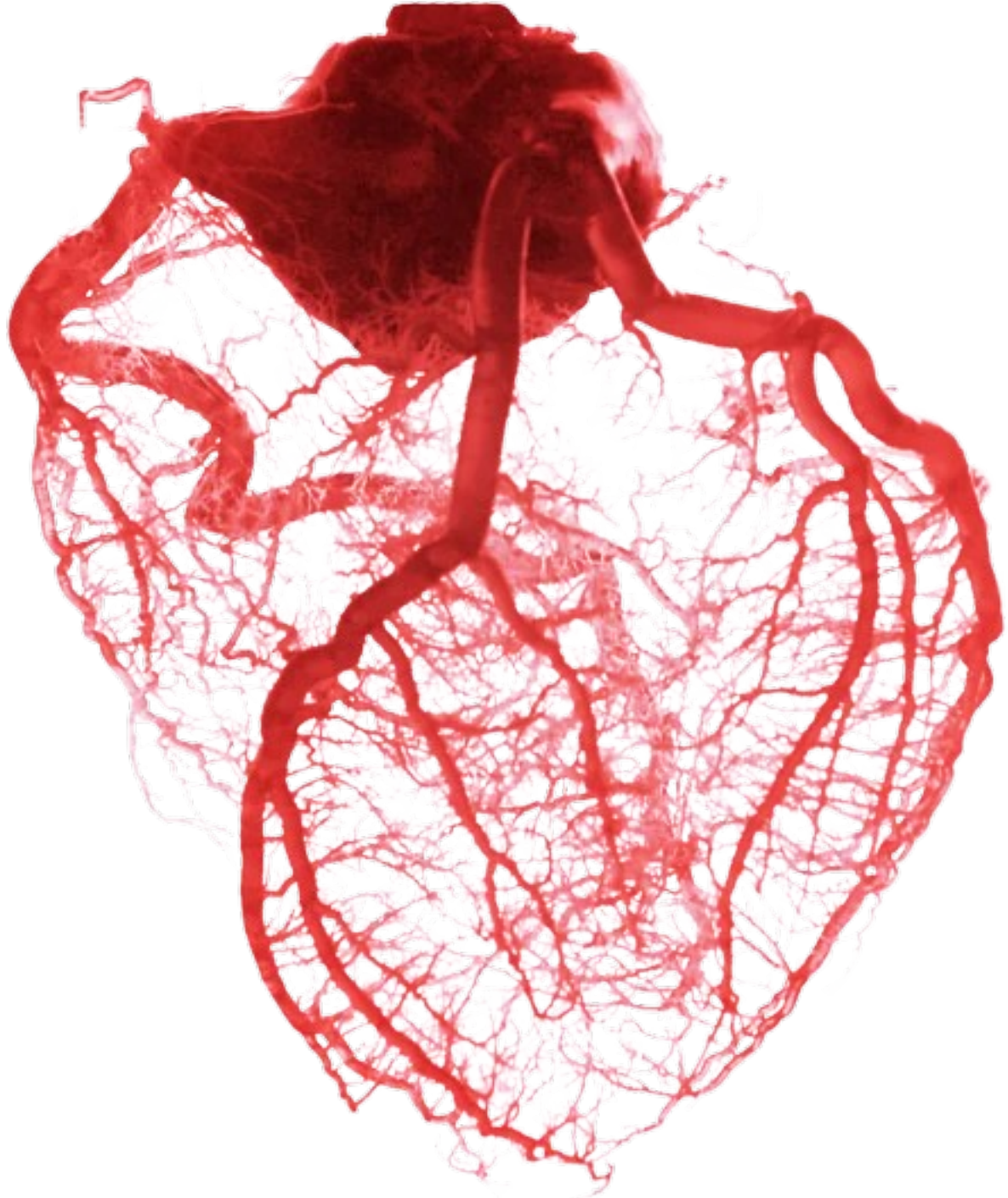

biomedicines

MDPI

Editorial

Cardiovascular Diseases in the Critically Ill: Bridging Evidence Gaps Between Cardiology and Intensive Care Medicine

Vasileios Vazgiourakis [1,2]

[1] Faculty of Medicine, School of Health Sciences, University of Thessaly, 3 Panepistimiou Street, Biopolis, 41500 Larissa, Greece; vasvazg@yahoo.com
[2] Department of Critical Care, University Hospital of Larissa, Mezourlo, 41110 Larissa, Greece

Education in Heart

Assessment and management of cardiovascular disease in the intensive care unit

David Jonathan Cook,[1,2] Stephen Webb ,[3] Alastair Proudfoot[4,5]

Why ACS in the ICU is different

Symptoms may be absent, masked by sedation, ventilation, delirium, or analgesia

ECG changes may be transient or confounded by pacing, electrolyte disorders, LVH, or baseline abnormalities

Troponin elevation is common in sepsis, shock, renal dysfunction, PE, and acute heart failure

Bleeding risk, procedures, thrombocytopenia, and competing organ failure complicate antithrombotic treatment

Do not let a nonspecific troponin rise trigger automatic ACS treatment—or let an atypical presentation delay reperfusion.

The goal today is a practical framework for **recognition**, **triage**, and **treatment**—not a replacement for local STEMI pathways or cardiology consultation.

Start with the right definitions

Acute myocardial injury: cardiac troponin above the 99th percentile with a rise and/or fall

Myocardial infarction: acute myocardial injury PLUS evidence of acute myocardial ischemia

Type 1 MI: acute atherothrombosis, usually plaque rupture/erosion

Type 2 MI: ischemia from oxygen supply–demand imbalance, without acute coronary atherothrombosis

Acute myocardial injury without ischemia ≠ type 2 MI

Troponin is a marker of myocardial injury, not a mechanism-specific test for coronary thrombosis.

MINS

Myocardial Injury After Noncardiac Surgery

Type 1 MI, type 2 MI, or myocardial injury?

Type 1 MI: focal ischemic ECG changes, new regional wall-motion abnormality, culprit lesion/thrombus, compatible clinical trajectory

Type 2 MI: a clear stressor (e.g., severe hypoxemia, anemia, tachyarrhythmia, hypotension) PLUS evidence of ischemia

Myocardial injury: troponin dynamics without convincing evidence of ischemia

These categories can coexist with underlying coronary artery disease

Treat the mechanism—not the troponin number.

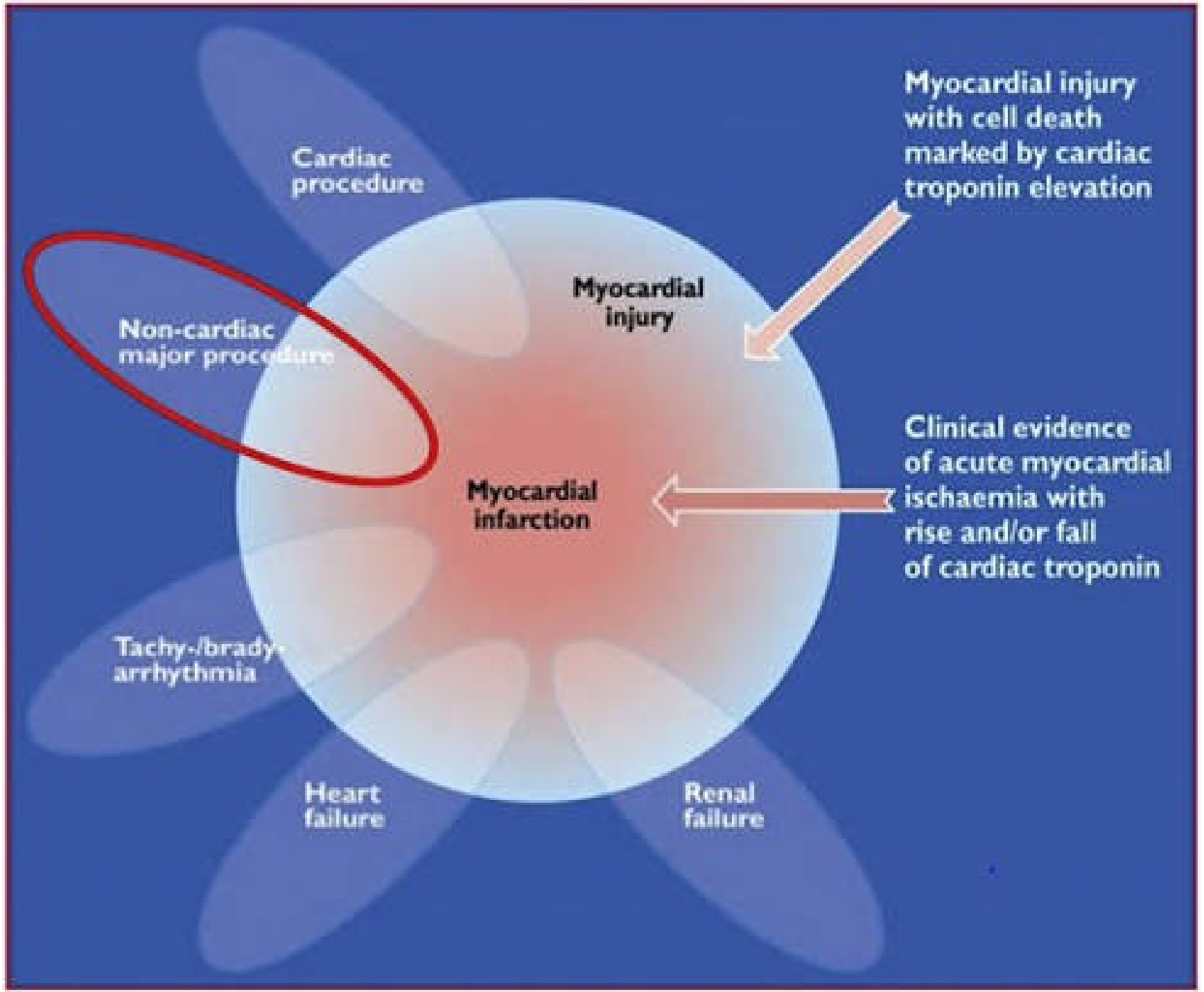
Cardiac procedure
Non-cardiac major procedure
Tachy-/brady-arrhythmia
Heart failure
Renal failure
Myocardial injury
Myocardial infarction
Myocardial injury with cell death marked by cardiac troponin elevation
Clinical evidence of acute myocardial ischaemia with rise and/or fall of cardiac troponin

A practical diagnostic bundle

12-lead ECG within 10 minutes when ACS is suspected; repeat with clinical change or persistent suspicion

Serial high-sensitivity troponin using the assay-specific 0/1-hour or 0/2-hour pathway where validated

Focused bedside echocardiography: regional wall motion, LV/RV function, acute MR, pericardial effusion, alternative shock causes

Review hemodynamics, oxygenation, hemoglobin, rhythm, renal function, medications, and prior ECG/troponin

A single ECG, a single troponin, or a single bedside echo rarely settles the diagnosis.

ECG clues in a non-communicative patient

New ST elevation or dynamic ST depression/T-wave changes: treat as high concern for acute ischemia

Consider posterior MI when V1–V3 show ST depression; obtain posterior leads when appropriate

New LBBB alone is not automatically diagnostic; interpret with symptoms, ECG criteria, and instability

Compare with prior tracings; correct major electrolyte and rate-related confounders—but do not delay reperfusion for clear STEMI

Dynamic ECG change plus instability deserves urgent cardiology/cath-lab discussion.

Decision algorithm: first 10 minutes

1. Suspected ACS or unexplained shock/arrhythmia → ABCs, monitor/defibrillator readiness, 12-lead ECG
2. STEMI or compelling occlusion pattern? → activate reperfusion pathway immediately
3. Hemodynamic instability, ongoing ischemia, malignant arrhythmia, acute HF? → urgent cardiology + bedside echo; consider emergency angiography
4. No immediate high-risk feature → serial ECG/hs-cTn, focused echo, search for competing causes
5. Reassess as the trajectory evolves; document the working mechanism and uncertainty

Clinical instability can outweigh a nondiagnostic first troponin or ECG.

When is invasive coronary angiography urgent?

Immediate/emergency strategy: STEMI; very-high-risk NSTE-ACS with shock/hemodynamic instability, refractory ischemia, life-threatening arrhythmia, or acute HF suspected from ongoing ischemia

Early inpatient invasive evaluation: confirmed NSTEMI or high-risk NSTE-ACS, based on risk and clinical context

Individualize when diagnosis is uncertain and procedural/bleeding risk is extreme—but actively reassess

If type 2 MI or non-ischemic injury is more likely, prioritize the precipitating cause and consider coronary evaluation after stabilization when appropriate

Do not misclassify every ICU troponin rise as an indication for urgent catheterization.

Antithrombotic therapy: benefit versus bleeding

For confirmed/suspected type 1 ACS, use guideline-based aspirin, P2Y12 inhibition, and parenteral anticoagulation when indicated

Choose agent/timing with cardiology; account for renal function, weight, age, prior anticoagulants, thrombocytopenia, and procedures

Routine P2Y12 pretreatment before coronary anatomy is known is not recommended for all NSTE-ACS patients

Use radial access when feasible; assess bleeding risk and need for gastroprotection

Do not routinely give ACS antithrombotics for isolated myocardial injury without evidence of type 1 ACS

In ICU, the harm of empiric antithrombotic treatment may be substantial when the diagnosis is wrong.

Avoid giving a universal drug/dose protocol on this slide because treatment depends on diagnosis, renal function, bleeding risk, PCI plan, and local pathways.

The 2025 ACC/AHA guideline supports DAPT as default after ACS in patients without high bleeding risk, with individualized strategies for high bleeding risk or concurrent oral anticoagulation.

Confirmed type 2 MI is not automatically treated with the type 1 ACS antithrombotic bundle.

Mechanism of Action for TherOx® SuperSaturated Oxygen (SSO_2) Therapy

DAMAGE TO THE MYOCARDIUM

Primary stenting for anterior STEMI restores blood flow to improve outcomes, but damage in the microvasculature can persist due to reactionary changes that occur at the cellular level, obstructing microvascular flow.[1]

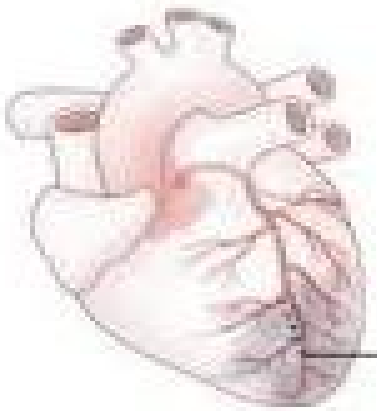

Left anterior descending artery

Damaged myocardium

MICROVASCULAR OBSTRUCTION

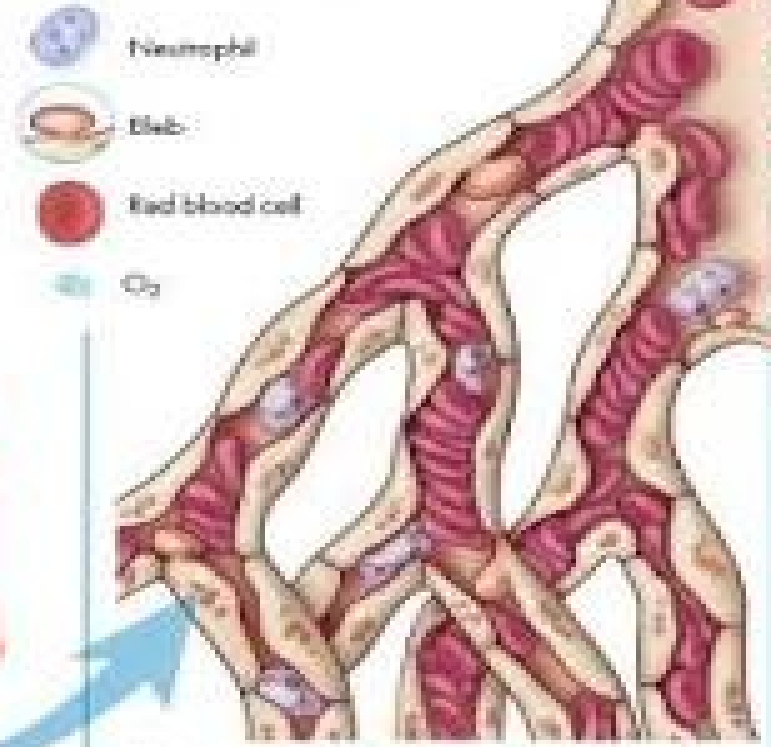

Following flow restoration with PCI, capillaries can remain obstructed from endothelial edema, activation of neutrophils, and other physiologic factors. This is known as microvascular obstruction (MVO).[2]

SSO_2 THERAPY

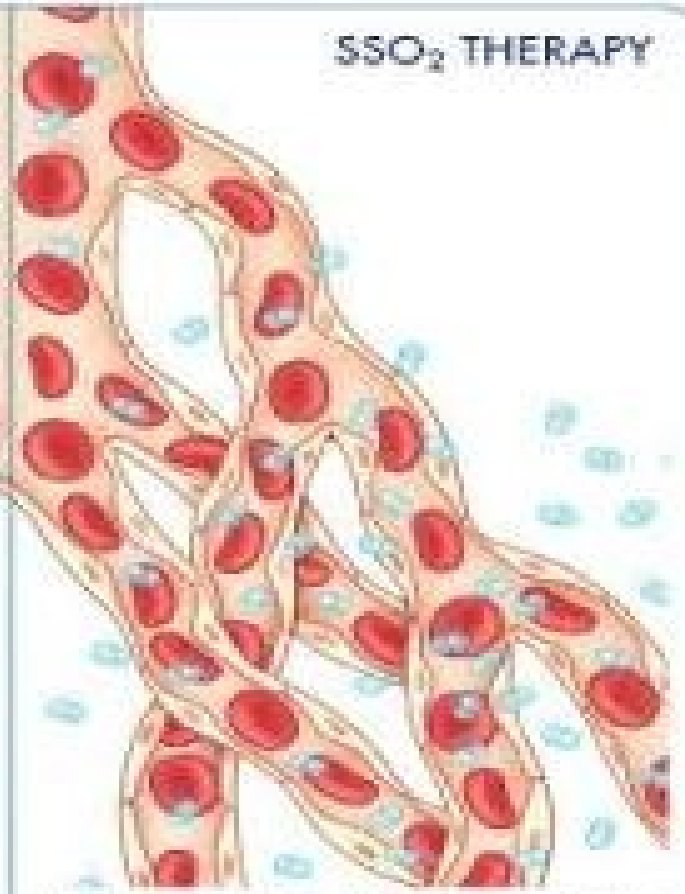

The hyperoxemic levels of dissolved oxygen (7-10x normal) provided by SSO_2 allow for a high rate of diffusion via the plasma, even before flow is restored downstream. This reduces endothelial swelling and allows for restoration of microvascular flow.[3]

IMPLICATIONS

SSO_2's mechanism of action can improve microvascular blood flow, viability, and function.[4] This is likely a key contributing factor driving the significant reductions in infarct size and improved left ventricular function as observed in multiple clinical studies for SSO_2 Therapy.[5-7]

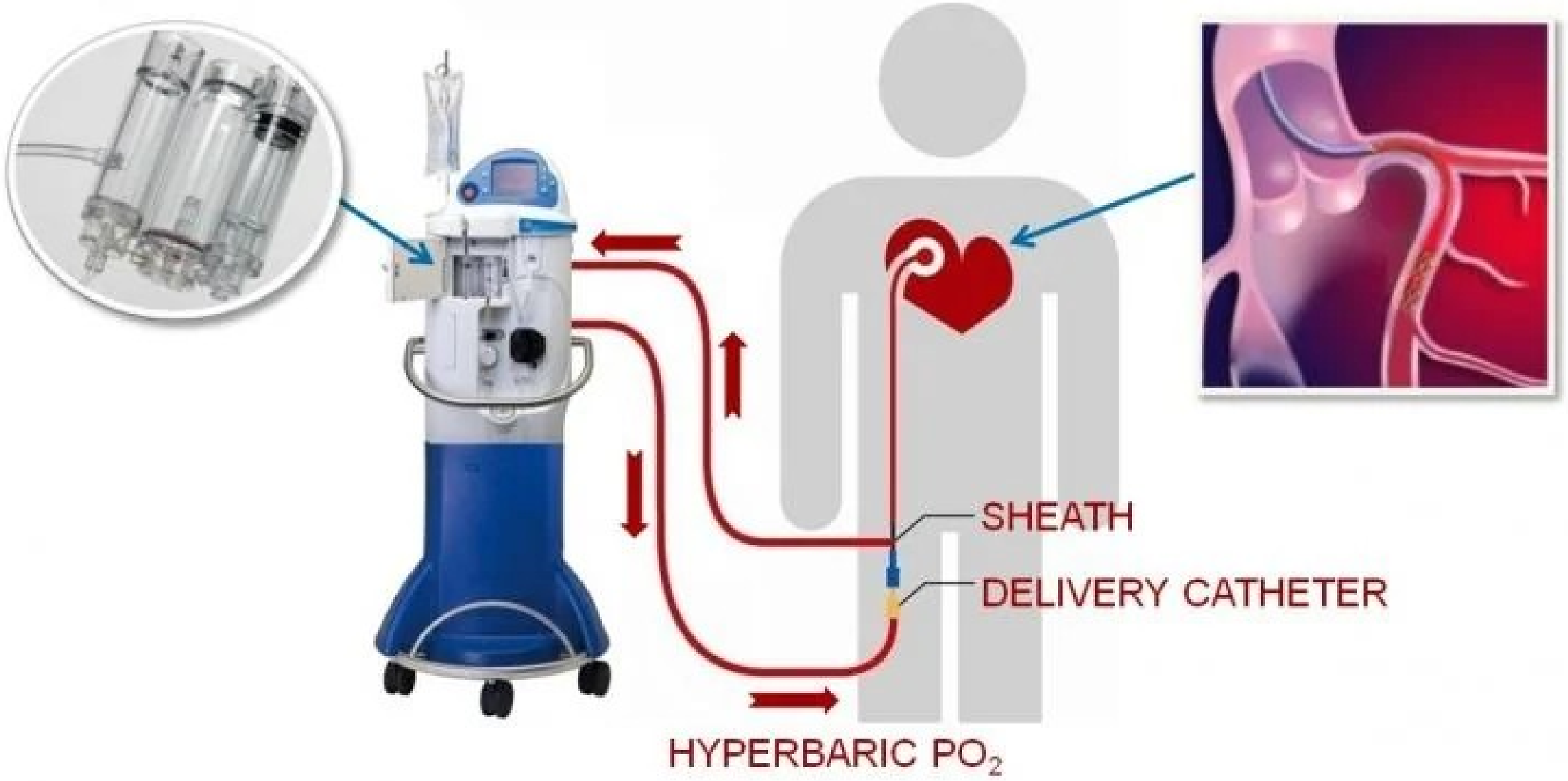
SHEATH
DELIVERY CATHETER
HYPERBARIC PO_2

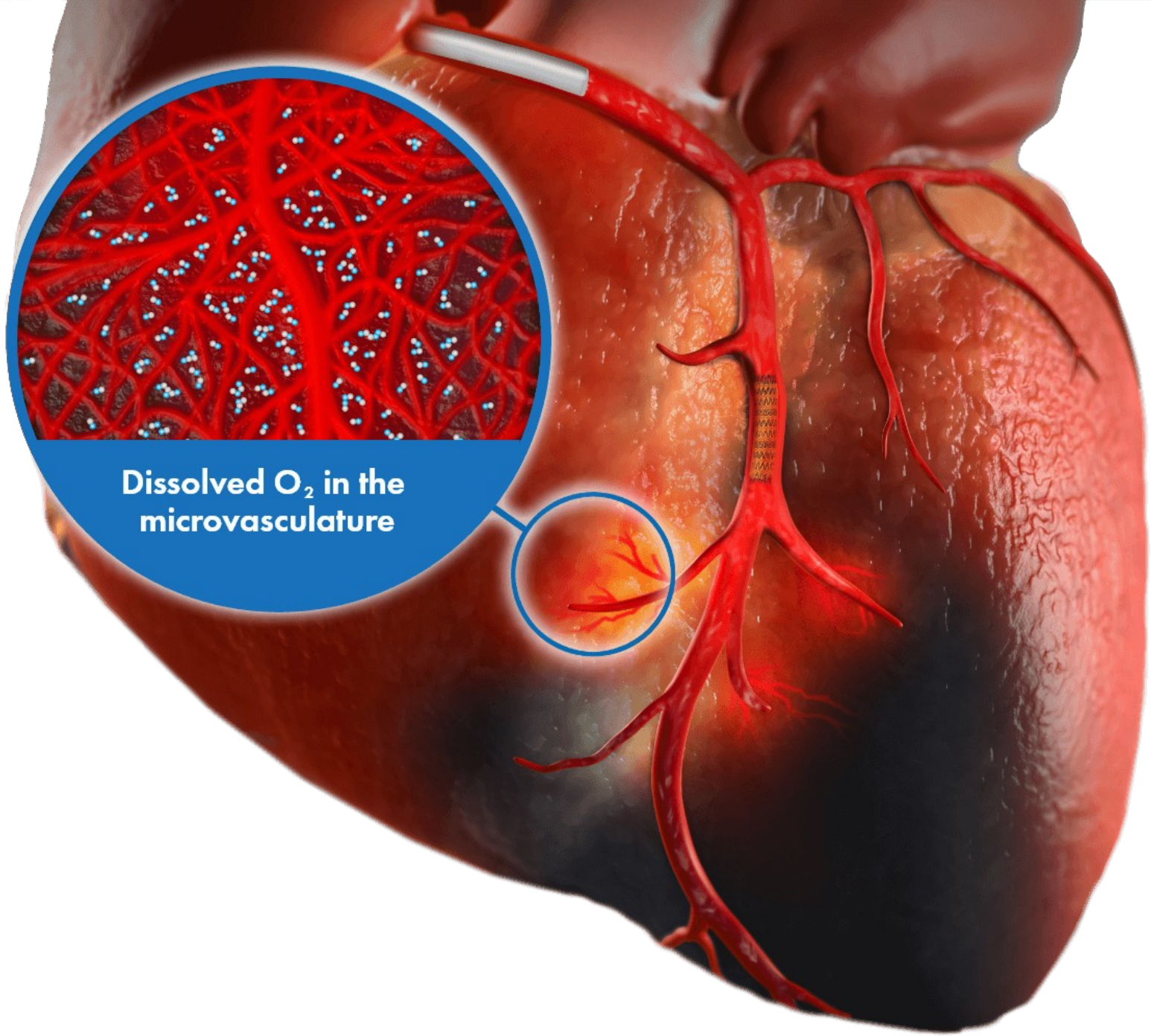
Dissolved O_2 in the microvasculature

Type 2 MI / myocardial injury: treat the driver

Correct the precipitant: hypoxemia, hypotension, severe anemia, fever/sepsis, tachyarrhythmia, or marked hypertension

Optimize oxygen delivery and demand; avoid reflexive escalation of oxygen in normoxemia

Reassess ECG, troponin trend, ventricular function, and symptoms/signs after stabilization

Consider obstructive CAD and secondary prevention based on history, imaging, and overall risk

Avoid assuming that antiplatelet/anticoagulant treatment improves outcomes in every type 2 MI

A cause-directed plan is the treatment core; evidence for routine type 1 MI therapies in type 2 MI is limited.

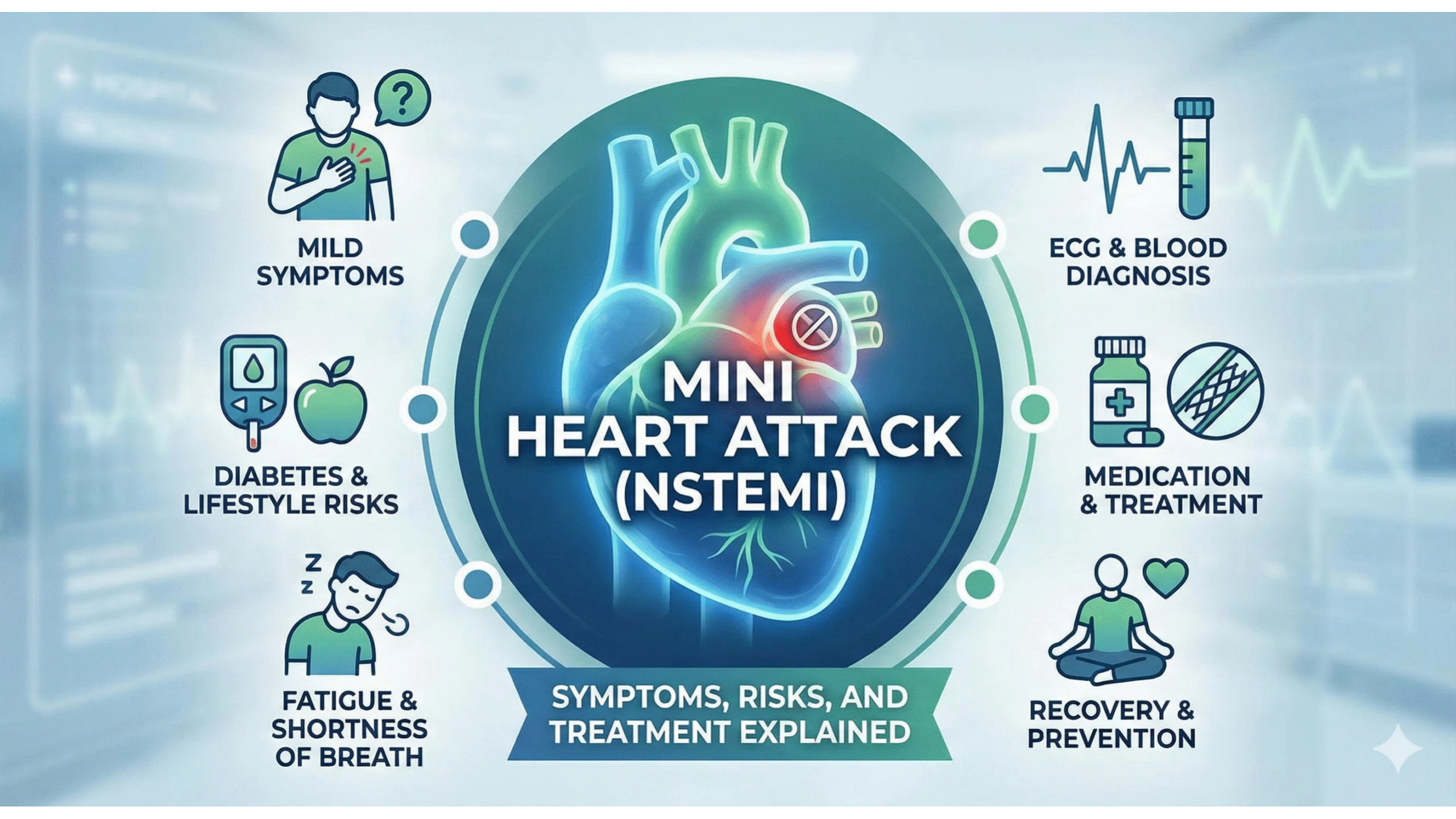
MILD SYMPTOMS
DIABETES & LIFESTYLE RISKS
FATIGUE & SHORTNESS OF BREATH
MINI HEART ATTACK (NSTEMI)
SYMPTOMS, RISKS, AND TREATMENT EXPLAINED
ECG & BLOOD DIAGNOSIS
MEDICATION & TREATMENT
RECOVERY & PREVENTION

ACS with cardiogenic shock

Recognize hypoperfusion early: altered mentation, cool/mottled skin, oliguria, lactate rise, worsening renal/hepatic function

Urgent culprit-vessel revascularization by PCI or CABG is indicated when ACS causes shock

Routine immediate PCI of non-culprit vessels during shock is not recommended; consider staged revascularization after stabilization

Use echo/hemodynamic assessment to phenotype LV, RV, or mixed shock; reassess frequently

Escalate to a shock team / advanced center when refractory shock or mechanical complications are suspected

Revascularization is time-critical; the initial PCI strategy is generally culprit-vessel focused.

Vasoactive support and mechanical circulatory support

Use vasopressors/inotropes to restore perfusion while arranging definitive treatment; norepinephrine is commonly preferred for severe hypotension

Avoid prolonged escalation without reassessing phenotype, volume status, rhythm, lactate, and end-organ perfusion

Routine IABP or VA-ECMO for all AMI-shock patients has not shown a survival benefit

A microaxial flow pump may be reasonable in selected patients with STEMI and severe/refractory cardiogenic shock; weigh bleeding, limb ischemia, and renal complications

Mechanical complications (e.g., acute severe MR, VSD, free-wall rupture) require urgent specialist/surgical evaluation

MCS is a selective, phenotype- and system-dependent strategy—not a substitute for revascularization.

ICU-specific pitfalls to avoid

Anchoring on troponin magnitude instead of ischemic evidence and trajectory

Calling all sepsis-associated troponin rises “type 2 MI” without evidence of ischemia

Missing silent/posterior MI because the first ECG is nondiagnostic

Starting DAPT + anticoagulation before considering active bleeding, recent surgery, or an alternative diagnosis

Using MCS reflexively without a shock-team plan, defined goals, and complication surveillance

Use structured reassessment; document both the working diagnosis and what would change it.

Take-home algorithm

1. Suspect ACS in unexplained shock, new arrhythmia, acute pulmonary edema, or dynamic ECG changes—even without chest pain

2. ECG promptly + serial ECGs; hs-cTn using a validated local pathway; focused echo

3. STEMI / very-high-risk ischemia / shock → urgent cardiology and invasive pathway

4. If type 2 MI or injury is more likely → correct the trigger, reassess, and evaluate CAD selectively

5. Match antithrombotic intensity and MCS to mechanism, bleeding risk, shock phenotype, and expertise

The best ICU strategy is rapid recognition, mechanism-based diagnosis, and timely escalation—not troponin-driven treatment.

Acute Heart Failure is Not One Disease: A Guide to Phenotype-Driven Therapy

By Dr. Petrina

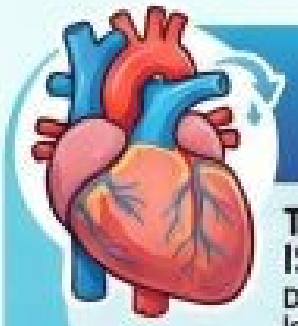

CARDIOGENIC PHENOTYPE (PUMP FAILURE)

THE CORE PROBLEM IS PUMP FAILURE

Decreased cardiac contractility leading to poor blood pumping.



HEMODYNAMICS

LOW OUTPUT, HIGH PRESSURE

Low cardiac output, high filling pressures. Often Hypotension (SBP < 90 mmHg) with hypoperfusion.



CLINICAL CLUE

LOOK FOR SIGNS OF POOR PERFUSION

Cold extremities, altered mental status, reduced urine output (oliguria).



TREATMENT FOCUS

RESTORE PERFUSION FIRST

Primary goal is to restore blood flow. Use of diuretics (Lasix) is conditional and must be cautious.



VASOGENIC PHENOTYPE (AFTERLOAD MISMATCH)

SCAPE

THE CORE PROBLEM IS A PRESSURE PROBLEM (SCAPE)

Sympathetic Crashing Acute Pulmonary Edema

Excessive afterload from severe vasoconstriction, shifting fluid into lungs.



KEY FINDING

ONSET IS SUDDEN AND DRAMATIC

Rapid symptoms in minutes to hours, dyspnea onset < 1 week. Critically ill patient.



CLINICAL CLUE

LOOK FOR SEVERE HYPERTENSION

Severely hypertensive (SBP > 140 mmHg), flash pulmonary edema. Systemic congestion often absent.



TREATMENT FOCUS

VASODILATION IS THE PRIORITY

Primary therapy is vasodilation (Nitroglycerin) and NIV. Diuretics (Lasix) are NOT first-line.

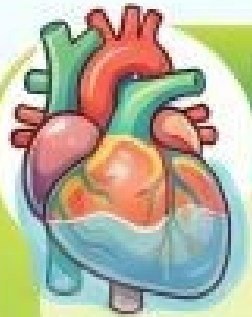

CARDIAC/CONGESTIVE PHENOTYPE (PRELOAD EXCESS)

FOSPE

THE CORE PROBLEM IS A VOLUME PROBLEM (FOSPE)

Fluid Overload Subacute Pulmonary Edema

True fluid overload state leading to pulmonary & systemic congestion.



KEY FINDING

ONSET IS GRADUAL OVER DAYS TO WEEKS

Slow, progressive dyspnea. Typically not as critically ill as SCAPE patients upon presentation.



CLINICAL CLUE

LOOK FOR SIGNS OF FLUID OVERLOAD

Often normotensive, prominent peripheral edema, raised JVP, ascites.



TREATMENT FOCUS

VOLUME REMOVAL IS KEY

Primary therapy is volume removal through IV diuretics (Furosemide/Lasix) or dialysis.

NotebookLM