Right ventricular failure in the ICU
Recognition & Management

By Atabak Najafi MD FCCM
professor of Anesthesiology & Critical Care
Tehran university of medical sciences

Acute right ventricular failure

- Acute right ventricular failure (ARVF) can be defined as a rapidly progressive clinical syndrome characterized by systemic congestion and reduced cardiac output (CO) resulting from a failing right ventricular (RV), producing decompensated heart failure or cardiogenic shock (CS)

RV dysfunction can lead to ARVF

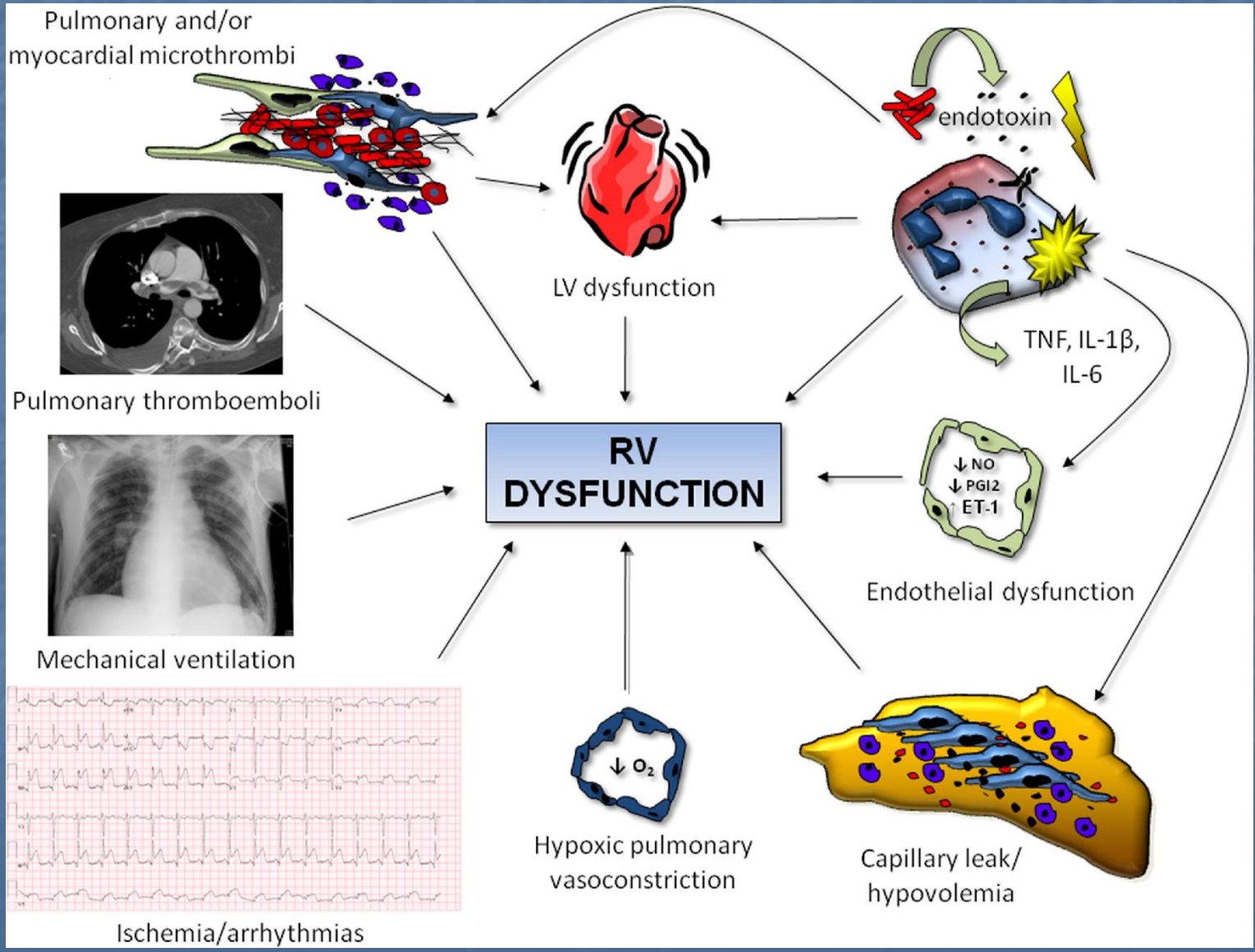

The NEW ENGLAND JOURNAL of MEDICINE

REVIEW ARTICLE

Darren B. Taichman, M.D., Ph.D., *Editor*

Right Ventricular Failure

Brian A. Houston, M.D., Evan L. Brittain, M.D., and Ryan J. Tedford, M.D.

N Engl J Med 2023;388:1111-25.
DOI: 10.1056/NEJMra2207410
Copyright © 2023 Massachusetts Medical Society.

ADVANCES IN HEART FAILURE, MECHANICAL CIRCULATORY SUPPORT AND TRANSPLANT

Gaps and Knowledge in the Contemporary Management of Acute Right Ventricular Failure

Paolo Manca, MD; Vincenzo Nuzzi, MD; Massimiliano Mulè, MD, PhD; Sergio Sciacca, MD; Matteo Castrichini, MD; Uwe Schulz, MD; Naveen L. Pereira, MD; Holger Thiele, MD; Jacob C. Jentzer, MD, MS; Manlio Cipriani, MD

© 2025 The Authors. *Circulation: Heart Failure* is published on behalf of the American Heart Association, Inc., by Wolters Kluwer Health, Inc. This is an open access article under the terms of the Creative Commons Attribution Non-Commercial-NoDerivs License, which permits use, distribution, and reproduction in any medium, provided that the original work is properly cited, the use is noncommercial, and no modifications or adaptations are made.

Circulation: Heart Failure is available at www.ahajournals.org/journal/circheartfailure

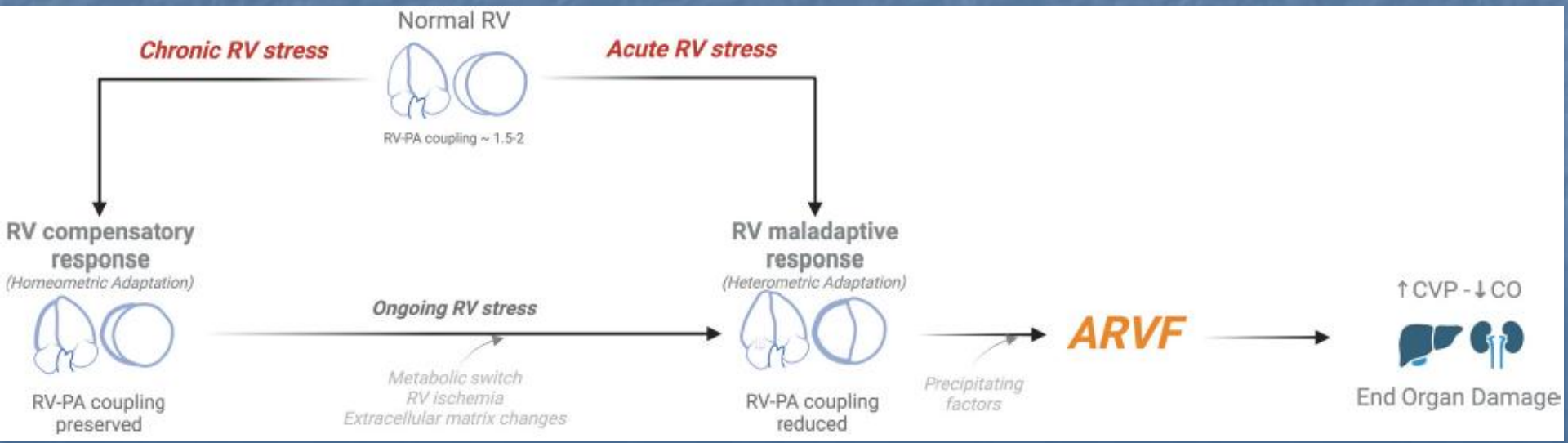

Main causes of ARVF

- ARVF develops through 3 primary mechanisms, often interrelated
- • Reduced contractility
- • Increased preload
- • Increased afterload

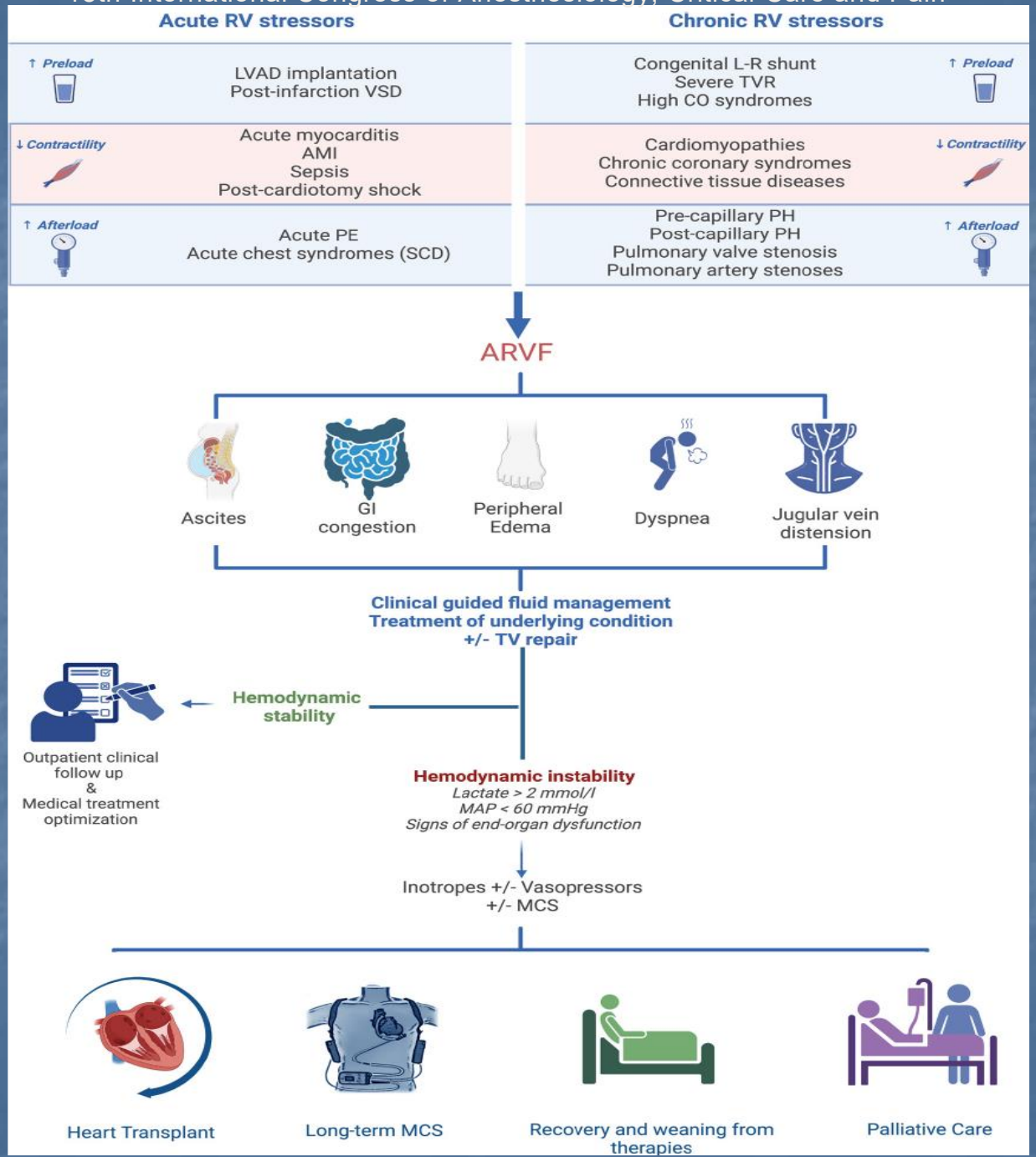
Acute RV stressors
Chronic RV stressors
↑ Preload
LVAD implantation
Post-infarction VSD
Congenital L-R shunt
Severe TVR
High CO syndromes
↑ Preload
↓ Contractility
Acute myocarditis
AMI
Sepsis
Post-cardiotomy shock
Cardiomyopathies
Chronic coronary syndromes
Connective tissue diseases
↓ Contractility
↑ Afterload
Acute PE
Acute chest syndromes (SCD)
Pre-capillary PH
Post-capillary PH
Pulmonary valve stenosis
Pulmonary artery stenoses
↑ Afterload
ARVF
Ascites
GI congestion
Peripheral Edema
Dyspnea
Jugular vein distension
Clinical guided fluid management
Treatment of underlying condition
+/- TV repair
Hemodynamic stability
Outpatient clinical follow up & Medical treatment optimization
Hemodynamic instability
Lactate > 2 mmol/l
MAP < 60 mmHg
Signs of end-organ dysfunction
Inotropes +/- Vasopressors
+/- MCS
Heart Transplant
Long-term MCS
Recovery and weaning from therapies
Palliative Care

Decrease in Ventricular contraction and relaxation produce ARVF

- Reduction in ATP production in ischemic myocardium leads in decreased inotropy and lusitropy and cardiac output and eventually heart failure

Mechanical Mechanisms of ARVF

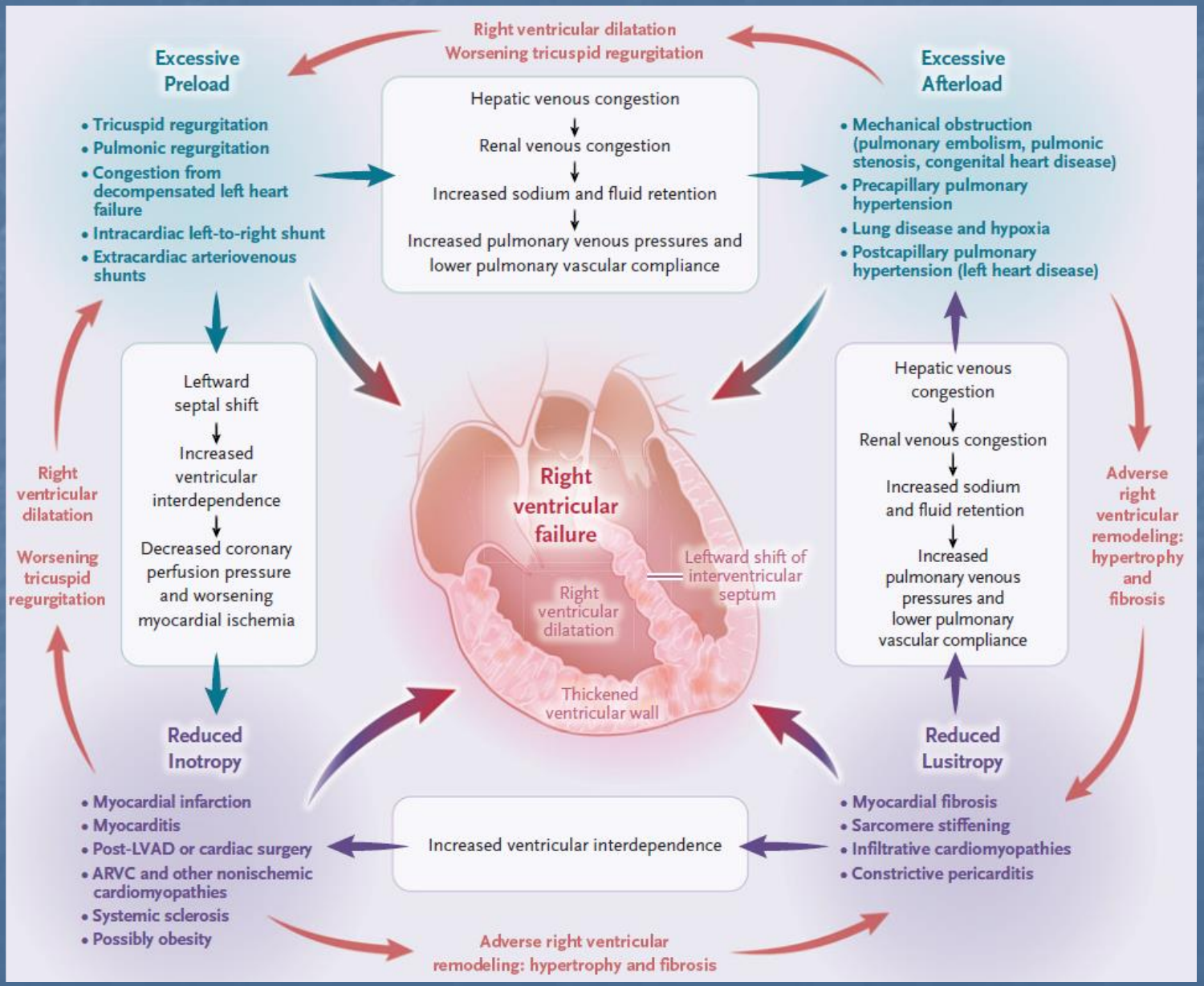

Molecular mechanisms of RVF

- Hypertrophy
- Ischemia
- Metabolic dysfunction
- Fibrosis

Molecular Mechanisms of Right Ventricular Failure

Hypertrophy

Patient-level factors

- Sex: estrogens may be protective
- Obesity: adverse effects on afterload, preload, and contractility
- Insulin resistance: fibrosis, inflammation, and lipotoxicity

↑ Contractility
Preserved stroke volume → Dilatation ↑ Heart rate ↑ Oxygen demand → ↓ Stroke volume Uncoupling

Compensated → Decompensated

Ischemia

Chronic pressure overload

Hypertrophy → ↑ Wall stress → ↓ Coronary perfusion Capillary rarefaction → **Oxygen supply and demand imbalance**

Hypertrophy → ↑ Oxygen demand → **Oxygen supply and demand imbalance**

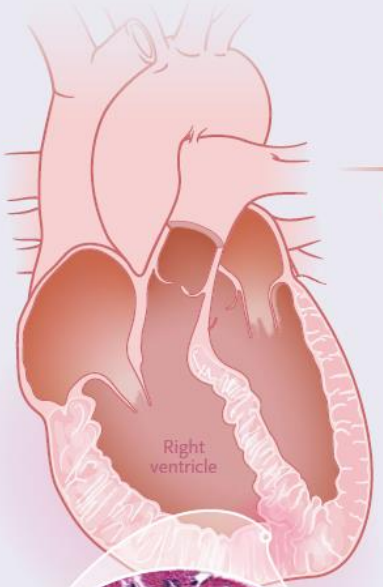

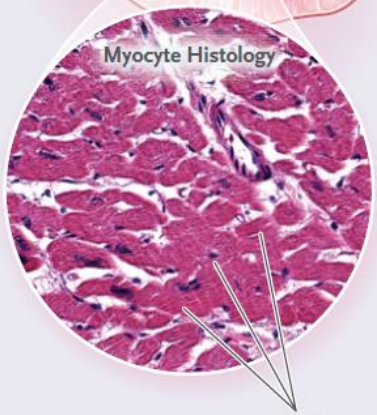

Metabolic dysfunction

Glycolytic switch
↑ PDK → ↑ Glucose uptake

Increased uptake
Decreased uptake

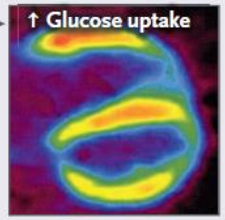

Mitochondrial dysfunction → ↓ Beta-oxidation → Lipotoxicity

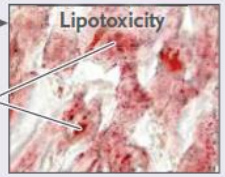

Lipotoxicity

Fission → ↑ ROS

Fibrosis

Increased fibrosis
Decreased fibrosis

Myofibroblast activation: interstitial, dynamic

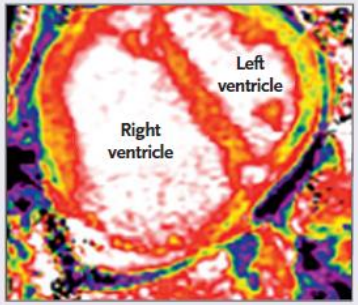

Mechanical stress: replacement, permanent

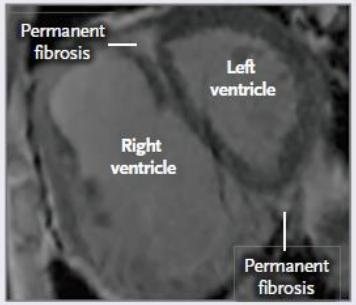

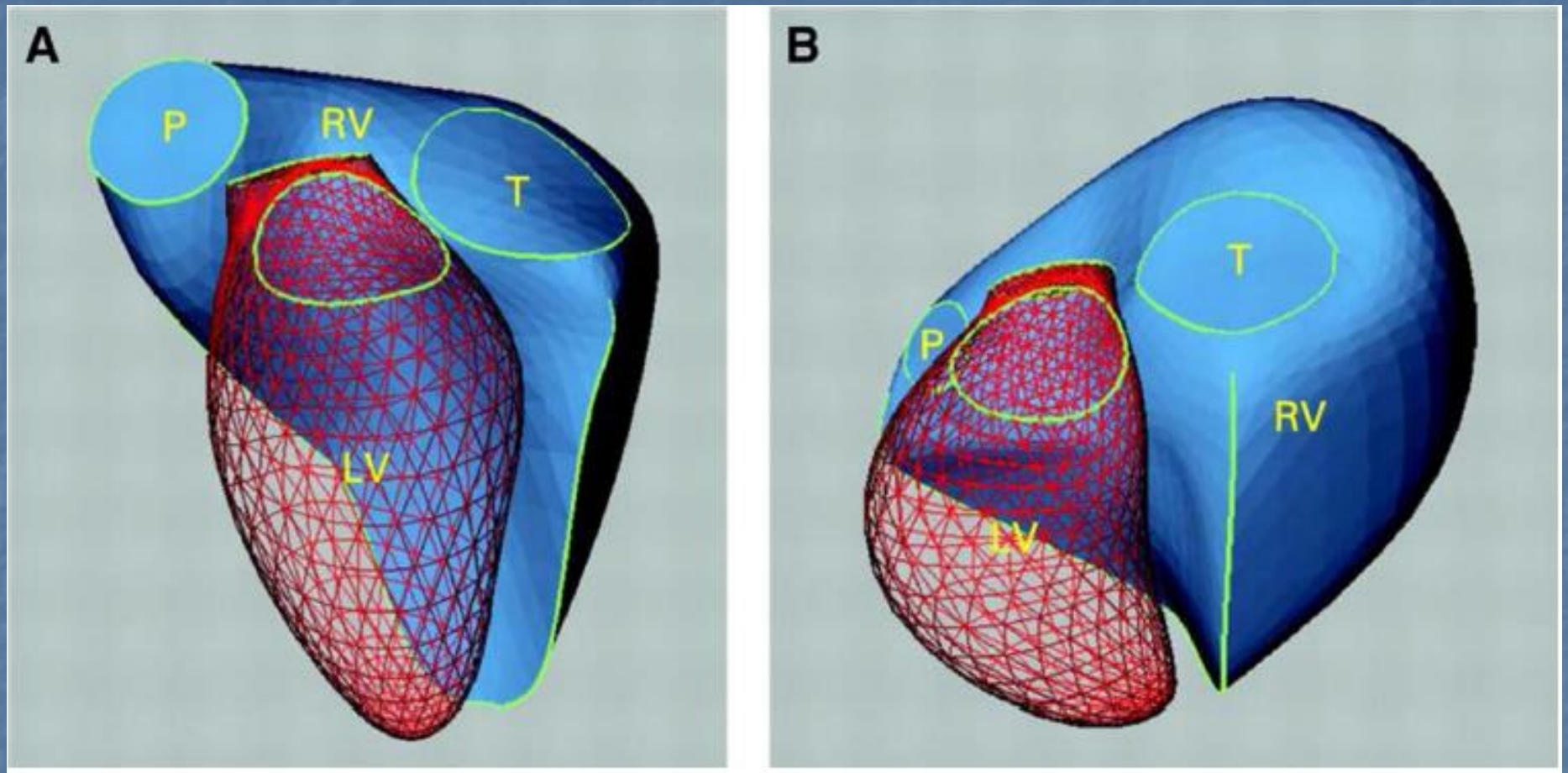

Fig. 4 Three dimensional reconstructions of the right ventricle (RV) illustrating its complex shape in a normal subject (A). RV remodeling in diseased hearts can result in profound shape change, as in this patient (B) with dilated RV due to severe pulmonary regurgitation following repair of tetralogy of Fallot. The mesh surface is the left ventricle. LV, left ventricle; P, pulmonary valve; RV, right ventricle; T, tricuspid valve. Reprinted from Sheehan and Redington [23] with permission from BMJ Publishing Group, Ltd.

Copyright © 2008, BMJ Publishing Group, Ltd

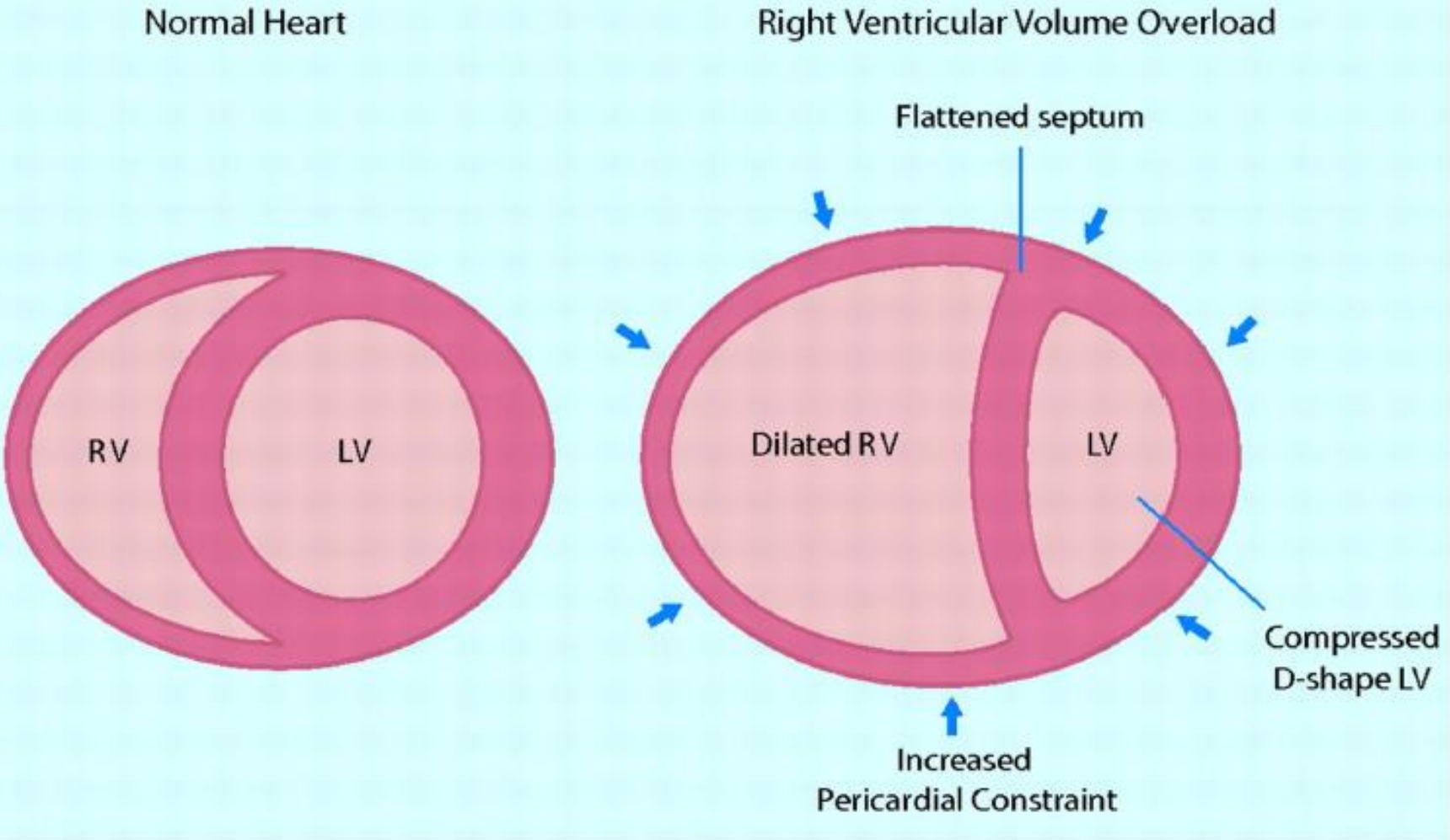

Fig. 5 The effects of RV volume overload on cardiac interactions. Right ventricular volume overload causes RV cavity dilation, which flattens the interventricular septum and increases pericardial constraint, ultimately compressing the left ventricular cavity. This leads to impaired LV diastolic filling, reduced LV distensibility and elastance, and decreased cardiac output. Reprinted with permission from Haddad F. et al. [22]

Heart lung interaction in ARVF

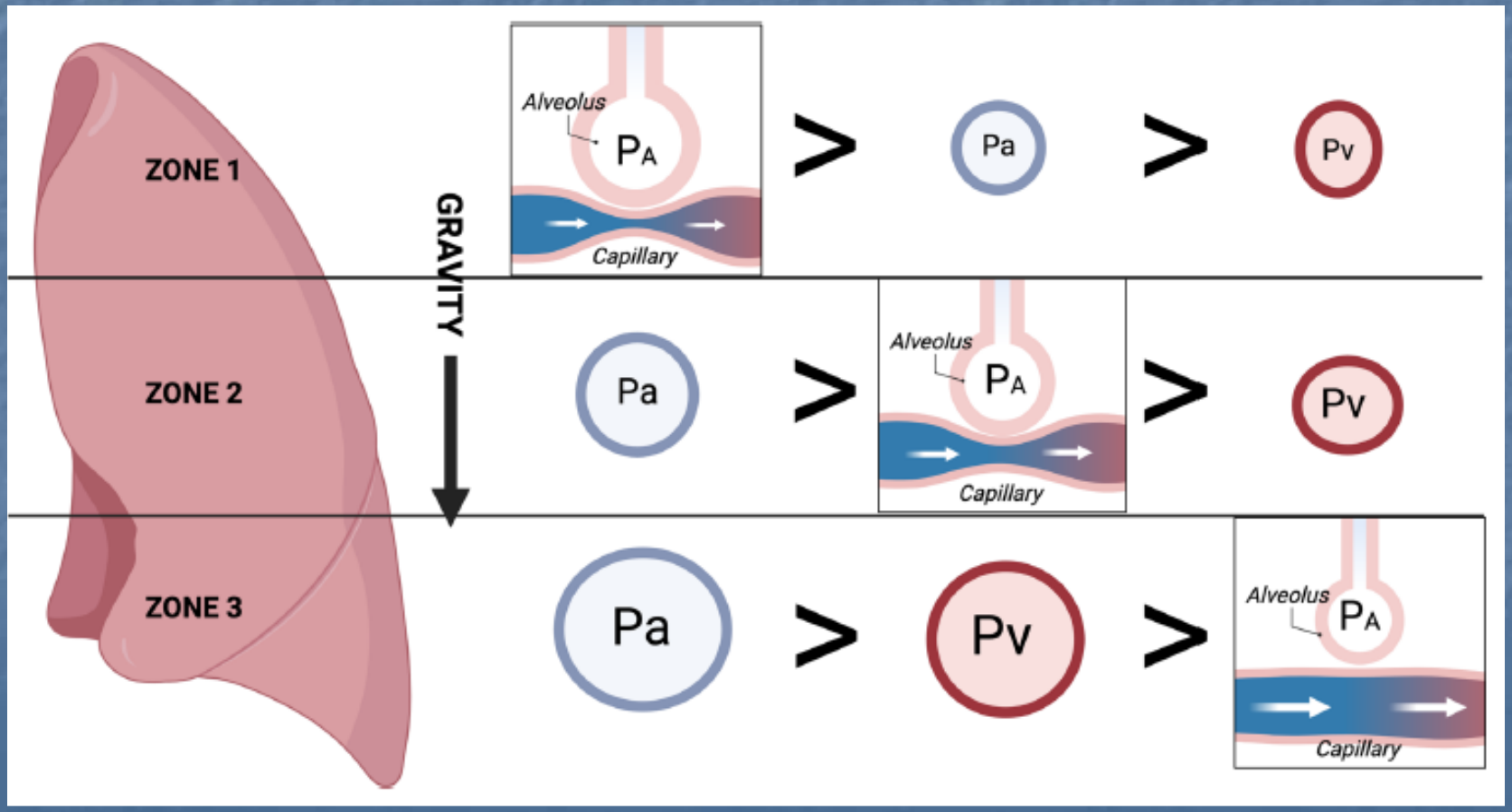

Diagnosis and Evaluation of ARVF

Diagnostic Tool	Findings
Detailed history	Symptoms of right heart failure: dyspnea, early satiety, abdominal fullness, lower-extremity edema, right-upper-quadrant tenderness, exercise intolerance, fatigue Associated conditions: coronary artery disease, left heart failure or valvular disease, chronic lung disease, venous thrombosis or embolism, connective tissue disease, human immunodeficiency virus infection Social history: tobacco use, illicit drug use, history of illicit or prescribed anorexigen use Family history: pulmonary arterial hypertension, left heart failure, sudden cardiac death, ARVC
Physical examination	Elevated jugular venous pressure, right ventricular heave, loud second component of second heart sound (P2), tricuspid regurgitation murmur, enlarged and pulsatile liver, hepatojugular reflux, ascites, lower-extremity edema
Serum biomarker	Elevated brain natriuretic peptide level
Electrocardiogram	Right atrial dilatation, right ventricular hypertrophy, right-axis deviation
Echocardiogram	Specific right ventricular measurements or findings: TAPSE, TAPSE:PASP ratio, tissue Doppler velocity at lateral tricuspid annulus, fractional area change, right ventricular strain, right ventricular hypertrophy, right atrial size Volumes, ejection fraction (three-dimensional imaging), tricuspid and pulmonary regurgitation, inferior vena cava diameter and collapsibility, leftward displacement or shift of interventricular septum Left heart disease: left ventricular hypertrophy, left atrial size, mitral and aortic valvular disease, left ventricular ejection fraction, left ventricular diastolic dysfunction, intracardiac shunts
Cardiac MRI	Right ventricular volumes (end-systolic and end-diastolic), right ventricular ejection fraction, delayed gadolinium enhancement or fibrosis, right ventricular or right atrial strain, left heart disease, intracardiac shunts, pericardium assessment
Right heart catheterization	RAP and right ventricular end-diastolic pressure, pulmonary-artery pressures (to detect pulmonary hypertension), pulmonary vascular resistance, pulmonary arterial compliance, pulmonary effective arterial elastance, PAWP, estimate of left atrial pressure, cardiac output or index, stroke volume or stroke volume index, pulmonary-artery oxygen saturation, RAP:PAWP ratio, PAPi, possibly measurement of right ventricular reserve with provocation (exercise or inotropes)

Echocardiography in ARVF

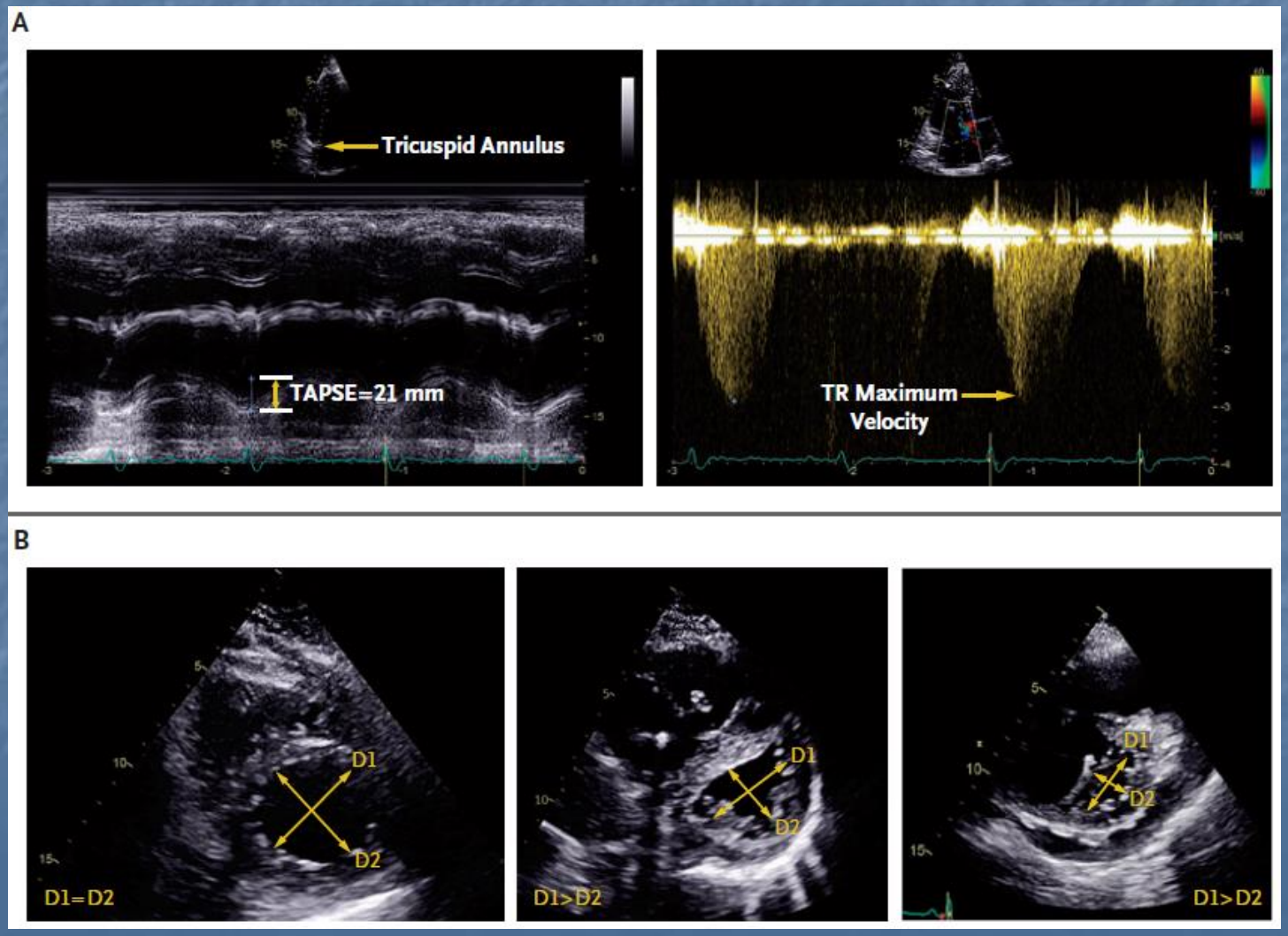

Treatment of ARVF

Physiological Target and Medications	Nonpharmacologic Therapy	Clinical Application
Preload reduction		
Loop diuretics: furosemide, bumetanide, torsemide Thiazide diuretics for augmentation of response to loop diuretics	Ultrafiltration, atrial septostomy	Beneficial for nearly all causes of chronic right ventricular failure with volume overload If response to diuretics is inadequate, ultrafiltration may be beneficial Atrial septostomy performed for palliation in severe pulmonary arterial hypertension
Afterload reduction		
Calcium-channel blockers: long-acting nifedipine, diltiazem, amlodipine Inhaled vasodilators (continuous): nitric oxide, prostacyclin analogues Endothelin receptor antagonists: bosentan, ambrisentan, macitentan Prostacyclin analogues: epoprostenol, treprostinil, iloprost Phosphodiesterase 5 inhibitors: sildenafil, tadalafil Soluble guanylate cyclase stimulator: riociguat	Mechanical obstruction alleviation, aortopulmonary shunt, lung transplantation	Calcium-channel blockers for vasoreactive pulmonary arterial hypertension (WSPH group 1); should be used only if pulmonary arterial hypertension is idiopathic or drug-associated and vasoreactivity has been shown on right heart catheterization with vasodilator study† Inhaled vasodilators for acute right ventricular failure or cardiogenic shock due to right ventricular failure Endothelin receptor antagonists, phosphodiesterase 5 inhibitors, soluble guanylate cyclase stimulators, and prostacyclin analogues for pulmonary arterial hypertension Inhaled treprostinil for ILD-associated pulmonary hypertension Mechanical obstruction alleviation for chronic thromboembolic pulmonary hypertension, congenital pulmonary vascular obstruction Aortopulmonary shunt for palliation in severe pulmonary arterial hypertension Lung transplantation for severe pulmonary arterial hypertension
Inotropic support		
$Beta_1$-agonists: dobutamine, epinephrine, dopamine Phosphodiesterase 3 inhibitor: milrinone Vasopressors: norepinephrine, vasopressin, phenylephrine Digoxin	NA	RV failure complicated by cardiogenic shock, malperfusion, or hypotension; digoxin may reduce symptoms in patients with chronic RV failure

Treatment of ARVF

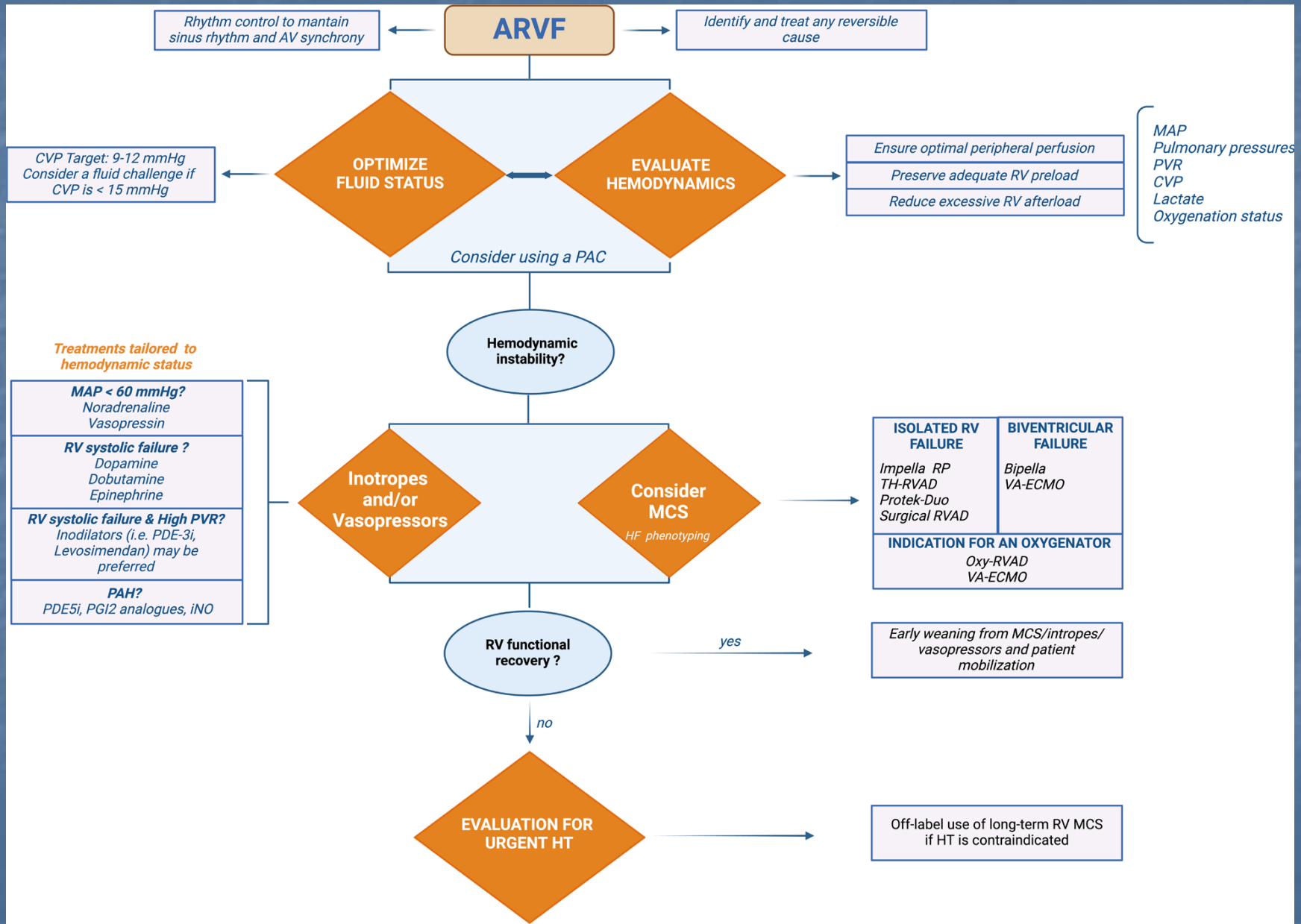

Temporary mechanical support devices for the treatment of ARVF

Direct RV bypass system

Indirect RV bypass system

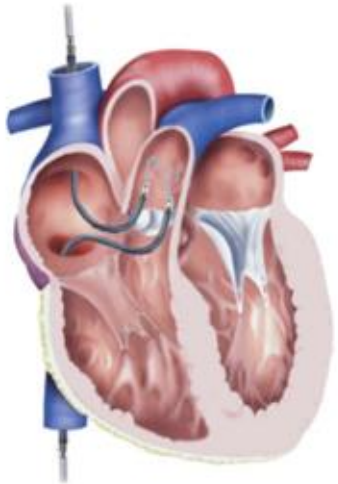

Impella RP

-Microaxial catheter based flow pump;

-22F cannula through femoral vein (or internal jugular vein in Impella RP flex);

-It provides up to 4L/min; approved for up to 14 days;

- ↓ RA pressure;

- ↑ PA pressure, LV preload

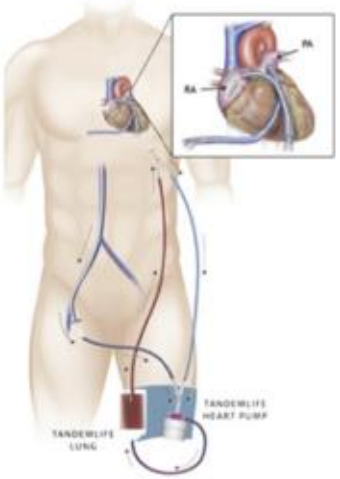

TH-RVAD

-Extracorporeal centrifugal flow pump;

-Two 21F inflow and outflow cannula (right and left femoral vein);

-It provides up to 4L/min; approved for 30 days;

- ↓ RA pressure;

- ↑ PA pressure, LV preload

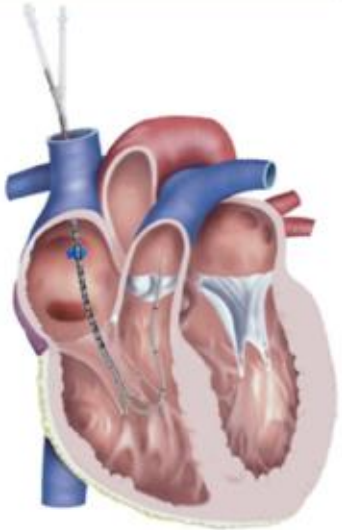

Protek-Duo

-Dual lumen Catheter;

-Two lumens : proximal lumen 29F or 31F; distal lumen 16F or 18.5F (internal jugular vein);

-It provides up to 4L/min; approved for 24 hours;

- ↓ RA pressure;

- ↑ PA pressure, LV preload

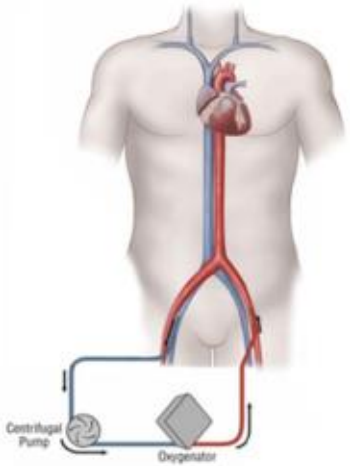

VA-ECMO

-Extracorporeal centrifugal flow pump;

-One venous cannula (femoral, jugular or sub-clavian vein); one 17-21F arterial cannula (femoral or axillary)

-It provides 4-6L/min; approved for 9 days;

- ↓ RA pressure and LV preload;

- ↑ LV afterload

Clinical Studies Evaluating Mechanical Support Devices for Treatment of ARVF

Type of MCS	Study population	Survival	Complications
Impella RP[66]	n=30 (post-LVAD n=18; postcardiotomy or AMI n=12)	30 d overall survival 73.3%	Major bleeding (60%) Hemolysis (13%)
Impella RP[69]	n=39 (post-LVAD n=6; PE n=9; postcardiotomy n=8; post-AMI n=11; NICM n=5)	30 d overall survival 49% (from 27% to 80% depending on etiology)	Hemolysis (25.6%) Major bleeding not reported
Impella RP[70]	n=31 (post-LVAD n=7; postcardiotomy n=7; post-AMI n=13; PE n=2; post pericardiectomy n=2)	30 d overall survival 74%	Not reported
Impella RP[71]	n=12 adolescents (post-HT n=5; myocarditis n=2; postcardiotomy n=2; NICM n=3)	Survival to hospital discharge 83%	Pump thrombosis (8%) No major bleeding or hemolysis observed
Impella RP[72]	n=60 (post-LVAD n=31; postcardiotomy, HT or AMI n=29)	30 d overall survival 72%	Major bleeding (48.3%) Hemolysis (21.7%) Tricuspid/pulmonary valve dysfunction (2.9%)
TH-RVAD[64]	n=46 (postvalve surgery n=15; post-AMI n=12; post-HT n=5; post-LVAD n=5; post-CABG n=3; myocarditis or NICM n=6)	Survival to hospital discharge 43.4% (highly variable depending on the etiology from 0% to 80%)	Major bleeding (44%) Deep venous thrombosis (4.3%) PA damage (4.3%)
Protek Duo[73]	n=27 (post-LVAD implantation)	One year survival 81%	New moderate to severe TR (36%) Hemolysis (18%)
TH-RVAD[74]	n=9 (postcardiotomy n=2; post-AMI n=6; sepsis n=1)	Survival to hospital discharge 56%	Major bleeding (44.4%)
Protek Duo[75]	n=11 (postlung resection n=4; post-LVAD n=1; NICM n=1; PE n=1; AMI n=1; respiratory distress n=2; postvalve surgery n=1)	30 d survival 82% 180 d survival 72%	Major bleeding (45.5%) Sepsis (63.6%) Stroke (18.2%)
Protek Duo[76]	n=40 (postcardiotomy n=18; CS n=12; respiratory failure n=10)	Overall survival to discharge 67.5%	Device migration (7.5%) SVC syndrome (7.5%); Pump thrombosis (2.5%)
Protek Duo[77]	n=11 (post-LVAD n=11)	30 d survival 72.7%	Not reported (1 patient died for intracranial bleeding)

Thanks for your attention

