
نام خداوند جان و خرد
کزین برتر اندیشه برنگذرد

18th International Congress of Anesthesiology, Critical Care and Pain

Motor Sparing Regional Analgesia

Dr Elham Memary ,MD

Full Professor of SBMU

Regional Anesthesia Fellowship

Imam Hossein Hospital

18–20 November 2026 · Tehran, Iran · From Innovation to Resilience

Motor Sparing Analgesia



Faster Recovery
Function Preservation
Improvements in ERAS Protocols

Regional anesthesia :a central component of multimodal strategies to improve perioperative pain management

Enhances analgesic efficacy also reduces opioid requirements and mitigates opioid-related adverse effects.

By targeting peripheral nociceptive pathways:

- ❑ Attenuation of surgical stress response
- ❑ Improved hemodynamic stability
- ❑ Enhanced pulmonary function
- ❑ Earlier ambulation especially for motor sparing RA
- ❑ Faster gastrointestinal recovery
- ❑ Greater patient satisfaction especially for motor sparing RA

- ❑ **Motor Sparing Analgesia for Hand Surgery**
- ❑ **Motor Sparing Analgesia for Hip Surgery**
- ❑ **Motor Sparing Analgesia for Knee Surgery**
- ❑ **Motor Sparing Analgesia for Ankle Surgery**

Motor Sparing Analgesia for Hand Surgery

Ultrasound-guided motor-sparing forearm blocks for hand surgery: surgical and anesthetic perspectives

Chao-Ying Kowa [1], Behdad Ravarian [2], Heather Baltzer [2] and Ki Jinn Chin [1, 3]

Correspondence to Dr Ki Jinn Chin; gasgenie@gmail.com

Abstract

Introduction Certain specialized hand surgery procedures benefit from intraoperative motor testing and patient-demonstrated active range of motion. This requires motor-sparing regional anesthesia of the hand using targeted ultrasound-guided nerve blocks in the forearm.

Objective We present a joint surgical and anesthetic perspective covering the utility and indications for motor-sparing forearm blocks. We describe the anatomical principles and technical details of their performance and discuss other considerations for surgical and anesthetic success.

Findings Patient selection and expectation setting are critical for success. Four terminal nerves must be blocked: median nerve, ulnar nerve, superficial radial nerve, and lateral antebrachial cutaneous nerve. These must be targeted distal to origin of motor branches to extrinsic muscles of the hand, with precise deposition of limited volumes of local anesthetic. The nerves can be readily identified with ultrasound imaging by their predictable anatomical relationship to specific muscles and blood vessels.

Conclusion Intraoperative motor testing in complex surgical repair of the hand is associated with improved surgical outcomes, as well as greater patient satisfaction. Ultrasound-guided motor-sparing forearm blocks are a safe and effective method for achieving surgical anesthesia and optimal operating conditions in this context.

https://doi.org/10.1136/rapm-2025-107388

1. **Median nerve**

2. **Ulnar nerve**

3. **Superficial Radial nerve**

4. **Lateral antebrachial cutaneous nerve (branch of musculocutaneous nerve)**

NOTE:Cutaneous infiltration is needed for incisions at the level of the wrist

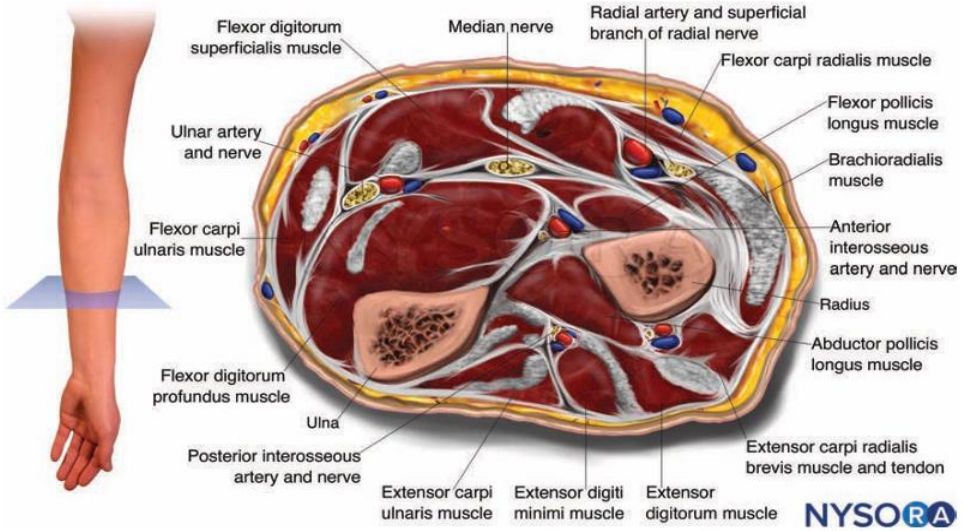

FIGURE 20-3. Cross-section anatomy at the level of the mid-forearm.

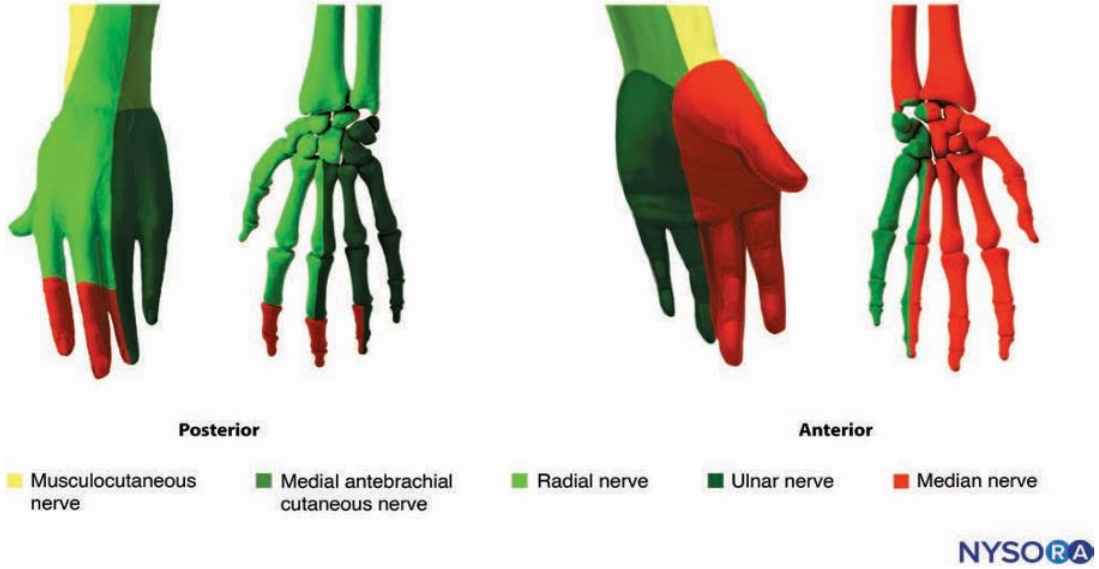

FIGURE 20-4. Anesthesia distribution after a wrist block.

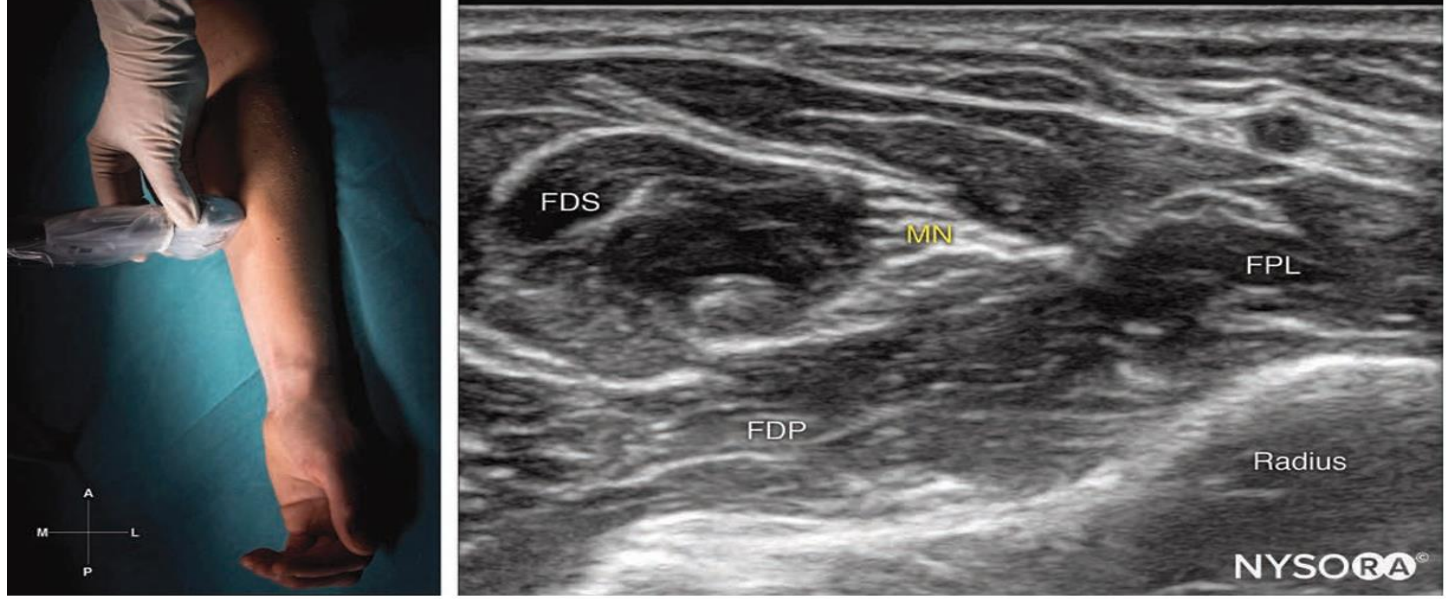

FIGURE 20-6. Transducer position and sonoanatomy of the median nerve (MN) at the level of the mid-forearm. FPL, flexor pollicis longus muscle; FDS, flexor digitorum superficialis muscle; FDP, flexor digitorum profundus.

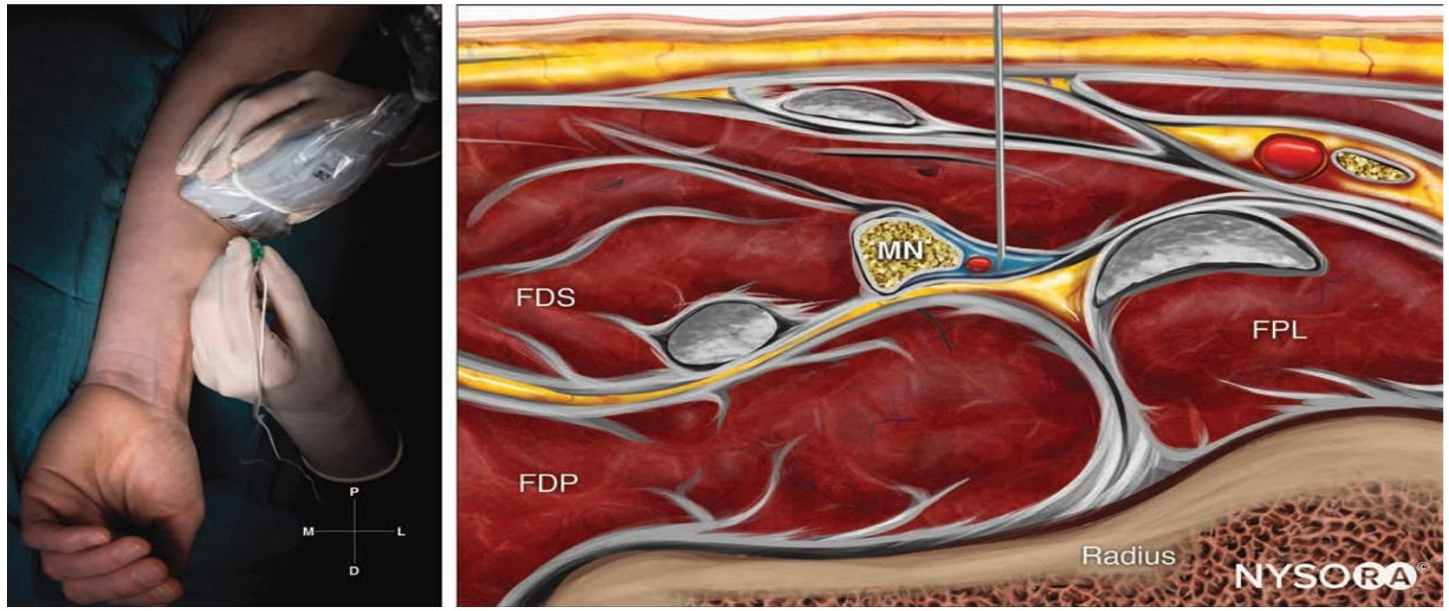

FIGURE 20-7. Reverse ultrasound anatomy of the median nerve (MN) at the level of the mid-forearm with needle insertion out-of-plane. FPL, flexor pollicis longus muscle; FDS, flexor digitorum superficialis muscle; FDP, flexor digitorum profundus.

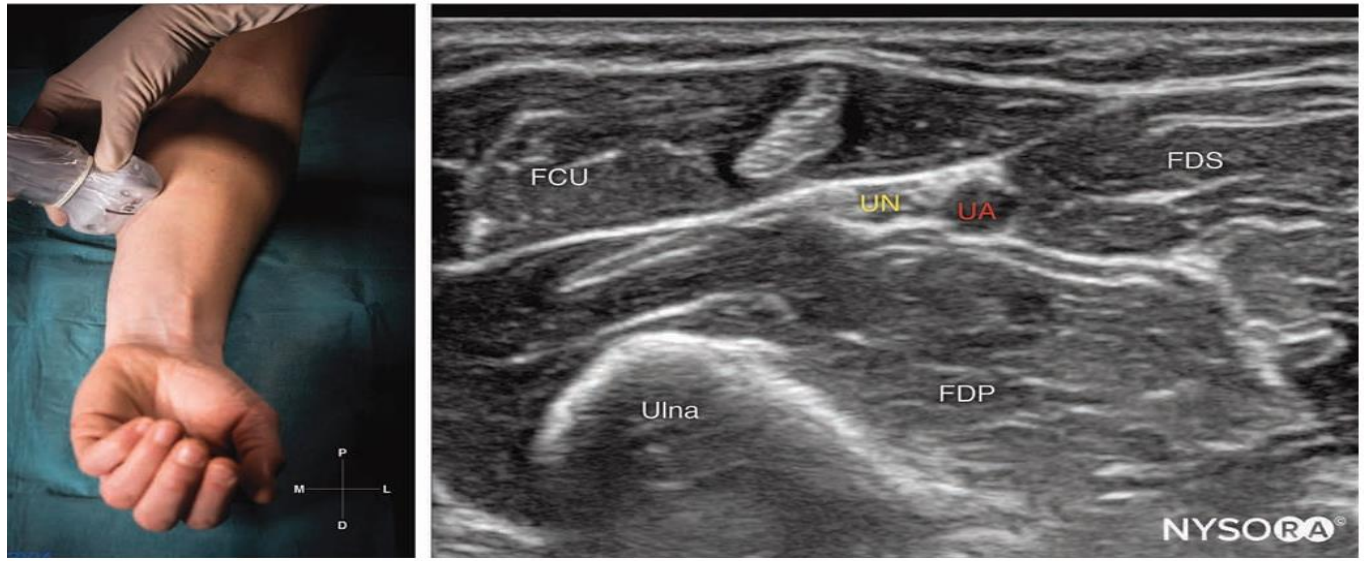

FIGURE 20-8. Transducer position and sonoanatomy of the ulnar nerve (UN) at the level of the mid-forearm. UA, ulnar artery; FCU, flexor carpi ulnaris; FDP, flexor digitorum profundus muscle; FDS, flexor digitorum superficialis muscle.

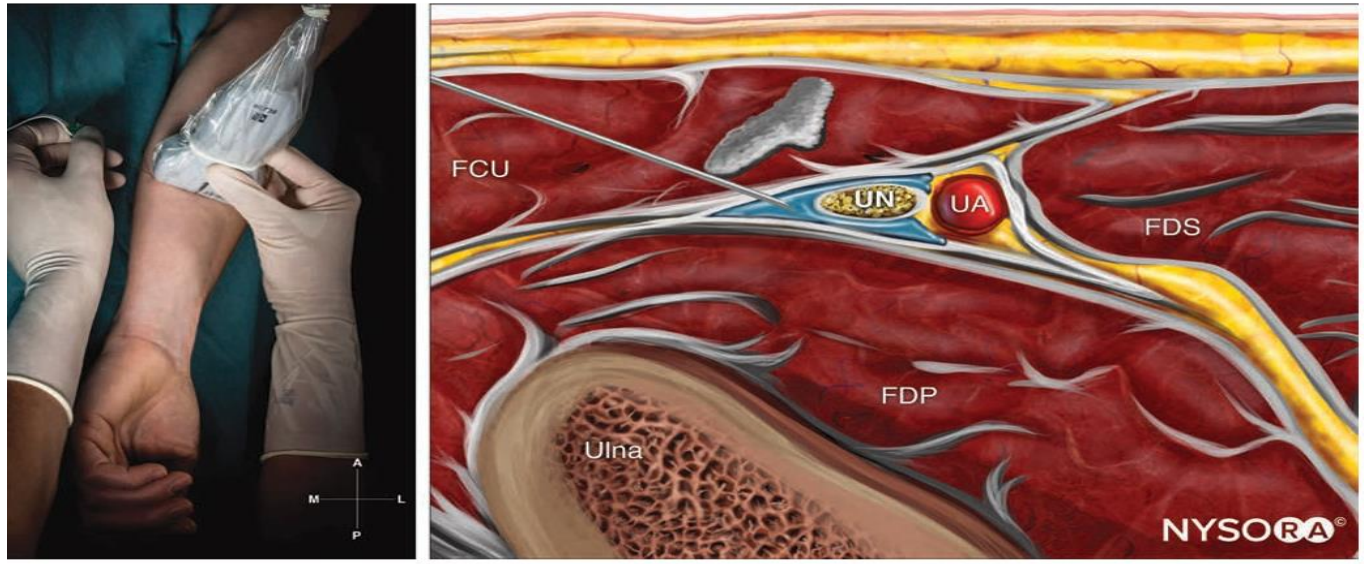

FIGURE 20-9. Reverse ultrasound anatomy of the ulnar nerve at the mid-forearm with needle in-plane and local anesthetic injection in blue. FDS, flexor digitorum superficialis muscle; FDP, flexor digitorum profundus muscle; FPL, flexor pollicis longus.

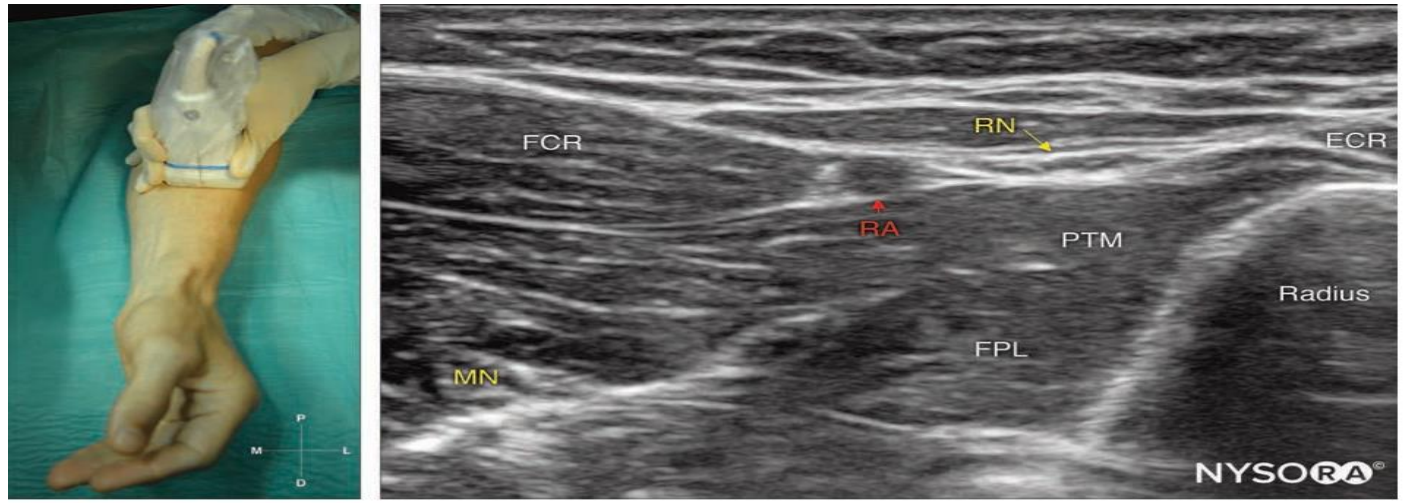

FIGURE 20-10. Sonoanatomy and transducer position for radial nerve (RN) block at the level of the mid-forearm. FCR, flexor carpi radialis; MN, median nerve; FPL, flexor pollicis longus; PTM, pronator teres muscle; ECR, extensor carpi radialis.

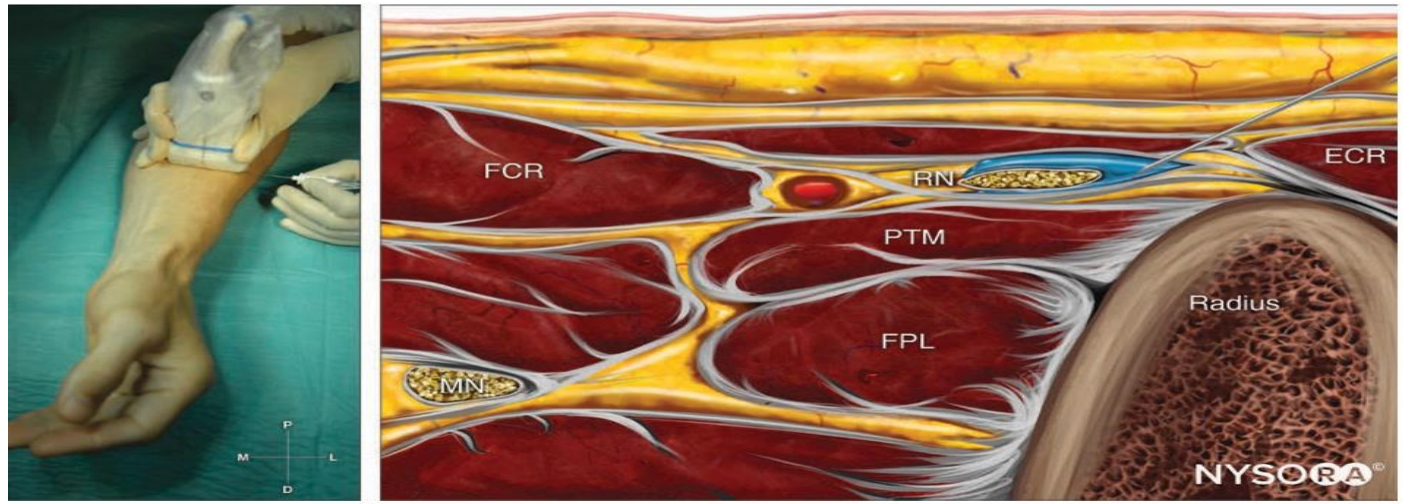

FIGURE 20-11. Reverse ultrasound anatomy of the superficial branch of the radial nerve (RN) at the level of the mid-forearm with needle insertion in-plane. FCR, flexor carpi radialis; MN, median nerve; FPL, flexor pollicis longus; PTM, pronator teres muscle; ECR, extensor carpi radialis.

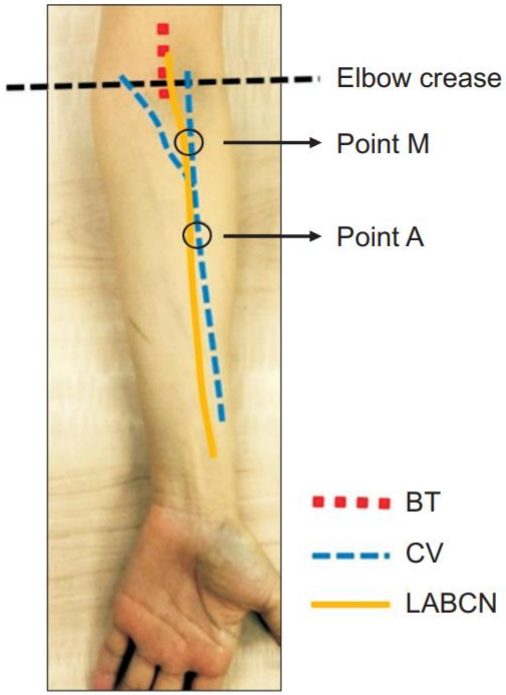

Fig. 1. Schematic relationship of the lateral antebrachial cutaneous nerve (LABCN), cephalic vein (CV), and biceps tendon (BT) at the anterior aspect of the forearm. Point M, meeting point of LABCN and CV; Point A, point where LABCN and CV come apart.

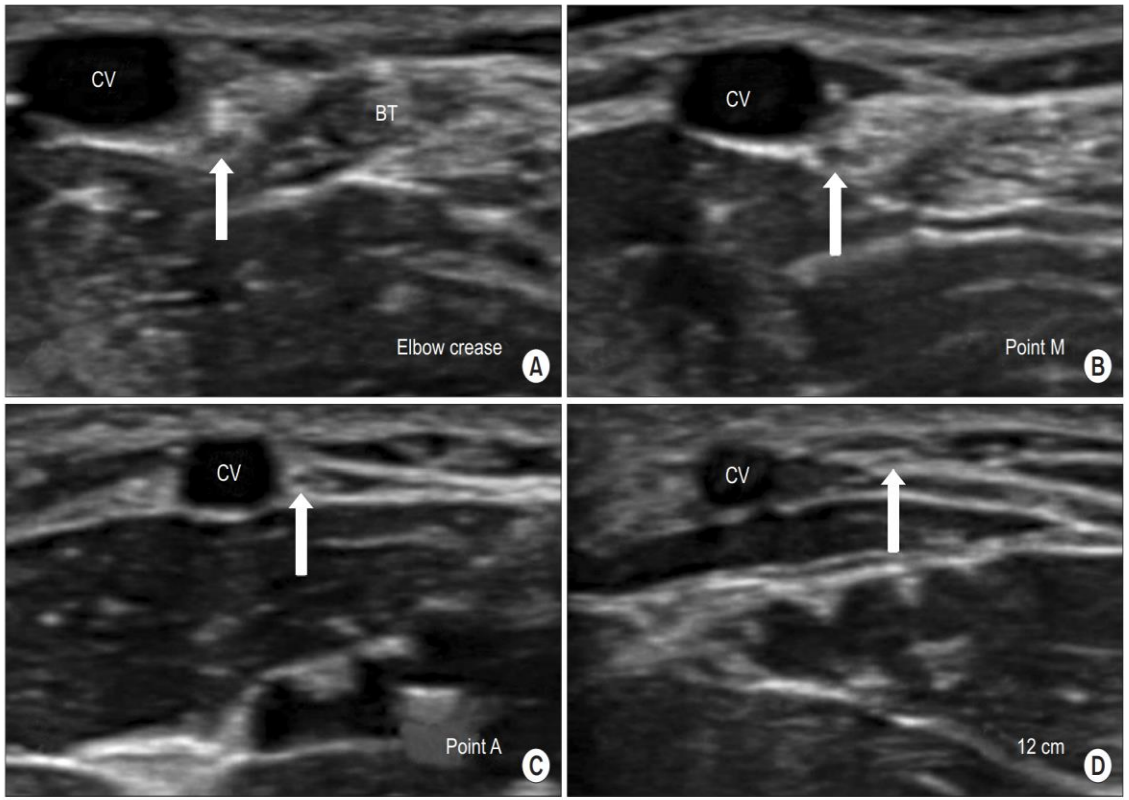

Fig. 2. Transverse view of ultrasonographic images of the course of the LABCN (arrows) at the elbow crease level (A), at the level of point M and A (B, C), and at the distal 12 cm level (D). LABCN, lateral antebrachial cutaneous nerve; CV, cephalic vein; Point M, meeting point of LABCN and CV; Point A, point where LABCN and CV come apart.

Motor Sparing Analgesia for Hip Surgery

Analgesic Benefits of Motor-sparing Fascial Plane Blocks in Comparison to Periarticular Local Infiltration Analgesia for Total Hip Arthroplasty: A Network Meta-analysis

Nasir Hussain, Richard Brull, Alex T. Freedenberg[3], Chris Vannabouathong[4], Ryan S. D'Souza[5], Steven Havlik[6], Peyton Beachy[7], Antonius Gunawan[8], Tristan E. Weaver[9], Daniel I. McIsaac[10], Colin J. L. McCartney[11], Faraj W. Abdallah[12]

Authors and Affiliations >

Anesthesiology 143(3):p 604-624, September 2025. | **DOI:** 10.1097/ALN.0000000000005607

Background:

Periarticular local infiltration analgesia has become an important mainstay of multimodal analgesia after elective total hip arthroplasty (THA). However, the role of novel motor-sparing fascial plane blocks—with or without periarticular local infiltration analgesia—has not been fully elucidated for patients undergoing THA. The authors conducted a network meta-analysis evaluating the relative analgesic effectiveness of motor-sparing fascial plane blocks (quadratus lumborum, erector spinae, and pericapsular nerve group blocks) and periarticular local infiltration analgesia for adult patients undergoing THA.

Methods:

Randomized trials examining single-injection quadratus lumborum, erector spinae, or pericapsular nerve group blocks, or periarticular local infiltration analgesia, for THA were sought. The primary outcome was area under the curve (AUC) rest pain scores during the period from 0 to 24 h. Secondary outcomes included rest pain scores at 0, 6, 12, and 24 h; postoperative function at 6, 12, and 24 h; analgesic consumption at 0 to 24 h; incidence of opioid-related side effects; and incidence of block-related complications. Network meta-analysis was performed using a frequentist approach.

Results:

A total of 44 trials (3,579 patients) evaluating the quadratus lumborum block, erector spinae block, pericapsular nerve group block, or periarticular local infiltration analgesia for THA were considered. Network meta-analysis was used to derive the probability of each intervention being the most effective as compared to the others (P score). For AUC 0 to 24 h rest pain, periarticular local infiltration analgesia was the most effective intervention, as demonstrated by a P score of 89%. For postoperative analgesic consumption, the quadratus lumborum block was the most effective intervention, with a P score of 88%. This was followed by the pericapsular nerve group block (74%), the erector spinae block (38%), and periarticular local infiltration analgesia (42%).

Conclusions:

Periarticular local infiltration analgesia alone provides the most consistent improvements in postoperative rest pain, analgesic consumption, and functional recovery after THA. The addition of a quadratus lumborum block or pericapsular nerve group block to periarticular local infiltration may further improve analgesic outcomes.

1. PERI CAPSULAR NERVE GROUP BLOCK(PENG)
2. QUADRATUS LUMBORUM BLOCK (QL)
3. ERECTOR SPINAE PLANE BLOCK (ESP)
4. LOCAL INFILTRATION ANALGESIA (LIA)

PERICAPSULAR NERVE GROUP BLOCK (PENG)

- Block of the sensory-articular branches of the anterior hip joint capsule

  Femoral N , Obturator N , Accessory Obturator N

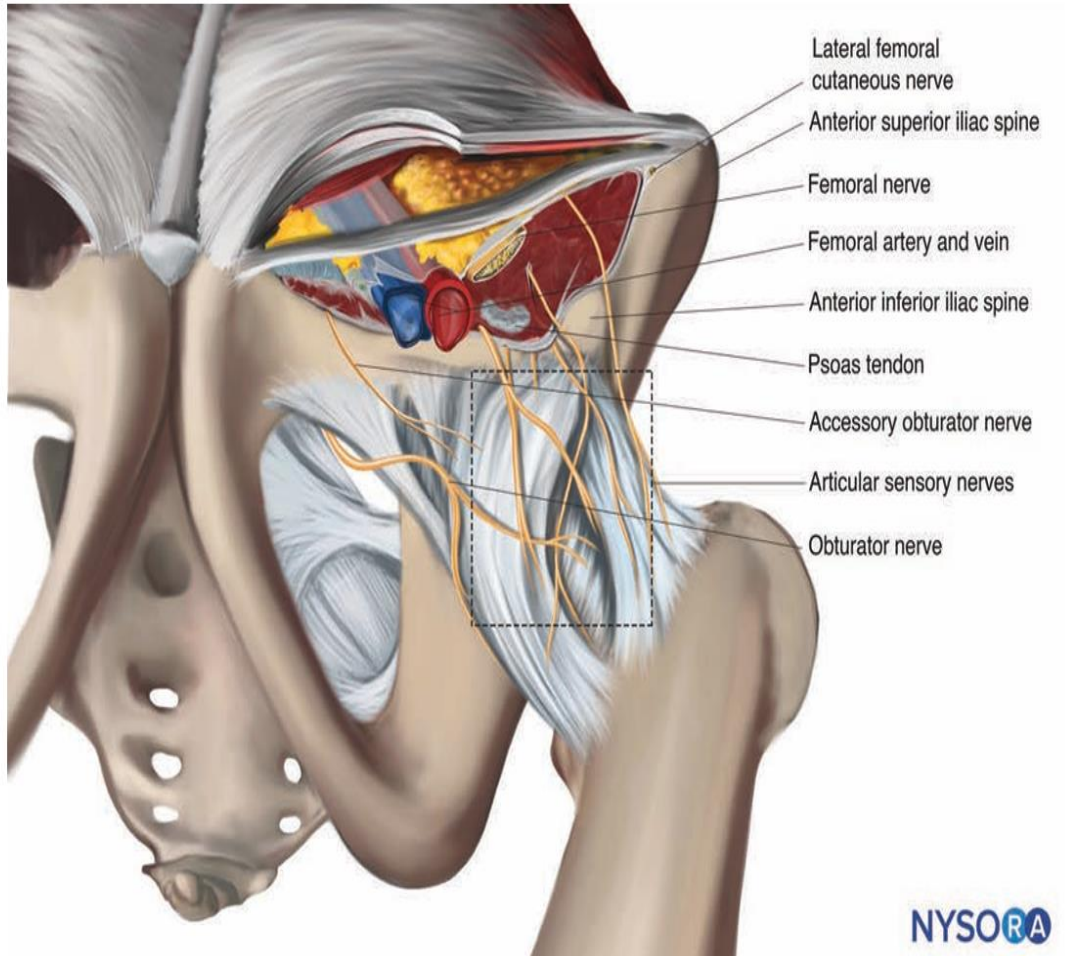

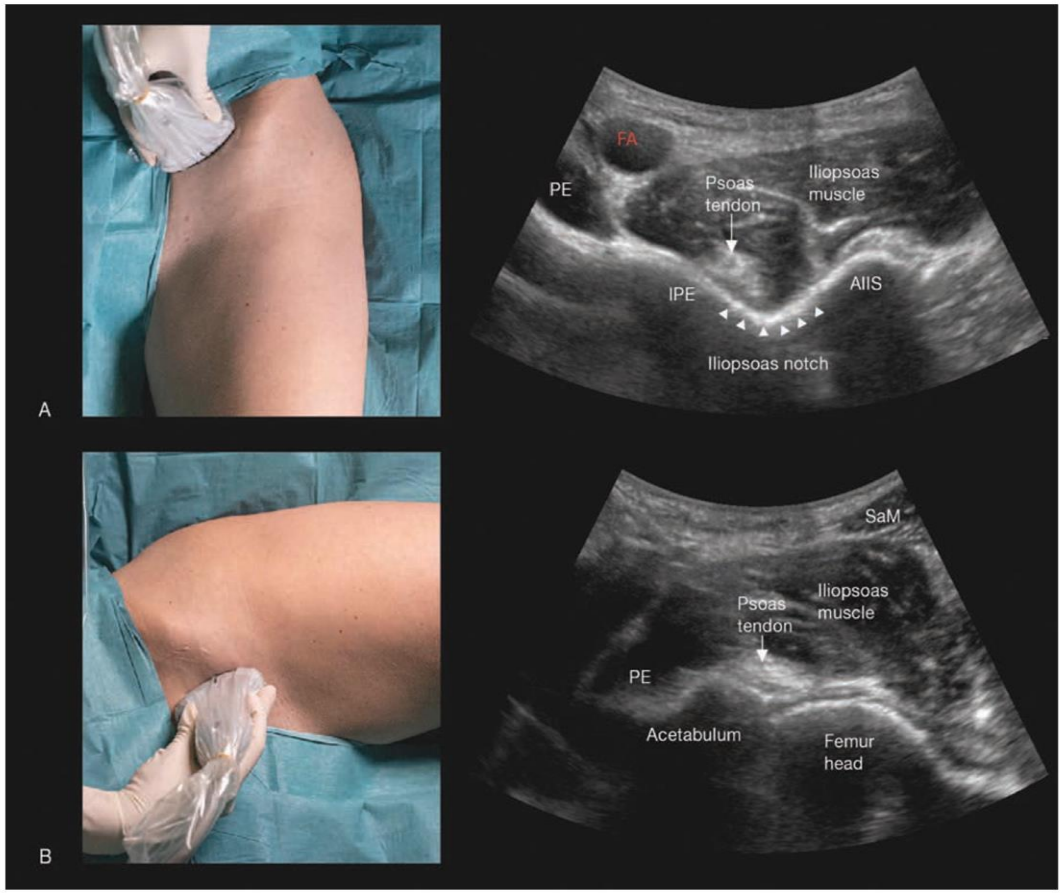

FIGURE 23-2. Transducer position and sonoanatomy to perform a hip block. A. Pericapsular nerve group block B. Iliopsoas plane block. FA, femoral artery; PE, pectineus muscle; IPE, iliopubic eminence; AIIS, anterior inferior iliac spine; SaM, sartorius muscle.

Quadratus Lumborum Block
(QL BLOCK)

- Interfascial plane injections of LA at different locations to the QL
  (lateral, posterior or anterior)
- Block of the anterior rami of spinal nerves T10-L1 and the paravertebral sympathetic chain
- Local anesthetic volume :15-30 mL

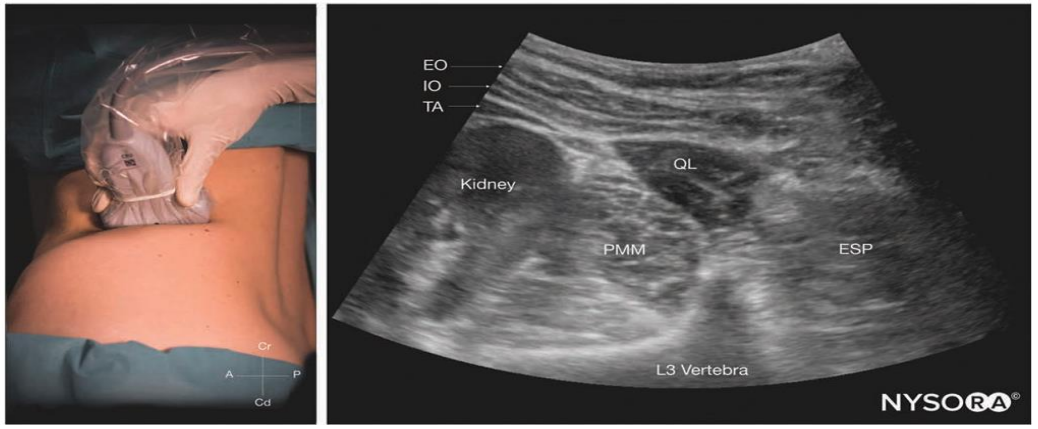

FIGURE 40-7. Transducer position and sonoanatomy to perform either a QL2 or a QL3 block. EO, external oblique muscle; IO, internal oblique muscle; TA, transversus abdominis muscle; QL, quadratus lumborum; PMM, psoas major muscle; ESP, erector spinae muscles.

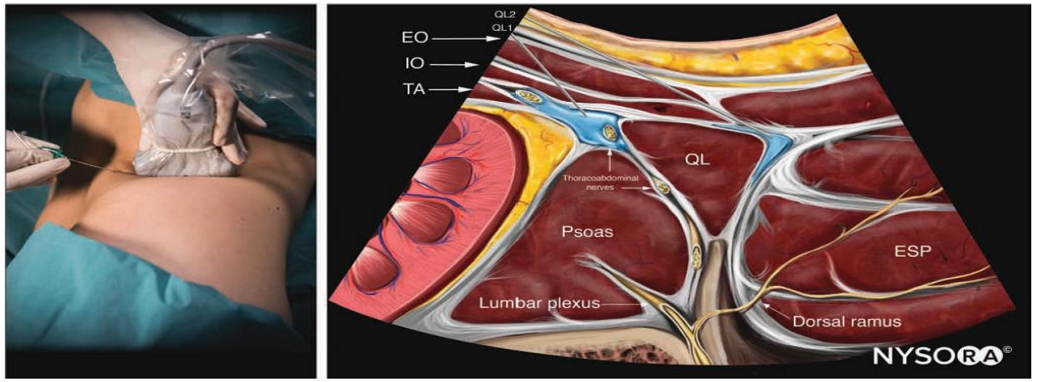

FIGURE 40-8. Reverse ultrasound anatomy of a QL1 or a QL2 block with needle insertion in-plane. EO, external oblique muscle; IO, internal oblique muscle; TA, transversus abdominis muscle; QL, quadratus lumborum; ESP, erector spinae muscles.

ERECTOR SPINAE PLANE BLOCK (ESP BLOCK)

- LA between the erector spinae muscles and the transverse processes at the segmental levels supplying the area of interest.
- Spread of an LA in the plane deep to the erector spinae muscles
- Craniocaudal distribution along several vertebral levels
- Block the posterior and possibly anterior rami of the spinal nerves
- Local anesthetic volume :20-30mL

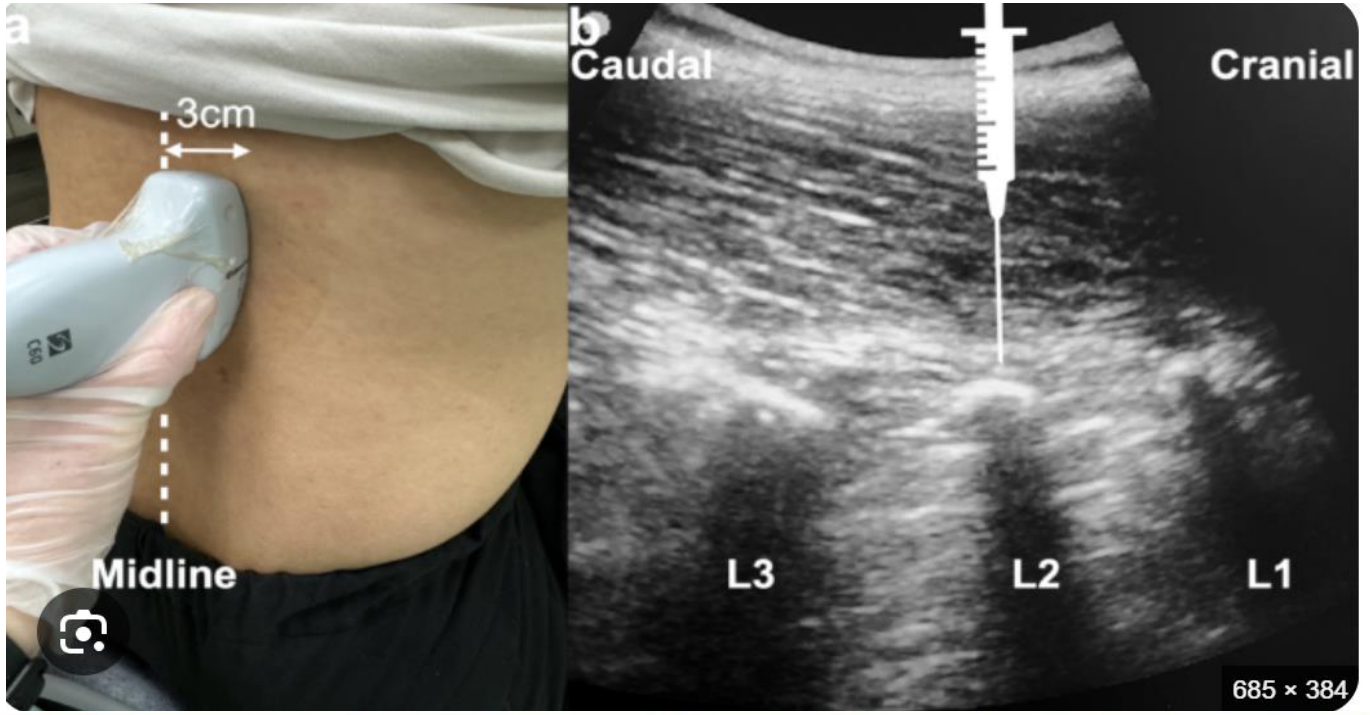

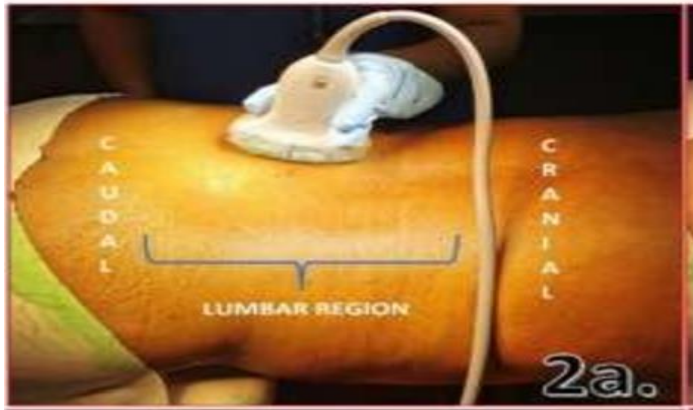

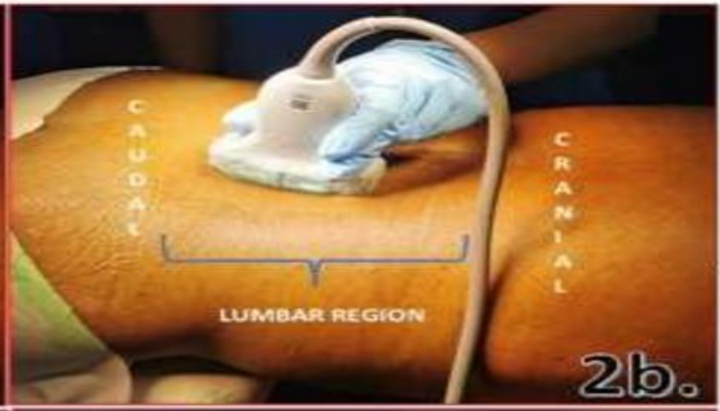



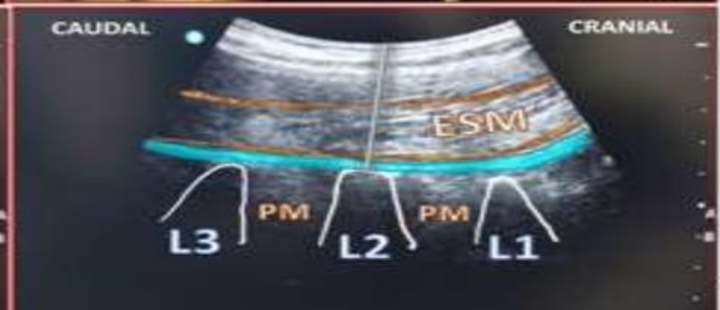

Motor Sparing Analgesia for Knee Surgery

BJA

Editor's key points

- Total knee arthroplasty is associated with severe postoperative pain. Enhancing recovery after total knee arthroplasty with effective analgesia is key to early mobilisation and hospital discharge.
- This narrative review and systematic literature search discusses innovations in motor-sparing regional anaesthesia techniques that have improved recovery after total knee arthroplasty.
- Targeted surgical local infiltration analgesia, adductor canal blockade, genicular nerve blocks, and the iPACK block are promising approaches that facilitate postoperative analgesia.
- Motor-sparing regional anaesthesia approaches contribute to multimodal analgesia to reduce opioid use and improve functional recovery.

British Journal of Anaesthesia, 134 (2): 510–522 (2025)

doi: 10.1016/j.bja.2024.10.041

Advance Access Publication Date: 2 January 2025

Review Article

REGIONAL ANAESTHESIA

Motor-sparing regional anaesthesia for total knee arthroplasty: a narrative and systematic literature review

Leigh White[1,2,*], Michael Kerr[3,4,5], Christopher Thang[1,2,5] and Amit Pawa[6,7]

Summary

Total knee arthroplasty is a life-changing surgical procedure that is associated with a high incidence of severe postoperative pain. Key to enhancing recovery after surgery is effective analgesia and early mobilisation. Innovations in motor-sparing regional anaesthesia techniques that have improved recovery include targeted surgical local infiltration analgesia, adductor canal blockade, genicular nerve blocks, and the infiltration between the popliteal artery and posterior capsule of the knee (iPACK) block. This narrative review discusses the current available motor-sparing regional anaesthetic techniques and assesses the evidence supporting each.

1. ***ADDUCTOR CANAL BLOCK (ACB)***

2. ***GENICULAR NERVE BLOCKS***

3. **INFILTRATION BETWEEN THE POPLITEAL ARTERY AND CAPSULE OF THE KNEE (IPACK)**

4. ***LOCAL INFILTRATION ANALGESIA (LIA)***

5

Adductor canal block

- medial and anteromedial knee analgesia while preserving quadriceps strength.
- Compared to femoral nerve blocks, ACB results in similar pain control with significantly less motor impairment.

Sub-sartorial / femoral triangle / adductor canal

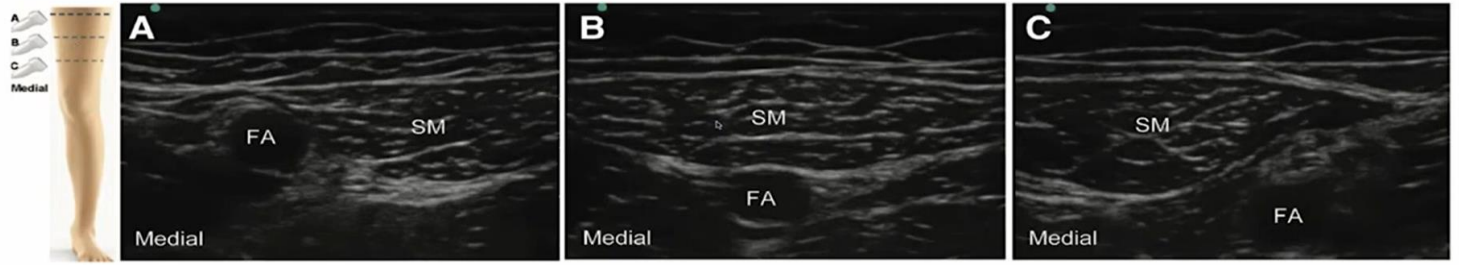

Fig. 1. Relative ultrasound probe positions and sonographic configurations of the sartorius muscle and femoral artery examined in this study. These include the muscle in lateral (*A*), superimposed (*B*), and medial position (*C*) relative to the artery. FA, femoral artery; SM, sartorius muscle.

Femoral triangle



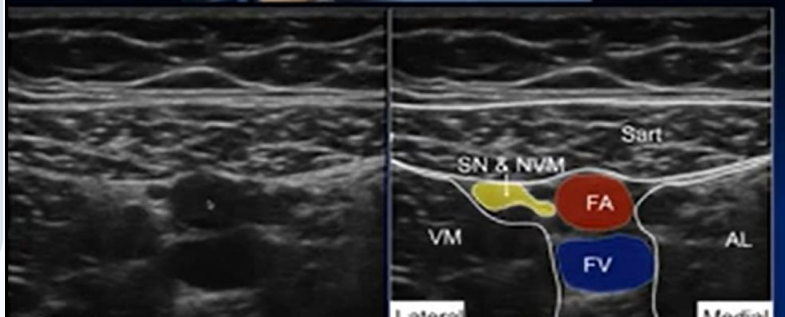

Adductor canal



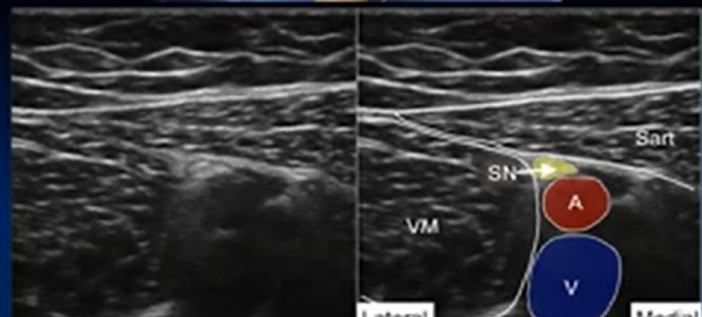

Genicular Nerve Blocks

- Targeting key sensory nerves around the knee
- Reduction of pain scores and opioid requirements

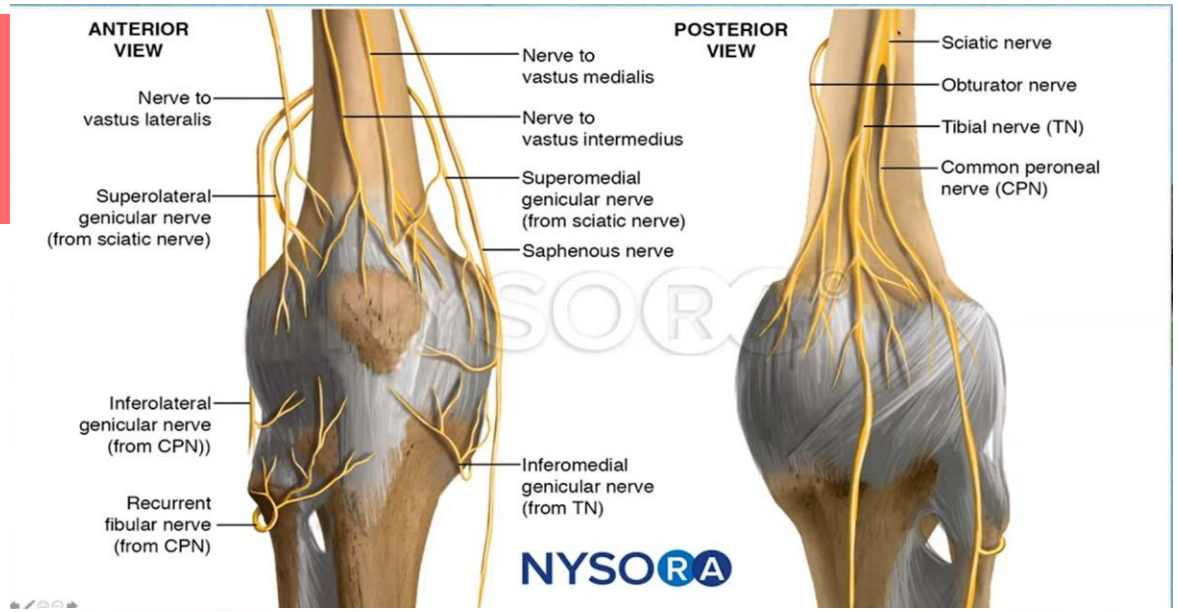

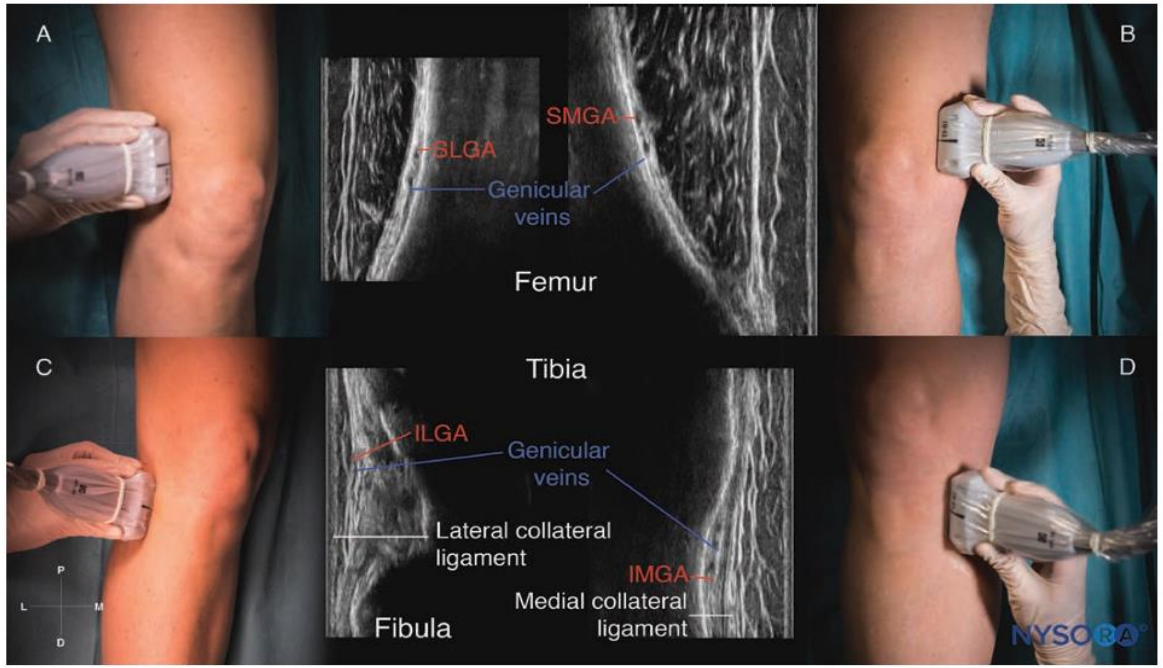

FIGURE 30-2. Sonoanatomy of the genicular nerves in a coronal plane. SLGA, superolateral genicular artery; SMGA, superomedial genicular artery; ILGA, inferolateral genicular artery; IMGA, inferomedial genicular artery. (A) Transducer position and sonoanatomy of the superomedial genicular nerve. (B) Transducer position and sonoanatomy of the inferomedial genicular nerve. (C) Transducer position and sonoanatomy of the superolateral genicular nerve. (D) Transducer position and sonoanatomy of the inferolateral genicular nerve.

Infiltration between the Popliteal Artery and Posterior Capsule of the Knee (*IPACK)*

- Block of the sensory-articular branches of Tibialis nerve (TN) and Common peroneal nerve(CPN)
- Anesthesia for posterior knee capsule the without affecting motor function
- No foot drop that occurs with the sciatic nerve block
- IPACK is highly effective as a standalone technique

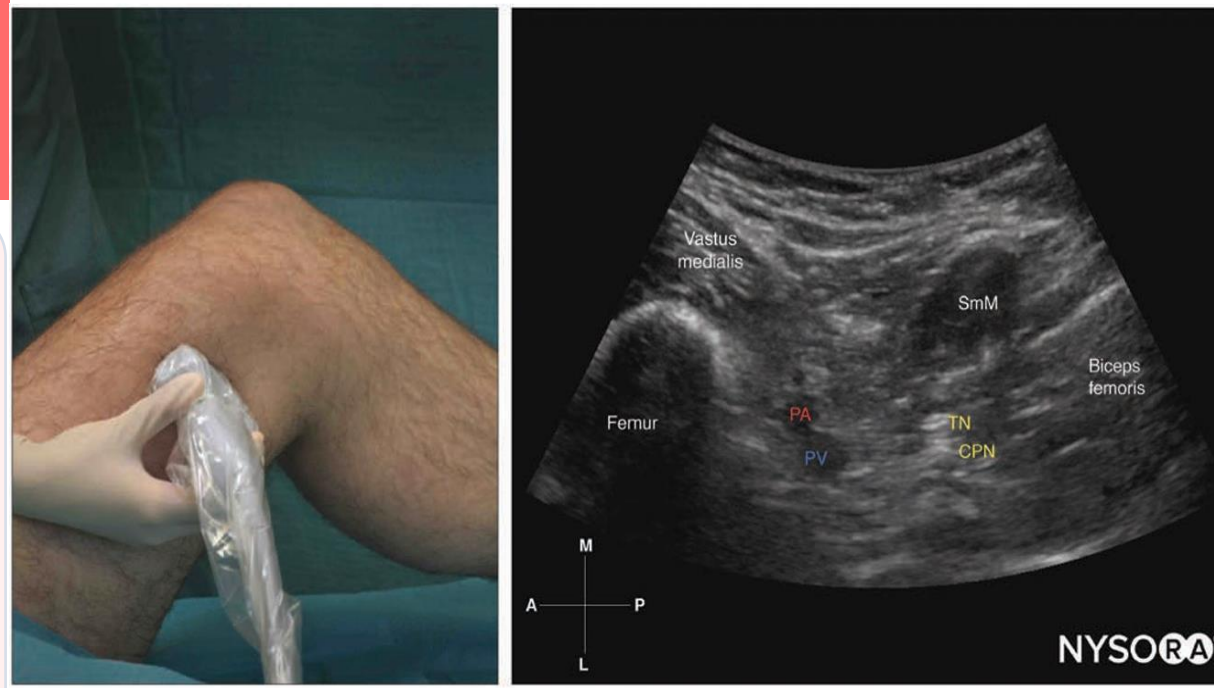

FIGURE 31-4. Transducer position and sonoanatomy for an iPACK block. SmM, semimembranosus muscle; StM, semitendinosus muscle; PA, popliteal artery; PV, popliteal vein; TN, tibial nerve; CPN, common peroneal nerve.

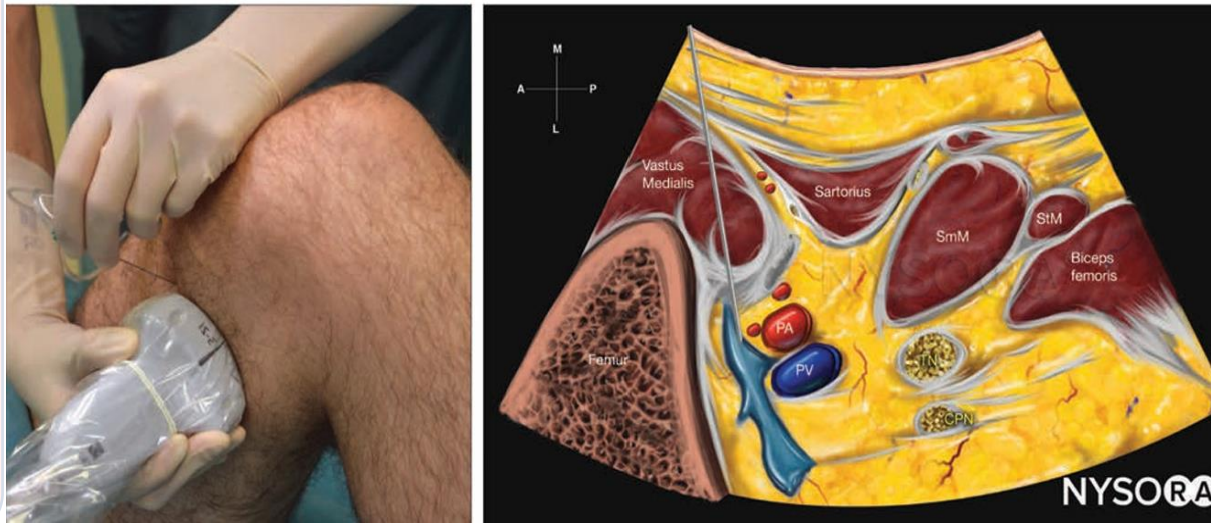

Motor Sparing Analgesia for Foot Surgery

Ankle Block

- Traditional techniques based on surface landmarks
- Ultrasound (US) : precise identification of each nerve consistent blockade and lower volumes of LA
- The main advantage of the ankle block : preservation of ankle mobility and facilitation of ambulation

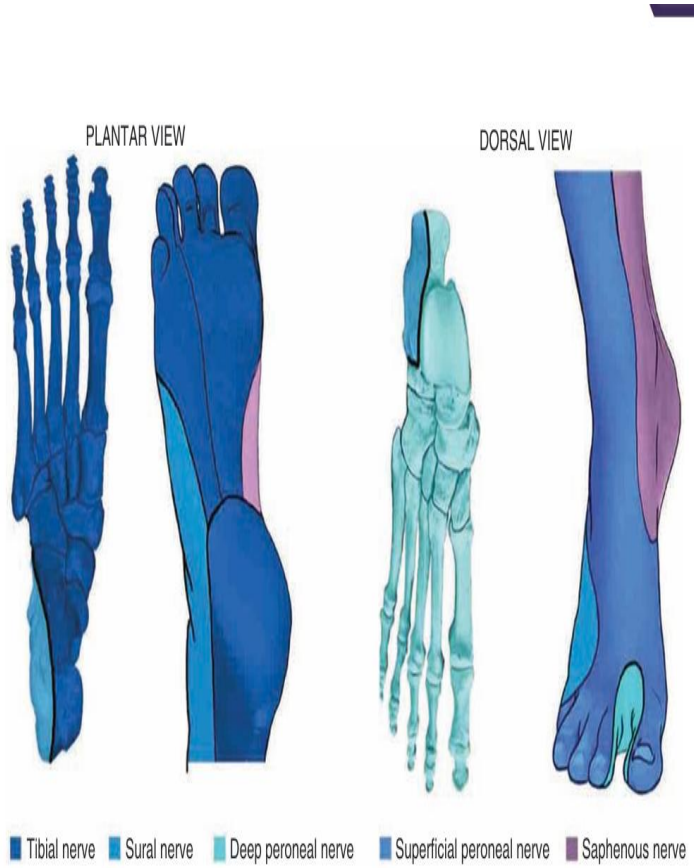

FIGURE 32-3. Sensory block distribution of the ankle.

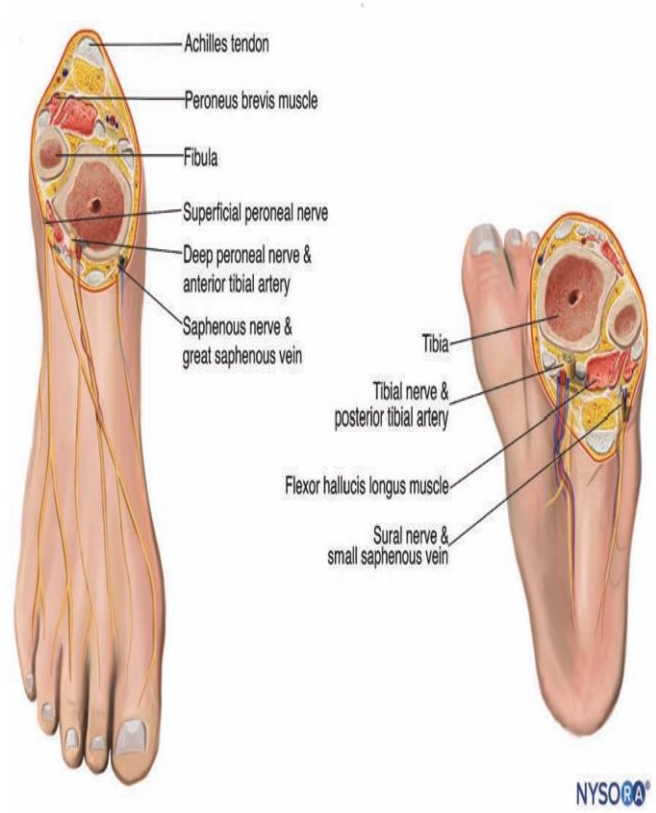

FIGURE 32-1. Relative position of the terminal nerves at the level of the ankle.

1. POSTERIOR TIBIALIS NERVE
2. SAPHENOUS NERVE
3. DEEP PERONEAL NERVE
4. SURAL NERVE
5. SUPREFICIAL PERONEAL NERVE

Posterior Tibialis Nerve Block

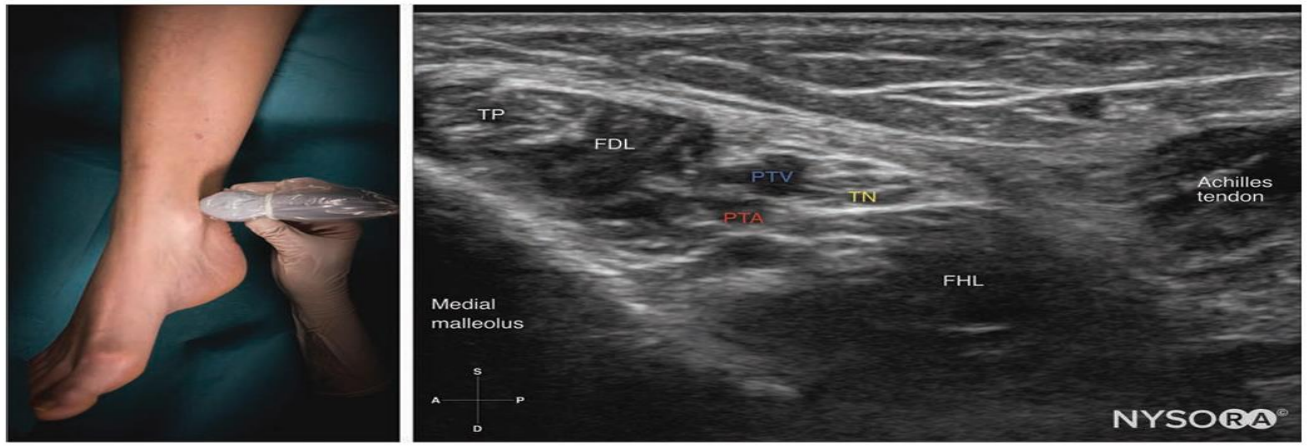

FIGURE 32-5. Transducer position and ultrasound anatomy to block the tibial nerve block. TP, tibialis posterior muscle; FDL, flexor digitorum longus; PTA, posterior tibial artery; PTV, posterior tibial vein; TN, tibial nerve; FHL, flexor hallucis longus.

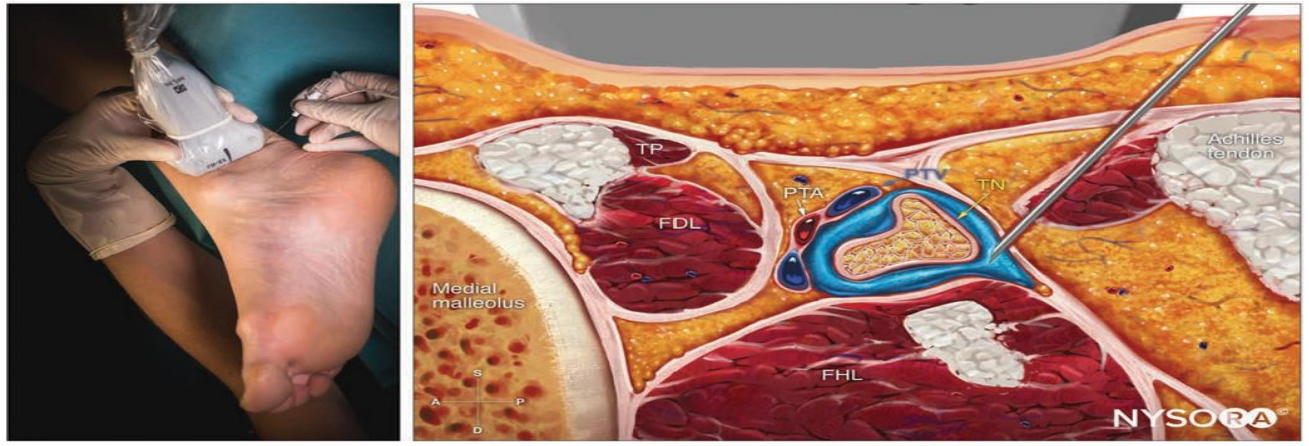

FIGURE 32-6. Reverse ultrasound anatomy of tibial nerve block with needle insertion in-plane. TP, tibialis posterior muscle; FDL, flexor digitorum longus; PTA, posterior tibial artery; PTV, posterior tibial vein; TN, tibial nerve; FHL, flexor hallucis longus.

Deep Peroneal Nerve Block

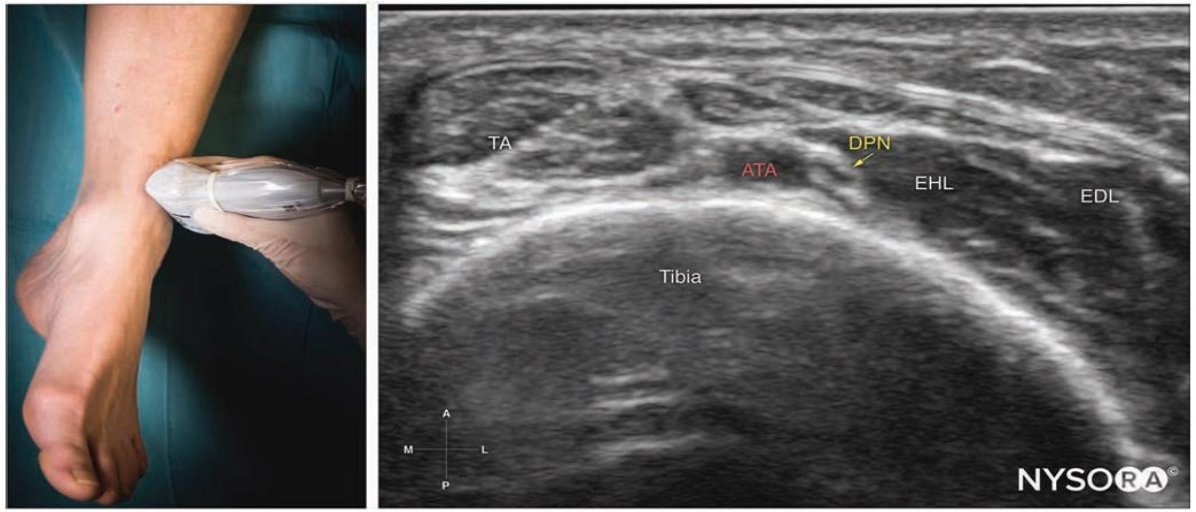

FIGURE 32-7. Transducer position and ultrasound anatomy to block the deep peroneal nerve. TA, tibialis anterior muscle; ATA, anterior tibial artery; DPN, deep peroneal nerve; EHL, extensor hallucis longus; EDL, extensor digitorum longus.

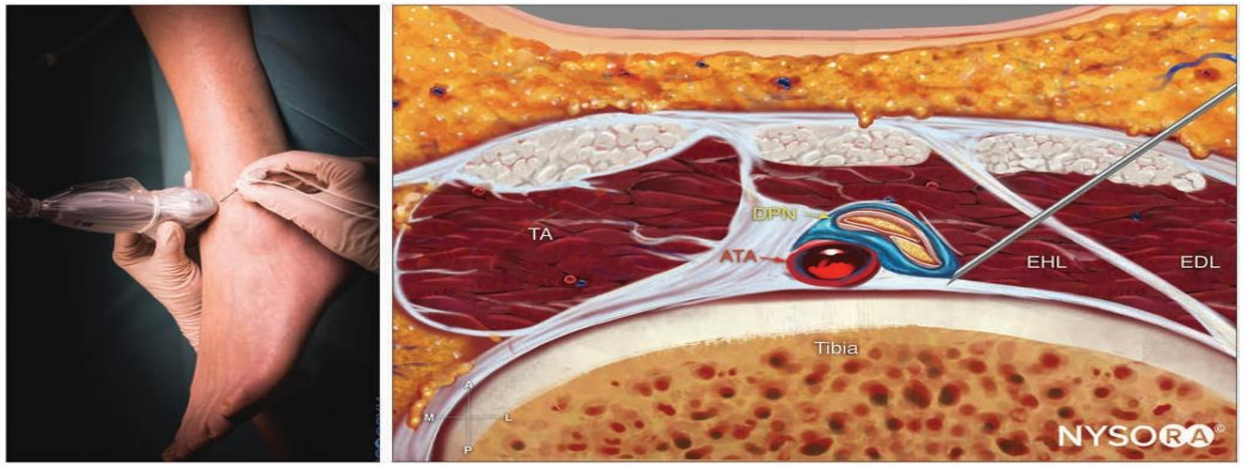

FIGURE 32-8. Reverse ultrasound anatomy of the deep peroneal block with needle insertion in-plane. TA, tibialis anterior muscle; ATA, anterior tibial artery; DPN, deep peroneal nerve; EHL, extensor hallucis longus; EDL, extensor digitorum longus.

Superficial Peroneal Nerve Block

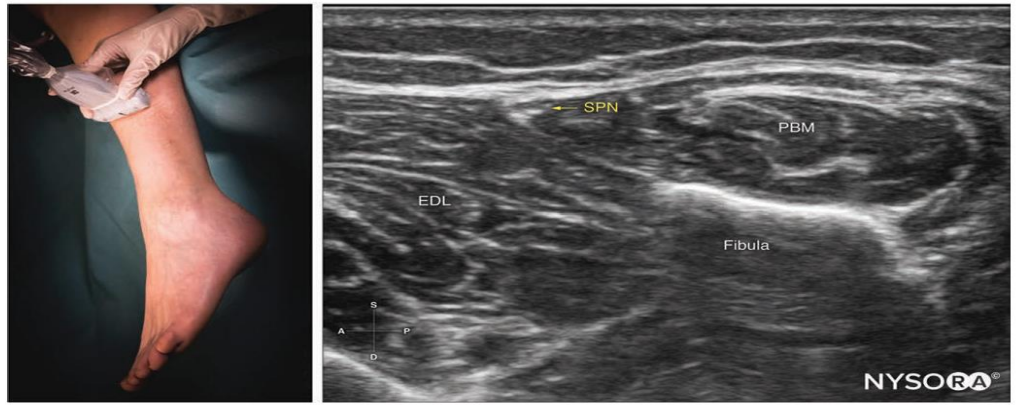

FIGURE 32-9. Transducer position and ultrasound anatomy to block the superficial peroneal nerve. EDL, extensor digitorum

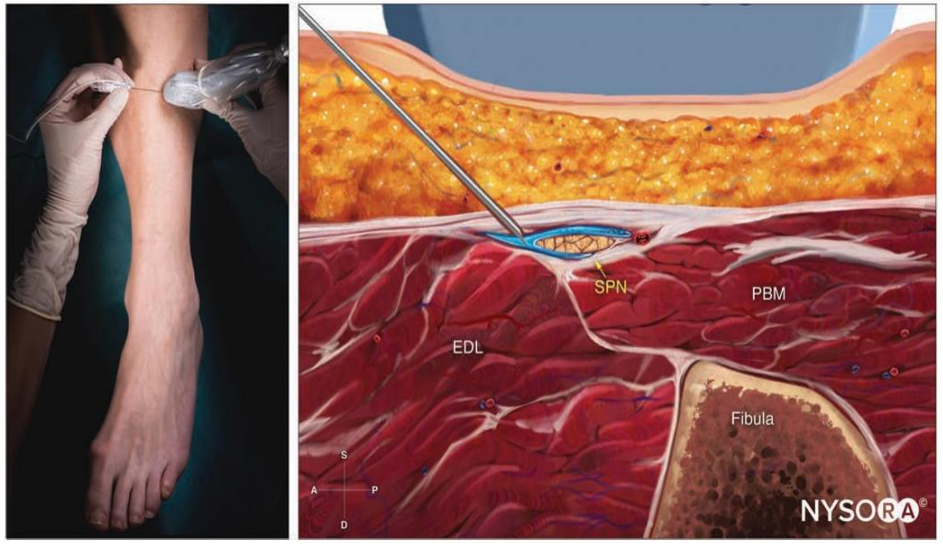

FIGURE 32-10. Reverse ultrasound anatomy of superficial peroneal nerve block with needle insertion in-plane. EDL, extensor digitorum longus; SPN, superficial peroneal nerve; PBM, peroneus brevis muscle.

Saphenous Nerve Block

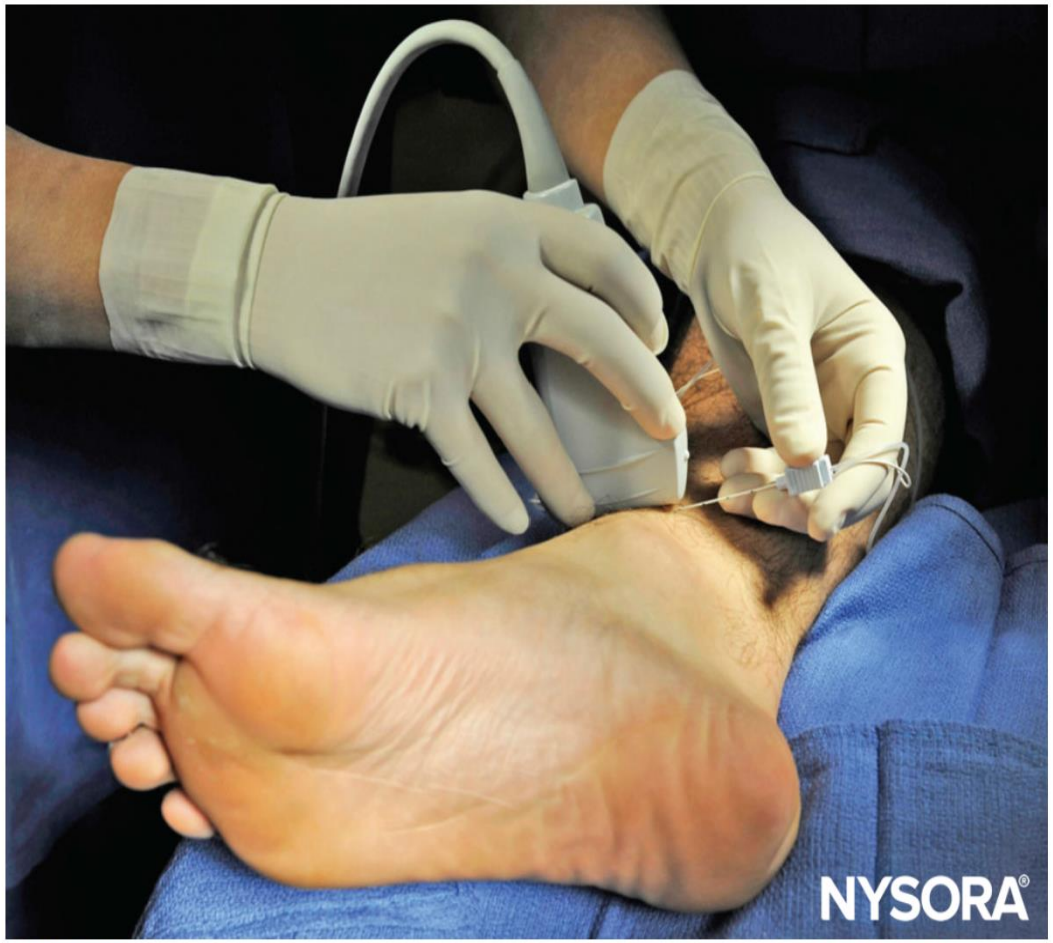

FIGURE 14. Transducer position and needle insertion to nerve block the saphenous nerve.

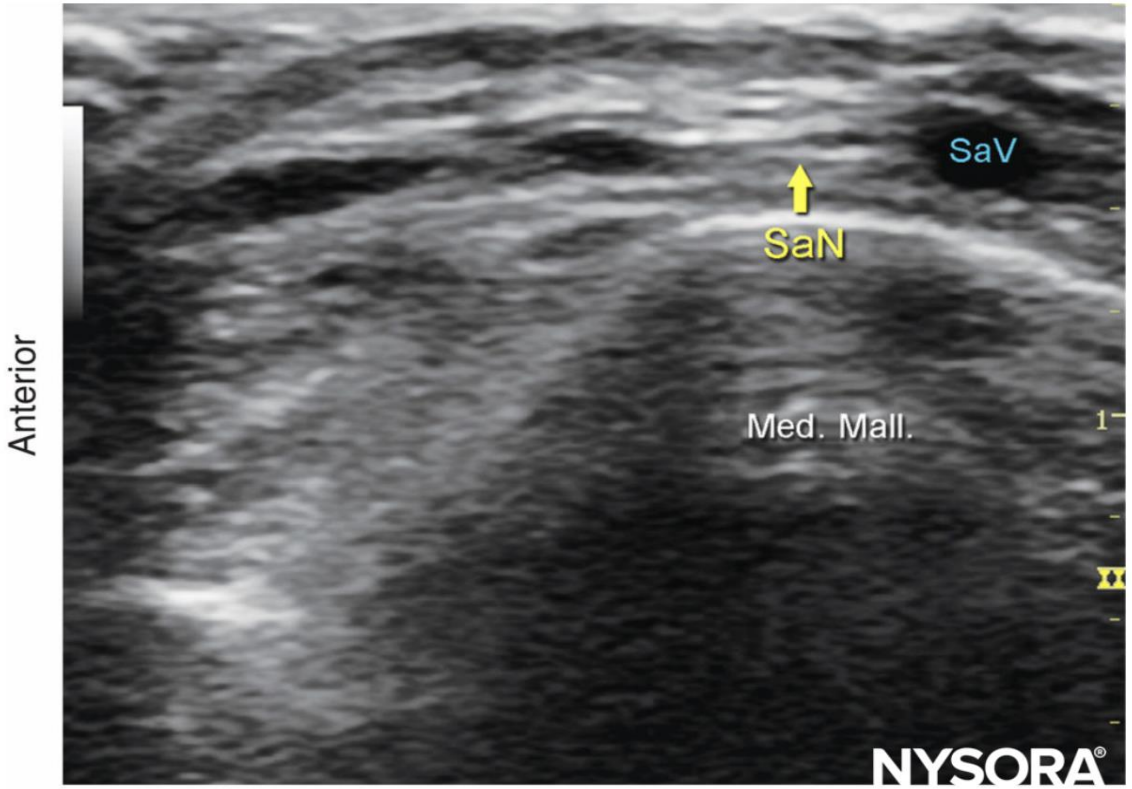

Ankle block-saphenous nerve

FIGURE 16. US anatomy of the saphenous nerve (SaN). Shown are the great saphenous vein (SaV) and the medial malleolus (Med. Mall.).

Sural Nerve Block

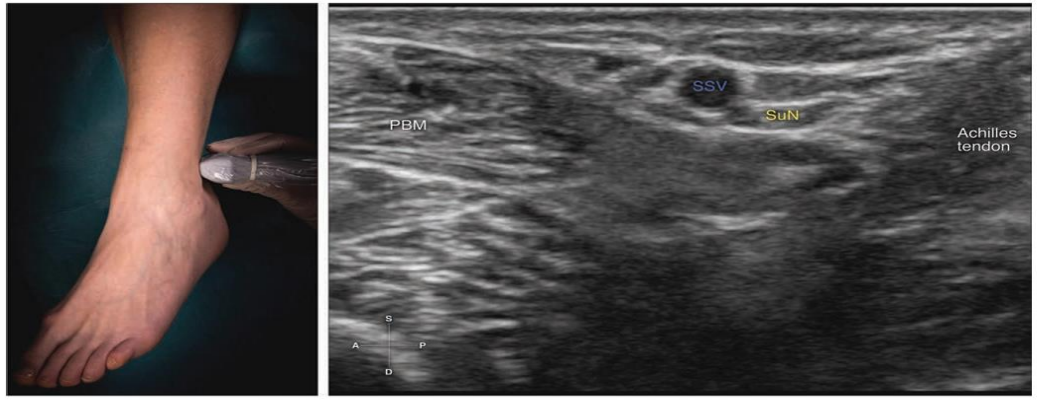

FIGURE 32-11. Transducer position and ultrasound anatomy to block the sural nerve. PBM, peroneus brevis muscle; SuN, sural nerve; SSV, small saphenous vein.

oval structure in close contact with the lesser saphenous vein (Figure 32-11 and 32-12).

Needle Approach

For each of the blocks, the needle can be inserted either in-plane or out-of-plane. Ergonomics often dictate which approach is the most effective (Figure 32-6, 32-8, 32-10, and 32-12).

Local Anesthetic Distribution

Ideally, the LA spreads immediately adjacent to the nerve; redirection to achieve circumferential spread is not necessary for the small nerves, as the LA diffuses quickly into the neural tissue. For the tibial nerve, the LA should be ideally injected within the neurovascular sheath to avoid delayed onset.

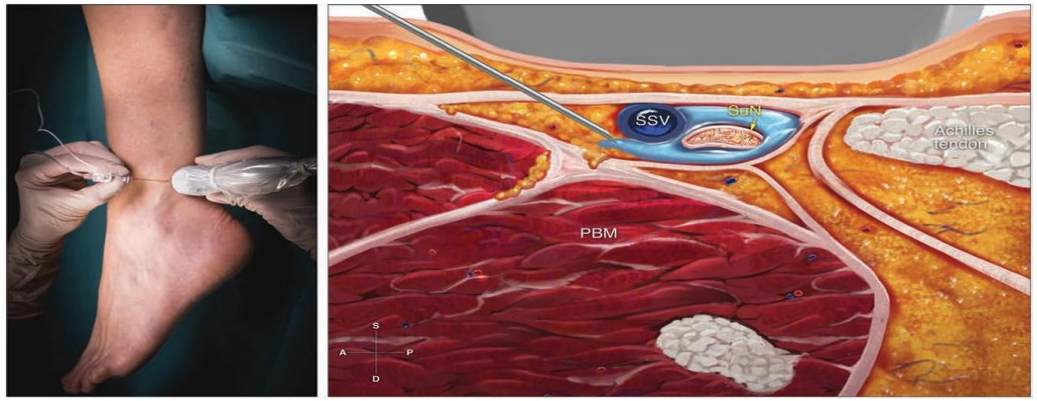

FIGURE 32-12. Reverse ultrasound anatomy of sural nerve block with needle insertion in-plane. PBM, peroneus brevis muscle; SuN, sural nerve; SSV, small saphenous vein.

Motor sparing analgesia is not an option

It’s a new standard in regional anesthesia
It’s pivotal evolution in ERAS


IRANIAN SOCIETY OF ANAESTHESIOLOGY AND CRITICAL CARE
Thank you for your attention
18–20 November 2026 · Tehran, Iran · From Innovation to Resilience