18th International Congress of Anesthesiology, Critical Care and Pain

SONOANATOMY: THE FIVE BREAD-and- BUTTER NERVE BLOCKS EVERY ANESTHESIOLOGISTS MUST KNOW

PROF. ALIREZA MIRKHESHTI

FELLOWSHIP OF REGIONAL ANESTHESIA

SHAHID BEHESHTI UNIVERSITY OF MEDICAL SCIENCES

18–20 November 2026 · Tehran, Iran · From Innovation to Resilience

Introduction

The **“Plan A”** regional anesthesia framework was proposed in **2019** by three prominent regional anaesthetists:

1.Dr. Lloyd R. Turbitt
2.Dr. Edward R. Mariano
3.Dr. Kariem El-Boghdadly

The authors introduced the “Plan A” concept to combat the overwhelming proliferation of novel ultrasound-guided regional anesthesia techniques. Instead of promoting **“many blocks for the few”** (where subspecialists perform highly niche blocks), the framework advocates for **“a few blocks for the many”**—establishing a core curriculum of versatile, low-risk, and high-efficacy blocks that generalist or non-expert anesthesiologists can readily master for everyday clinical practice.



Anaesthesia
Peri-operative medicine, critical care and pain

Association of Anaesthetists Great Britain & Ireland

Correspondence | Free Access

Future directions in regional anaesthesia: not just for the cognoscenti

T. W. Ashken ✉ M. H. W. Thompson

First published: 03 March 2020 | https://doi.org/10.1111/anae.14938 | VIEW METRICS

No competing interests declared.

SECTIONS PDF CITE TOOLS SHARE

We thank Turbitt et al. for their recent editorial on rationalising teaching of block diversity 1. As regional anaesthesia fellows at a large London teaching hospital, we are both regional anaesthesia learners and, increasingly, regional anaesthesia teachers. We applaud the approach and, whilst the exact choice of blocks will doubtless generate debate, we believe the overall strategy of selecting a small number of blocks, and driving competence among as many consultants and trainees as possible, is compelling.

However, the scale of the challenge should not be underestimated. We carried out a snapshot survey of anaesthetic consultants in seven acute Trusts covering 10 hospitals in London. Of 139 anaesthetic consultants at these Trusts, only 15 (10.8%) stated they could teach all seven of the plan A blocks under ultrasound guidance. Twenty-nine (20.9%) consultants felt they were not confident they could teach any of them and a further 12 (8.6%) felt they could teach only one of them. Only 24 (17.3%) consultants felt confident they could teach the erector spinae block (the newest of the blocks on the list). Training anaesthetic trainees and consultants in performing these blocks, in our region at least, is likely to be challenging on the basis of these results.

Our results are not meant to undermine the ‘plan A blocks’ approach, but they do reflect the size of the problem faced. We believe experts in the field, as well as relevant societies and associations, should consider strategies to drive wider competence and make regional anaesthetic and analgesic approaches available for more patients.

Rational and Core Concept

The Plan A blocks framework was proposed in 2019 with the aim of promoting a small number of versatile, high-value regional anesthetic techniques to build core competencies among all anesthetists.

- Plan A blocks concept is now cited globally as a framework for core competencies in regional anaesthesia.
- Many regional anesthesia educational courses worldwide now utilize the Plan A blocks moniker or concept, and the current Royal College of Anesthetists (RCoA) curriculum for regional anesthesia has integrated the Plan A blocks framework
- The ethos of ‘a few blocks for the many’ in place of ‘many blocks for the few´ was developed to assist the novice anesthetist in learning basic regional anesthesia skills for their daily practice and thus avoid becoming overwhelmed with the ever-increasing number of anatomically indistinct nerve block descriptions
- This framework also implies a broad definition of `novice´, which includes residents and anesthetists already in practice but who have not yet adopted regional anesthesia techniques

Evidence basis for plan A blocks

. The Plan A blocks were never intended for experienced regional anesthetists termed the “cognoscenti” in its original conceptualization.

. The concept was aimed solely at novice anesthetists as a mechanism to focus learning on a small group of high-value and versatile nerve blocks with the goal of creating a core foundation of regional anesthesia skills.

. The Plan A block educational approach does not mandate that other blocks cannot be learned or utilized; it is merely a suggested starting point.

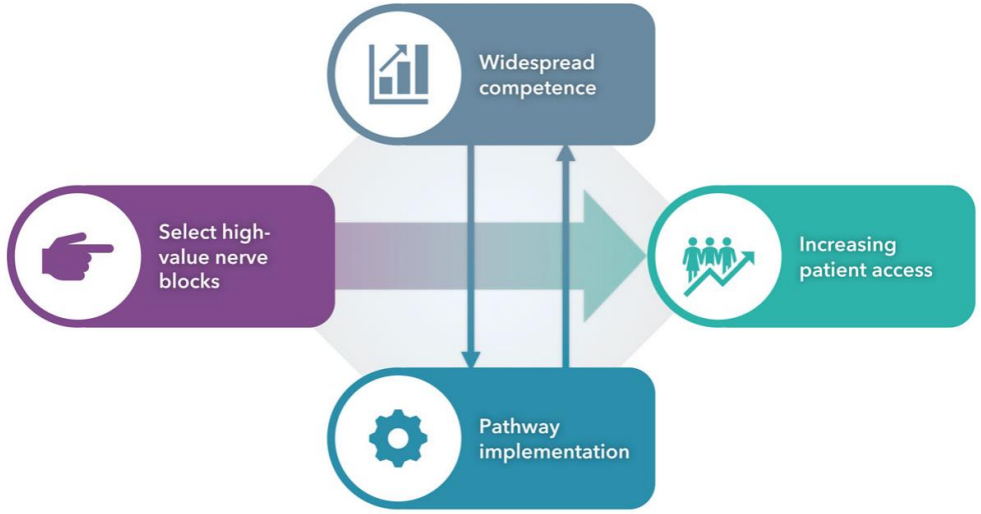

Beyond the Needle: Why Mastery of Sonoanatomy Is Essential for Every Anesthesiologist?

Current and potential future applications of US in anesthesiology are summarized as follows:

1. Neuraxial and regional anesthesia; chronic pain procedures
2. Vascular access
3. Airway assessment
4. Lung ultrasound
5. Gastric ultrasound;
6. Transesophageal echo (TEE) and Doppler

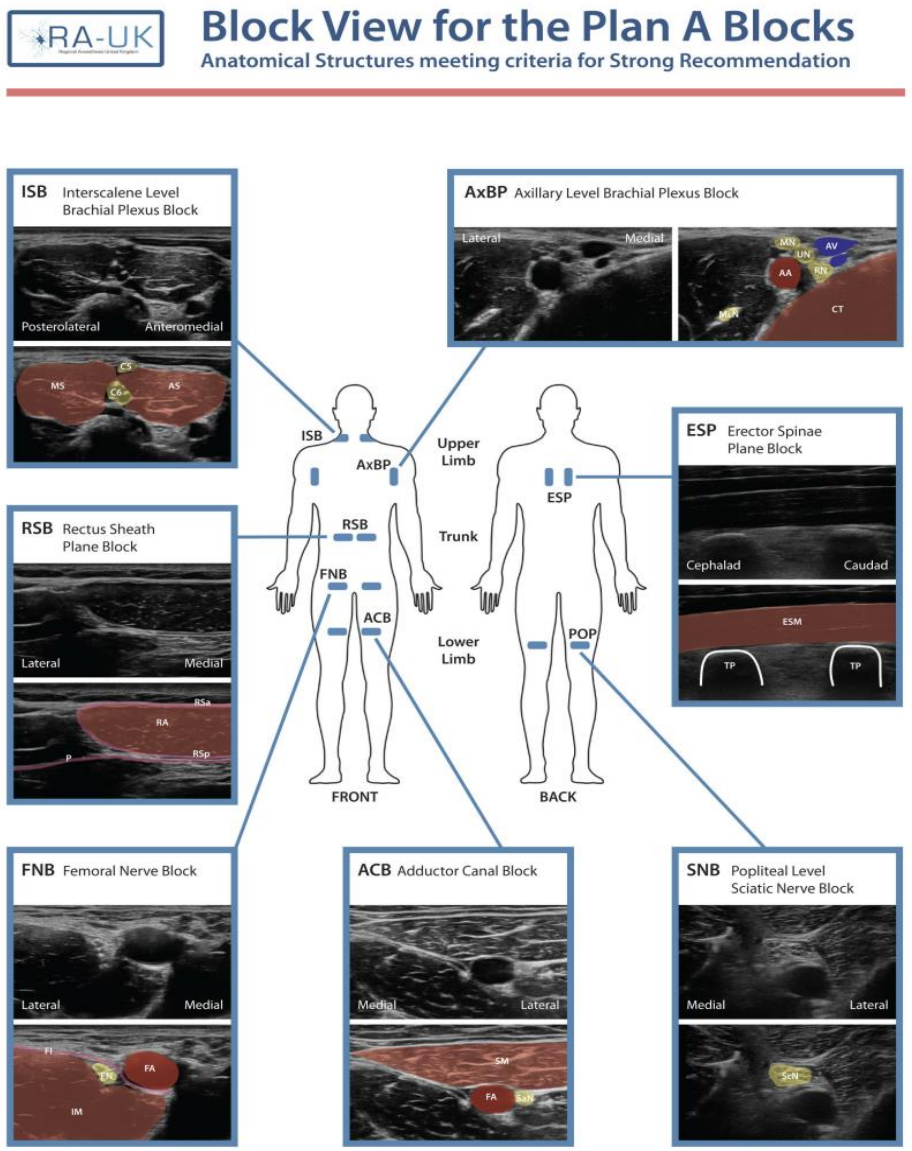

Why mastery of Sonoanatomy?

. For every anesthesiologist, whether performing regional blocks, vascular access, or point-of-care assessment, sonoanatomy serves as the essential bridge between textbook anatomy and the living human body.

. Without a solid grasp of sonoanatomy, the ultrasound machine becomes little more than an expensive guessing device—its full diagnostic and therapeutic potential remains untapped, and patient safety is placed at unnecessary risk.

. Sonoanatomy allows the anesthesiologist to convert a two-dimensional grey-scale image into a three-dimensional mental map of the patient's anatomy, thereby improving needle trajectory planning, reducing the number of attempts, and minimizing complications such as vascular puncture, nerve injury, or unintended intrathecal spread.

. In an era of increasingly image-guided practice, proficiency in sonoanatomy is no longer optional—it is a core competency that defines the modern anesthesiologist and directly contributes to improved patient outcomes.

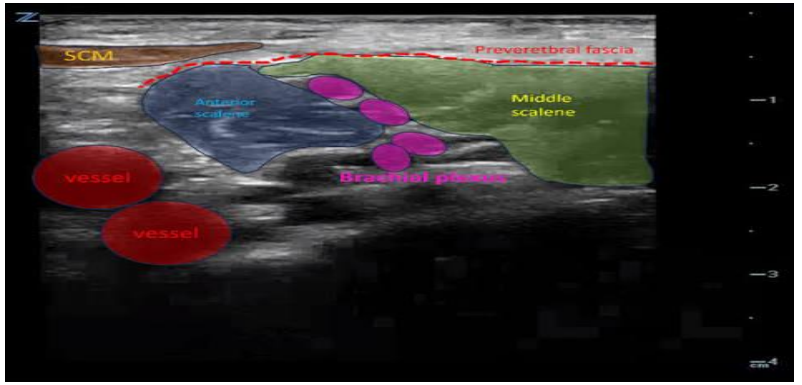

Dissemination and implementation

. The updated 2021 RCoA training curriculum in the UK has defined regional anesthesia as a core competency domain, and residents in the third and final stage of training should be able to perform and manage regional anesthetic techniques of the upper and lower limbs, chest wall and abdomen.

. A UK-wide survey study of anesthesia residents and RCoA College Tutors conducted from 2022 to 2023 revealed only 38% of stage 3 residents felt comfortable using regional anaesthesia alone for a patient undergoing hand surgery if they performed the block without Supervision.

. In another survey of UK consultants and specialists in 2023, 22% of respondents reported confidence in performing all seven Plan A blocks.

. These interviews identified important common barriers to learning regional anaesthesia by consultants: lack of confidence; fear of complications and failure;

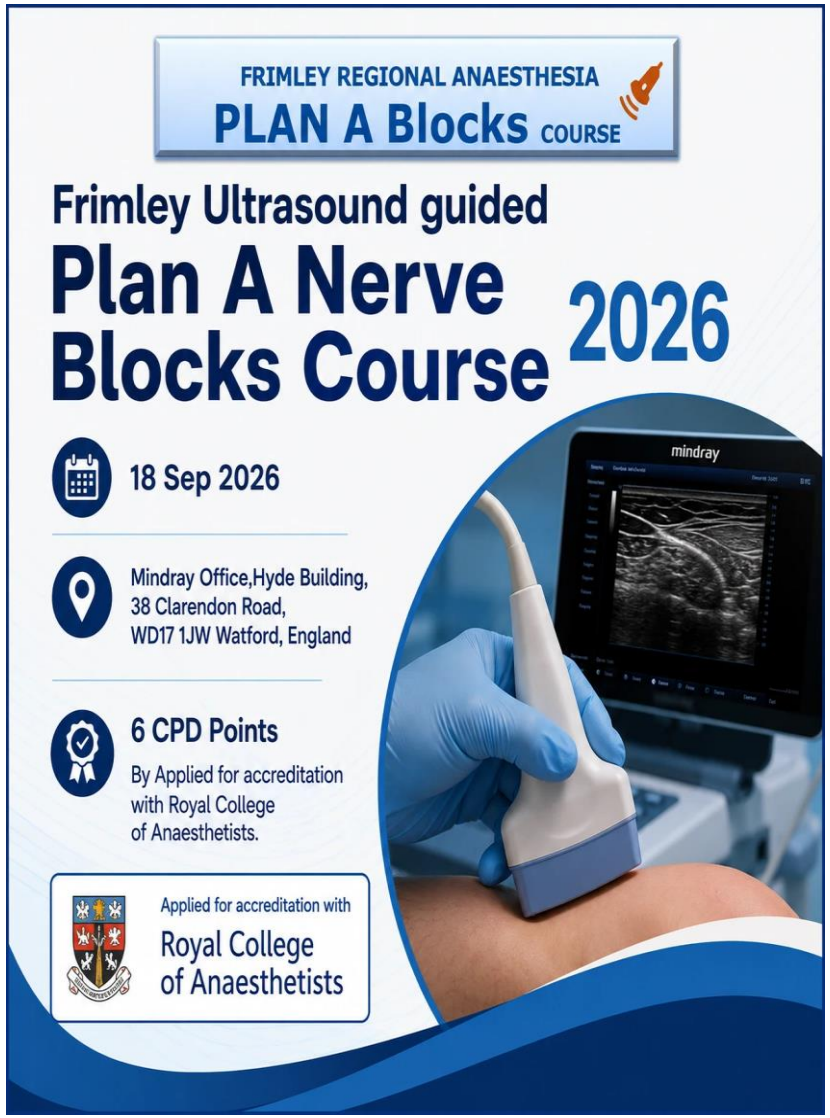

What are plan A blocks?

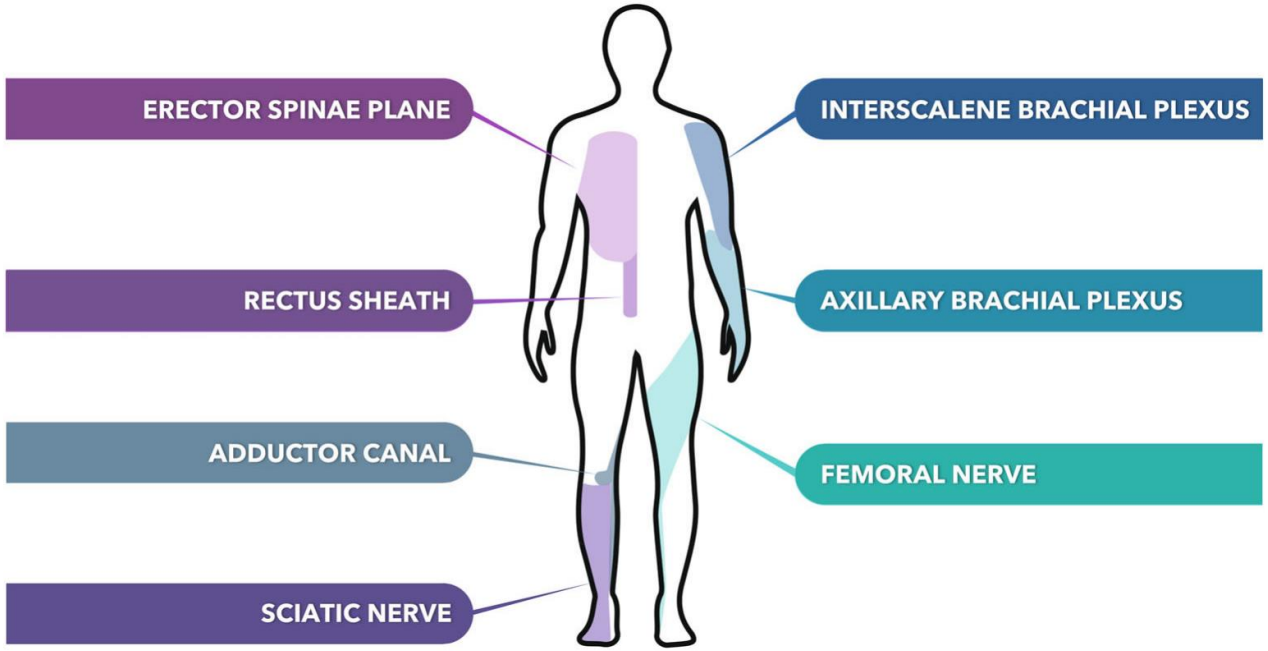

What are plan A blocks?

Anatomical region	Plan A block	Plan B/C/D blocks
Upper limb		
Shoulder	Interscalene brachial plexus block	Superior trunk block Combined axillary and suprascapular nerve block
Below shoulder	Axillary brachial plexus block	Infraclavicular or supraclavicular brachial plexus block
Lower limb		
Hip	Femoral nerve block	Fascia iliaca block Pericapsular nerve group block Lumbar plexus block
Knee	Adductor canal block	Femoral nerve block +/− IPACK block
Foot and ankle	Sciatic nerve block at the popliteal fossa	Ankle block Sciatic nerve block (proximal approaches)
Trunk		
Chest wall	Erector spinae plane block	Intertransverse process block Paravertebral block Serratus anterior plane block Interpectoral +/− pectoserratus plane blocks
Abdominal midline	Rectus sheath block	Transversus abdominis plane block (midaxillary or subcostal) Quadratus lumborum blocks External oblique intercostal block

INTERSCALENE BRACHIAL PLEXUS BLOCK

Indications: Shoulder procedures
Positioning: Supine, head turned to contralateral side
Depth: 1 – 4 cm
Needle: 22G, 25 – 50 mm
Volume: 10 ml for analgesia / 15 – 20 ml for anaesthesia

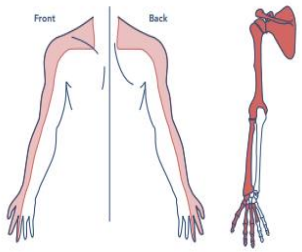

Abbreviations

MS = Middle Scalene Muscle
AS = Anterior Scalene Muscle
SCM = Sternocleidomastoid Muscle
VA = Vertebral Artery
IJV = Internal Jugular Vein
LA = Local Anaesthetic

PROBE POSITION

cephalad



ULTRASOUND IMAGE

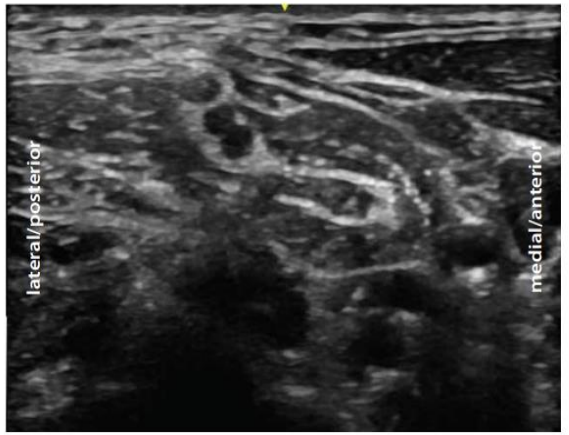

Probe position: Level of the cricoid cartilage over external jugular vein.
Needle approach: In-plane, posterior to anterior or out-of-plane.
Best view: C5, C6 and C7 between the AS and MS.
Technique: Needle insertion towards the C6 nerve root avoiding the dorsal scapular and long thoracic nerve with in the MS.

ULTRASOUND ANATOMY

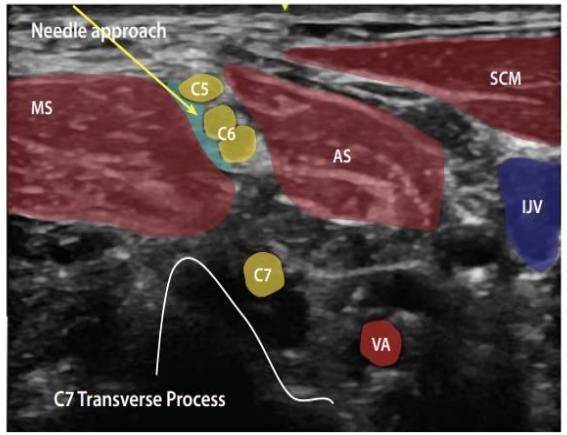

Spread of LA: Spread around C5 and C6 nerve roots.
Tips: Scan proximally from supraclavicular fossa. Use colour doppler to identify the vertebral artery. Avoid injecting near to C7 nerve root due to the risk of puncturing the nearby vertebral artery.

● = Local Anaesthetic Spread

AXILLARY BRACHIAL PLEXUS BLOCK

Indications: Procedures below shoulder
Positioning: Supine, arm abducted and / or elbow flexed
Depth: 1 – 4 cm
Needle: 22G, 50 – 100 mm
Volume: 15 – 25 ml

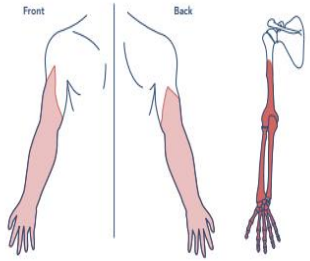

Abbreviations

AA = Axillary Artery
AV = Axillary Vein
MN = Median Nerve
UN = Ulnar Nerve
RN = Radial Nerve
MCN = Musculocutaneous Nerve

cephalad



caudad

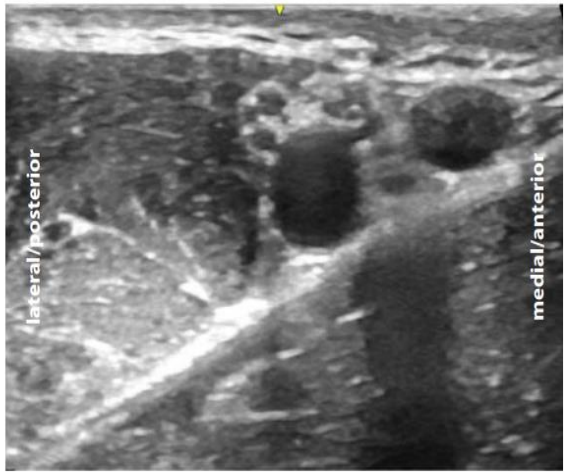

Probe position: Transversely across the axilla at junction of biceps and pectoralis muscles.
Needle approach: In-plane.
Best view: Axillary artery at the level of the conjoint tendon with the three nerves surrounding. MCN between biceps and coracobrachialis. Trace the nerves in the upper arm to confirm identity of the nerves.
Technique: Start with the radial nerve, deep to the artery. Then surround the median and ulnar nerves. May need a separate injection for MCN.

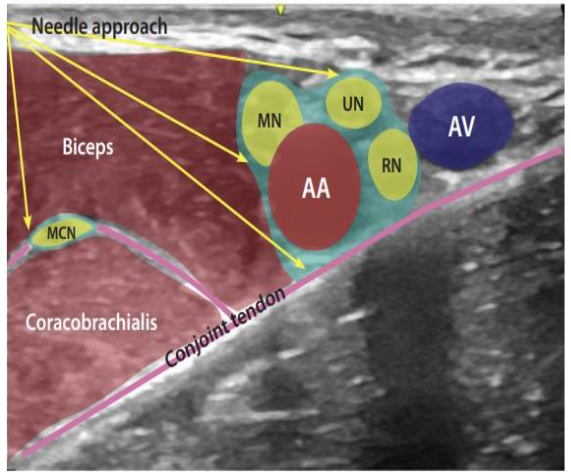

Spread of LA: Aim for 5 mls of LA around each nerve.
Tips: There is a large amount of anatomical variation. Always scan within the upper arm to locate the nerves. Use small amounts of LA to hydrodissect the nerves and vessels.

● = Local Anaesthetic Spread

FEMORAL NERVE BLOCK

Indications: Hip (or knee) procedures
Positioning: Supine, leg slightly abducted
Depth: 1 – 4cm
Needle: 22G 50 – 100 mm
Volume: 10 – 20 ml

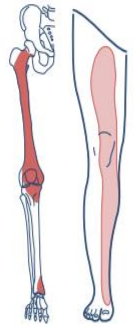

Abbreviations
FN = Femoral Nerve
FA = Femoral Artery
FV = Femoral Vein

PROBE POSITION

cephalad

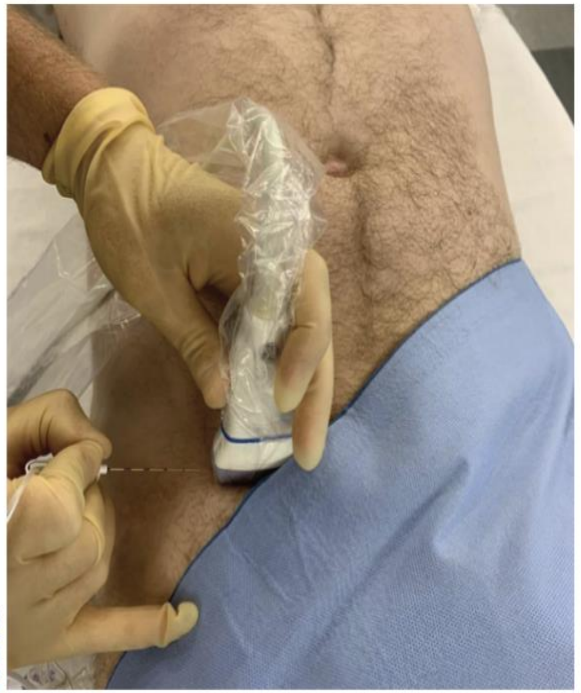

lateral

ULTRASOUND IMAGE

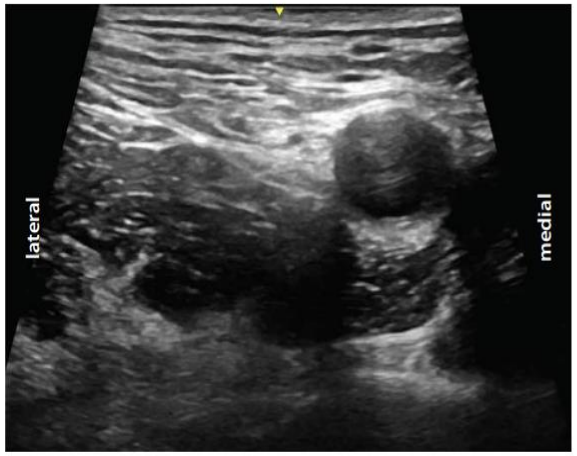

Probe position: Transverse across upper thigh, just below the inguinal ligament.
Needle approach: In-plane, lateral to medial.
Best view: Femoral artery and vein medially, femoral nerve just lateral to the artery underneath fascia iliaca.
Technique: Needle insertion lateral to the nerve below the fascia iliaca. Needle can be moved to ensure LA surrounding the nerve.

ULTRASOUND ANATOMY

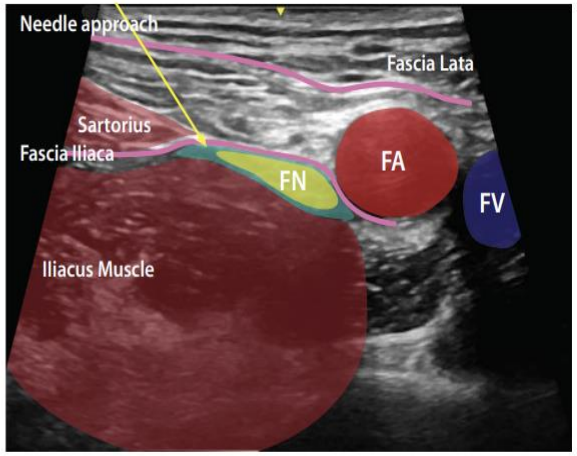

Spread of LA: Below the fascia iliaca, surrounding the nerve.
Tips: The femoral nerve can be difficult to visualise. Optimise the image using a caudal and cranial tilt of the probe. If the nerve is still difficult to visualise, perform a fascia iliaca block by depositing LA below the fascia iliaca.

● = Local Anaesthetic Spread

POPLITEAL SCIATIC BLOCK

Indications: Foot and ankle procedures
Positioning: Supine with hip and knee flexed / lateral / prone
Depth: 2 – 6cm
Needle: 22G 50 – 100 mm
Volume: 20 ml

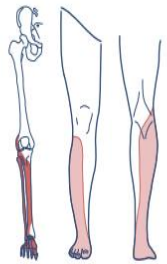

Abbreviations

CP = Common Peroneal Nerve
TN = Tibial Nerve
PV = Popliteal Vein
PA = Popliteal Artery
SMM = Semimembranosus Muscle
STM = Semitendinosus Muscle
····· = Circumneural Sheath



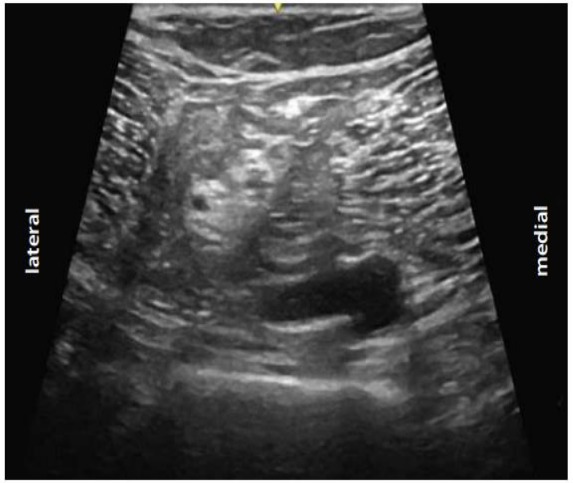

Probe position: Transverse approximately 5cm above the popliteal crease.
Needle approach: In-plane, lateral to medial or out-of-plane.
Best view: CP and TN just separate and contained within circumneural sheath.
Technique: Needle insertion parallel to the probe, aiming above and below the nerve.

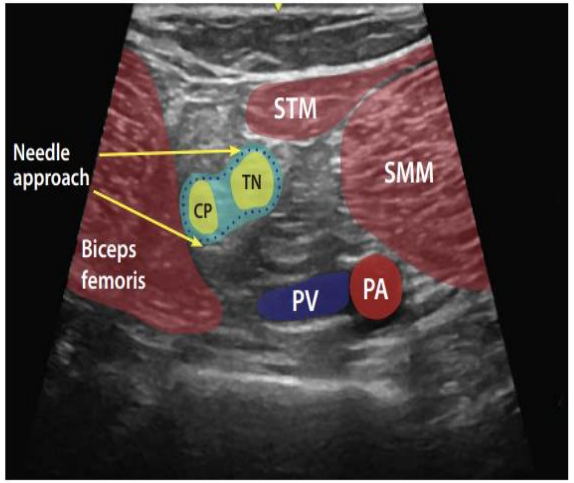

Spread of LA: Surrounding the two nerves and inside the circumneural sheath.
Tips: Use gentle pressure to avoid obliterating the popliteal vein. If the nerve is difficult to visualise, tilt the probe towards the knee. The "see-saw sign" can be used to identify the nerve. Aim to inject within the circumneural sheath but outside the epineurium.

● = Local Anaesthetic Spread

ADDUCTOR CANAL/FEMORAL TRIANGLE BLOCK

Indications: Knee procedures
Positioning: Supine, leg slightly abducted and externally rotated
Depth: 1 – 6 cm
Needle: 22G, 100 – 150 mm
Volume: 10 – 20 ml

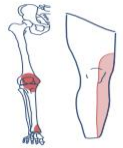

Abbreviations
SN = Saphenous Nerve
NVM = Nerve to Vastus Medialis
FA = Femoral Artery
FV = Femoral Vein

cephalad



lateral

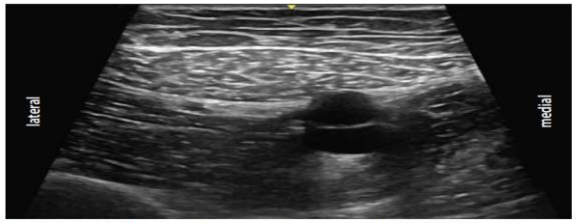

Probe position: Transverse position at mid-thigh level, medial aspect.
Needle approach: In-plane, lateral to medial.
Best View: Femoral artery below the sartorius muscle between vastus medialis and adductor longus. SN and NVM are seen just lateral to the artery.
Technique: Needle insertion towards the femoral artery, deep to sartorius.

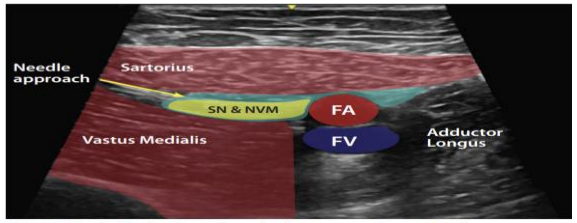

Spread of LA: In the plane below sartorius muscle.
Tips: Identify the femoral artery in the upper thigh and trace it distally to the mid-thigh. When this block is performed in the upper/middle thigh, the needle is usually located in the femoral triangle.

● = Local Anaesthetic Spread

ERECTOR SPINAE PLANE BLOCK

Indications: Chest wall procedures and rib fractures
Positioning: Sitting, lateral decubitus or prone
Depth: 4 – 10 cm
Needle: 22G 50 – 100 mm or 18G Tuohy
Volume: 20 – 30 ml, do not exceed max. dose of LA

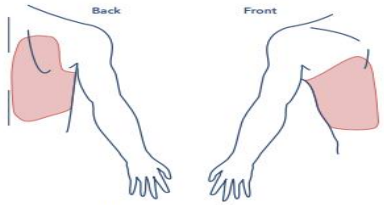

*This is the dermatomal spread we hope to cover

Abbreviations
TP = Transverse Process

cephalad



caudad

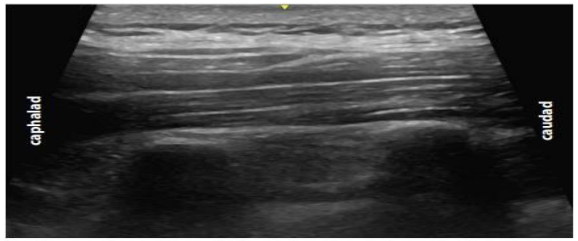

Probe position: Sagittal plane about 3 cm lateral to the midline.
Needle approach: In-plane, cephalad to caudad or caudad to cephalad.
Best view: Identify the transverse process in the middle of the intended dermatomal spread. Two transverse processes with the muscle layers in view.
Technique: Needle insertion towards the TP at the desired level. Inject below erector spinae muscle.

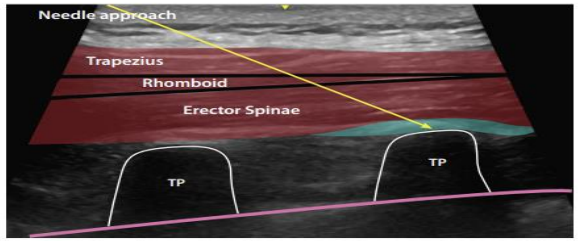

Spread of LA: Inject a small amount of LA to confirm needle in correct fascial plane. LA should spread below the erector spinae muscle, caudal to cranial.
Tips: Aim for the transverse process and use it as a back stop to avoid over inserting your needle. This is a fascial plane block which requires high volumes for spread. Be cautious to not exceed maximum dose of LA. Consider using dilute solution of LA.

● = Local Anaesthetic Spread

RECTUS SHEATH BLOCK

Indications: Midline abdominal procedures
Positioning: Supine
Depth: 3 – 6 cm
Needle: 22G 50 – 100 mm
Volume: 10 – 20 ml each side, do not exceed max. dose of LA

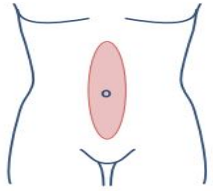

*This is the dermatomal spread we hope to cover

Abbreviations
PRS = Posterior Rectus Sheath
TF = Transversalis Fascia

cephalad



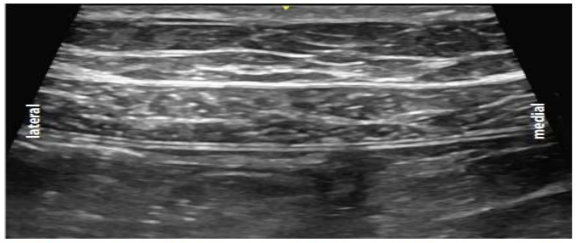

Probe position: Above the level of the umbilicus, lateral and in a transverse position
Needle approach: In-plane, lateral to medial
Best view: Identify linea alba in the midline and scan laterally to rectus. View the fascial plane deep to the rectus muscle.
Technique: Insert the needle through the rectus muscle aiming towards the fascial plane between the rectus muscle and PRS.

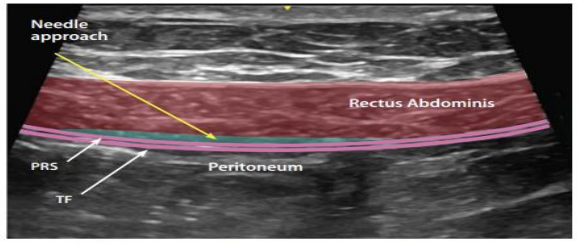

Spread of LA: LA spread between the rectus muscle and PRS. The muscle will peel away from the PRS.
Tips: Innervation of the midline is from both sides, therefore bilateral blocks are required for midline procedures. The epigastric vessels can lie deep to or in the rectus muscle, use colour doppler to help identify the vessels.

Current controversies with plan A blocks

. Despite progress in standardisation, the regional anaesthesia `cognoscenti´ cannot be deterred, and `novel´ blocks continue to be developed and published.

. Since its original description in 2016 , the understanding of the ESP block has continued to evolve. The differences in technique may be at least partially responsible for the perceived efficacy (or lack of efficacy) reported for the block.

. While the rectus sheath block is the recommended Plan A block for midline laparotomy, upper abdominal subcostal incisions may be amenable to subcostal TAP block.

. The choice of chest wall fascial plane block depends on the target site for analgesia, and many techniques exist to cover different areas

.The table of suggested Plan A blocks is intended for the general anesthetist, not the regional anesthesia expert,

Future directions for Plan A blocks

. The impact of Plan A blocks in changing clinical practice is difficult to quantify, but there has been a notable change in educational philosophy regarding regional anesthesia worldwide.

. Regional anesthesia community now has a responsibility to continue pushing the agenda of widespread competence and consistent pathway implementation of a select group of blocks for the benefit of patients globally.

Take-Home Messages

1

Message one

For every anesthesiologist, competence in “Plan A” nerve blocks is a core skill that directly improves perioperative care.

2

Message two

Sonoanatomy knowledge is the foundation of accurate, confident, and safe regional anesthesia practice.

3

Message three

The evolution of modern regional anesthesia offers a new frontier of techniques that continue to redefine standards of patient care

References

1. Lloyd R. Turbitt, Edward R. Mariano and Kariem El-Boghdadly. Plan A blocks in regional anaesthe sia: a narrative review. Anaesthesia 2026. https://doi.org/10.1111/anae.70182

2. T. W. Ashken, M. H. W. Thompson. Future directions in regional anaesthesia: not just for the cognoscenti. Anaesthesia 2020, 75, 550–559.

3. Gregory R. Dobson, Alex Beomju Bak, Anthony Chau and et al. Guidelines to the Practice of Anesthesia—Revised Edition 2026. Can J Anesth.https://doi.org/10.1007/s12630-026-03075-w

Thank You for Your Attention

A_Mirkheshti@sbmu.ac.ir