18th International Congress of Anesthesiology, Critical Care and Pain

Fascial Plane Blocks

Recent Advances and Future Perspectives

Dr. Ali Khatibi
assistant professor of anesthesiology fellowship of regional anesthesia
Firoozgar hospital ,Tehran, iran
Iran university of medical sciences

18–20 November 2026 · Tehran, Iran · From Innovation to Resilience

About the Speaker



- Assistant professor of anesthesiology
- fellowship of regional anesthesia
- Iran University of medical sciences
- Firoozgar Hospital

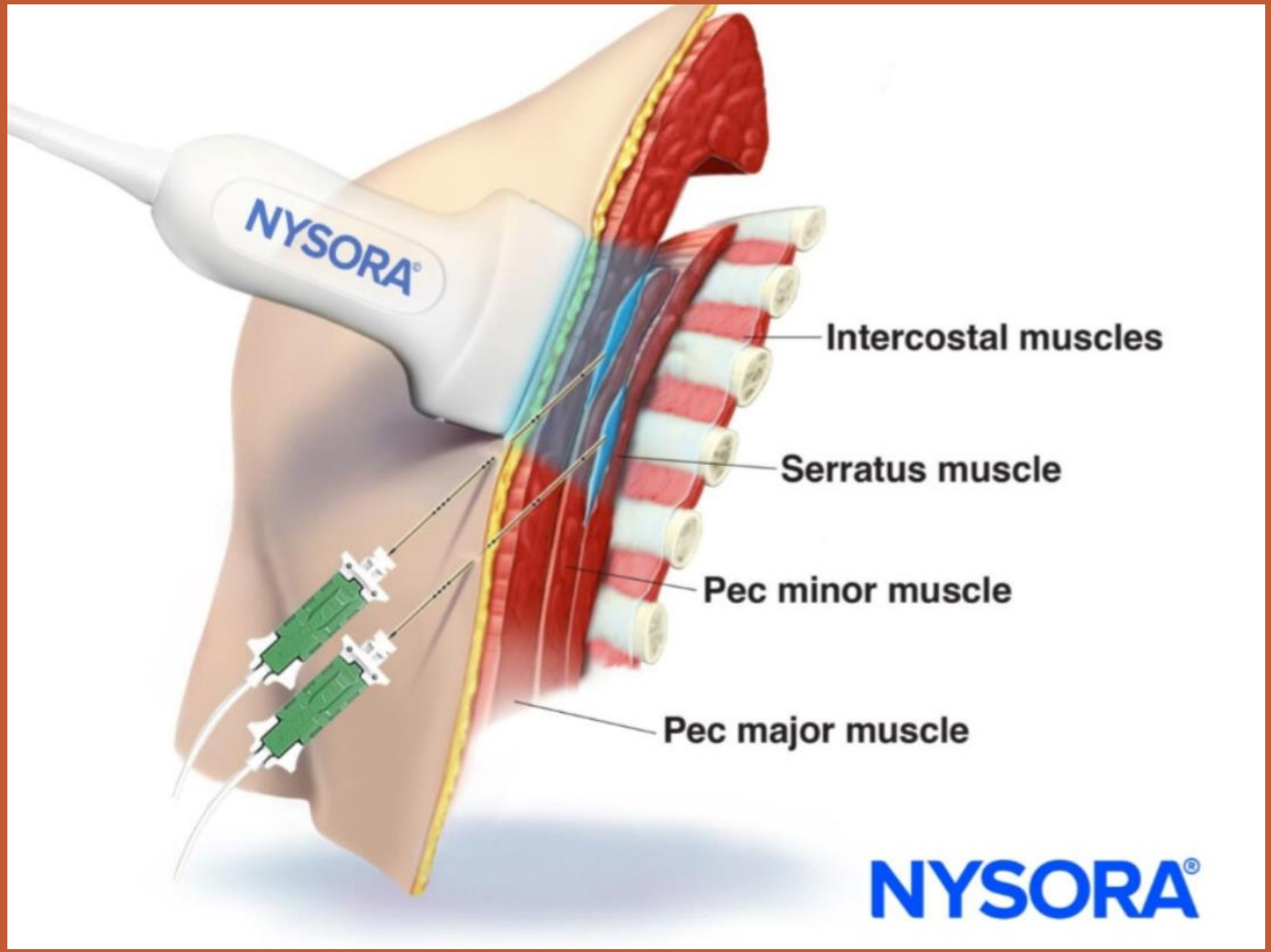
NYSORA
Intercostal muscles
Serratus muscle
Pec minor muscle
Pec major muscle
NYSORA

FASCIAL PLANE BLOCKS
COMPARISON

ANESTHESIA MADE EASY

Know the plane, Numb the pain!

"One needle. Different fascial planes. Completely different analgesia."

PECS BLOCK (PECS I & II)

LOCATION
Chest wall



MECHANISM
Local anesthetic deposited between pectoral muscles
(PECS I – between PM & PMm)
(PECS II – between PMm & Serratus Anterior)

SURGERIES
- Breast surgery
- Mastectomy
- Implant insertion
- Port placement

KEY POINT
Excellent analgesia for anterior chest wall & breast.

ESPB (Erector Spinae Plane Block)

LOCATION
Paraspinal region



MECHANISM
LA deposited deep to erector spinae muscle, spreads cranio-caudally & anteriorly to affect dorsal & ventral rami.

SURGERIES
- Thoracic
- Abdominal
- Spine
- Lower limb

KEY POINT
Most versatile block – wide spread of analgesia.

QLB (Quadratus Lumborum Block)

LOCATION
Posterior abdominal wall



MECHANISM
LA deposited around Quadratus Lumborum muscle (QL1 – anterolateral border / QL2 – posterior border / QL3 – transmuscular) → spread to thoracic paravertebral space.

SURGERIES
- Cesarean section
- Abdominal surgery
- Lower abdominal surgeries

KEY POINT
Provides both somatic & visceral analgesia.

SAPB (Serratus Anterior Plane Block)

LOCATION
Lateral chest wall



MECHANISM
LA deposited superficial or deep to Serratus Anterior muscle → blocks lateral cutaneous branches of intercostal nerves (T2 – T9).

SURGERIES
- Rib fractures
- Thoracotomy
- VATS
- Chest tube insertion

KEY POINT
Excellent for lateral chest wall analgesia.

PENG (Pericapsular Nerve Group Block)

LOCATION
Anterior hip region

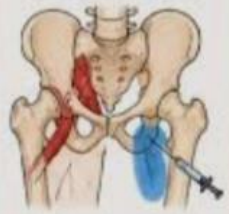

MECHANISM
LA deposited between AIIS & iliopubic eminence → blocks articular branches of femoral, obturator & accessory obturator nerves.

SURGERIES
- Hip fracture
- Total hip replacement
- Hip arthroscopy

KEY POINT
Motor-sparing block with excellent analgesia for hip.

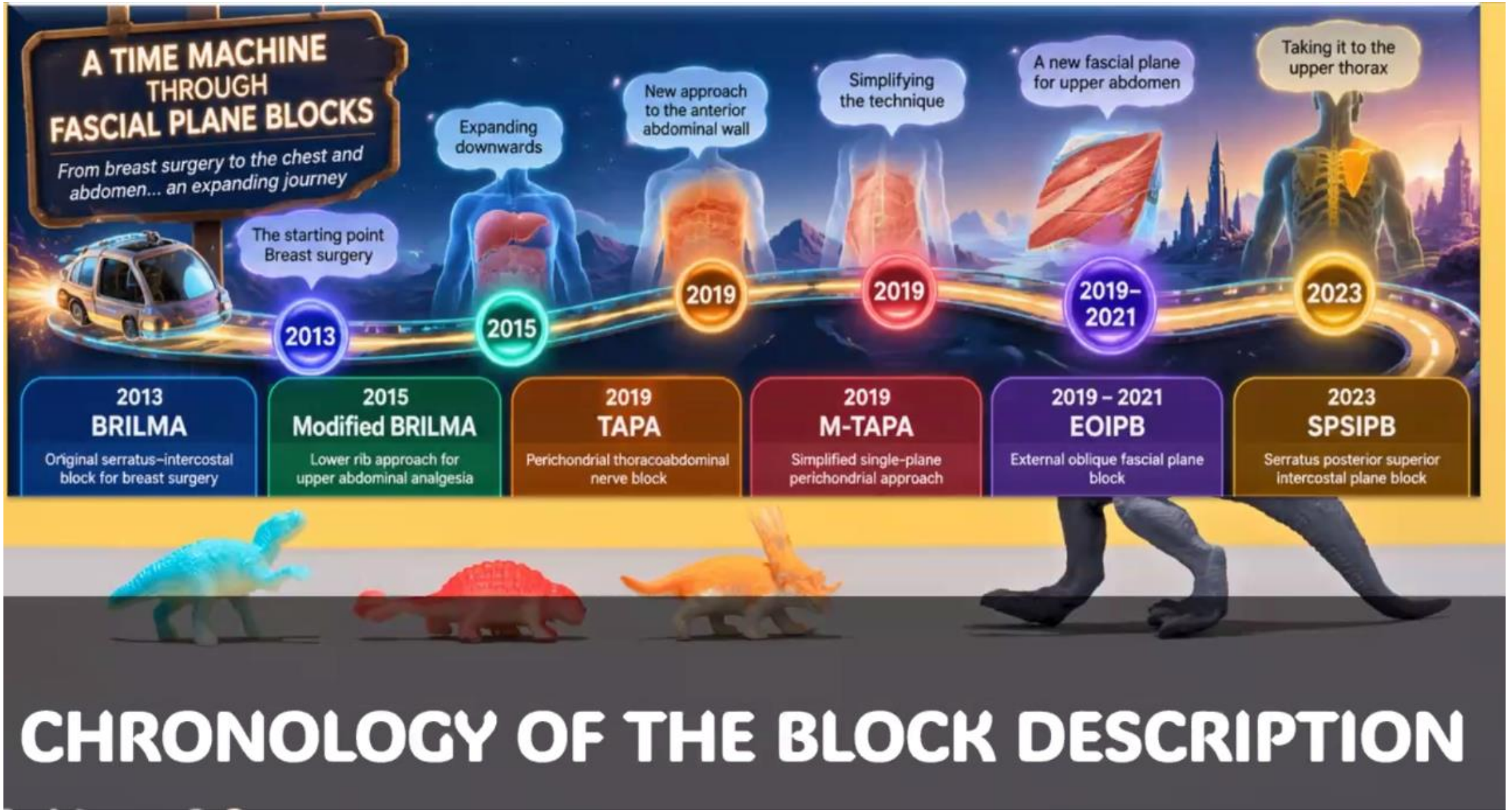
A TIME MACHINE THROUGH FASCIAL PLANE BLOCKS
From breast surgery to the chest and abdomen... an expanding journey
The starting point Breast surgery
Expanding downwards
New approach to the anterior abdominal wall
Simplifying the technique
A new fascial plane for upper abdomen
Taking it to the upper thorax
2013
2015
2019
2019
2019–2021
2023
2013 BRILMA
Original serratus–intercostal block for breast surgery
2015 Modified BRILMA
Lower rib approach for upper abdominal analgesia
2019 TAPA
Perichondrial thoracoabdominal nerve block
2019 M-TAPA
Simplified single-plane perichondrial approach
2019 – 2021 EOIPB
External oblique fascial plane block
2023 SPSIPB
Serratus posterior superior intercostal plane block
CHRONOLOGY OF THE BLOCK DESCRIPTION

BLOCKS OF THORAX

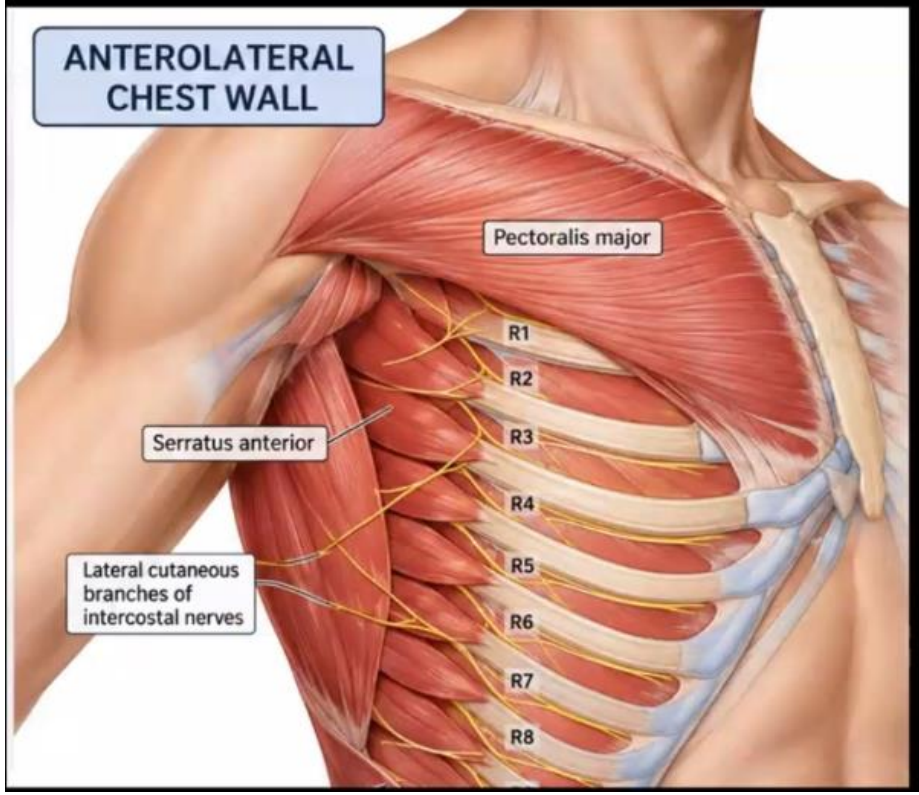

BRILMA

SERRATUS POSTERIOR SUPERIOR IPB

BLOCKS OF ABDOMEN

- M-BRILMA (SIPB)
- TAPA
- M-TAPA
- EOIPB

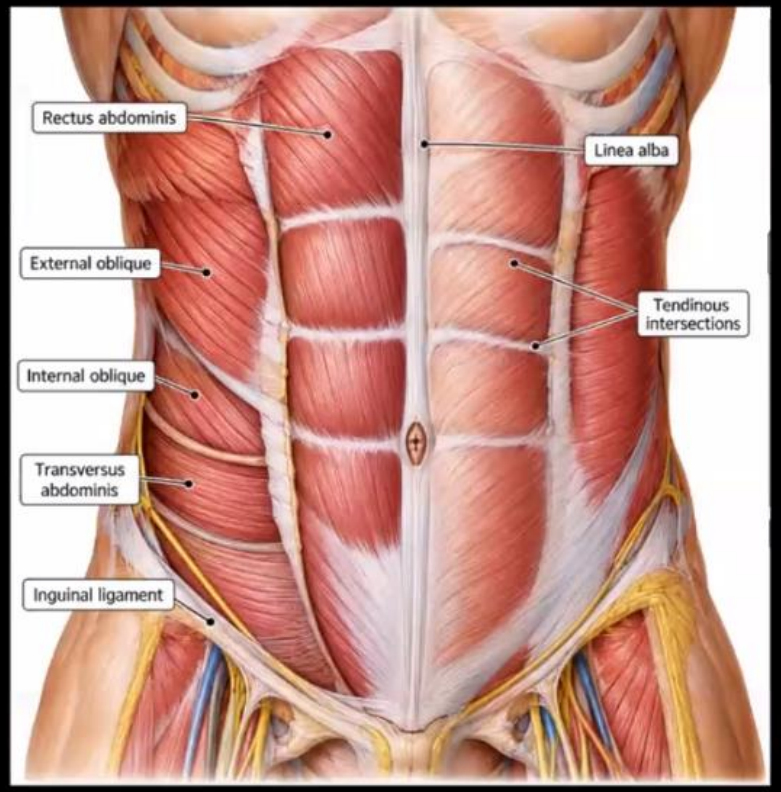

INTERCOSTAL NERVE

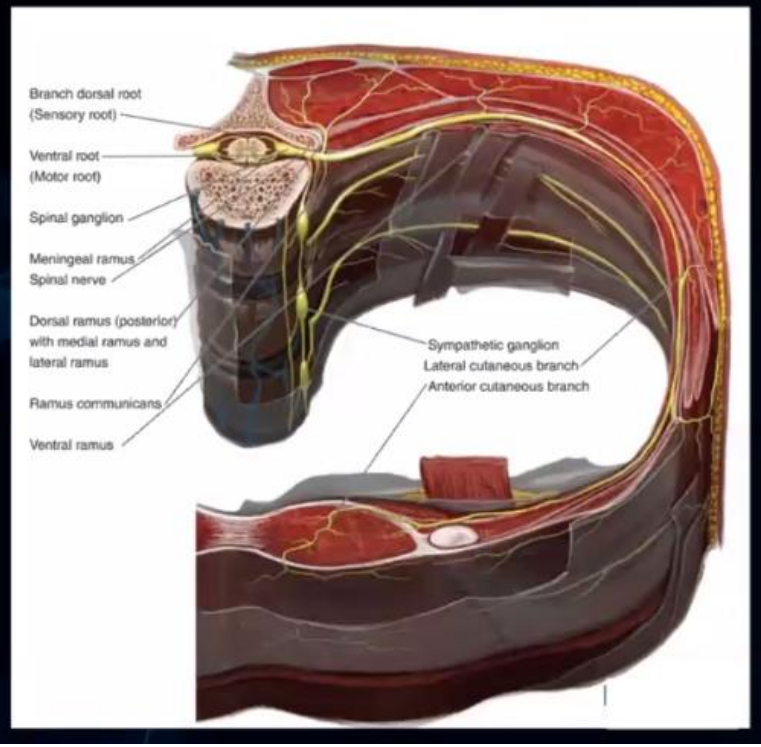

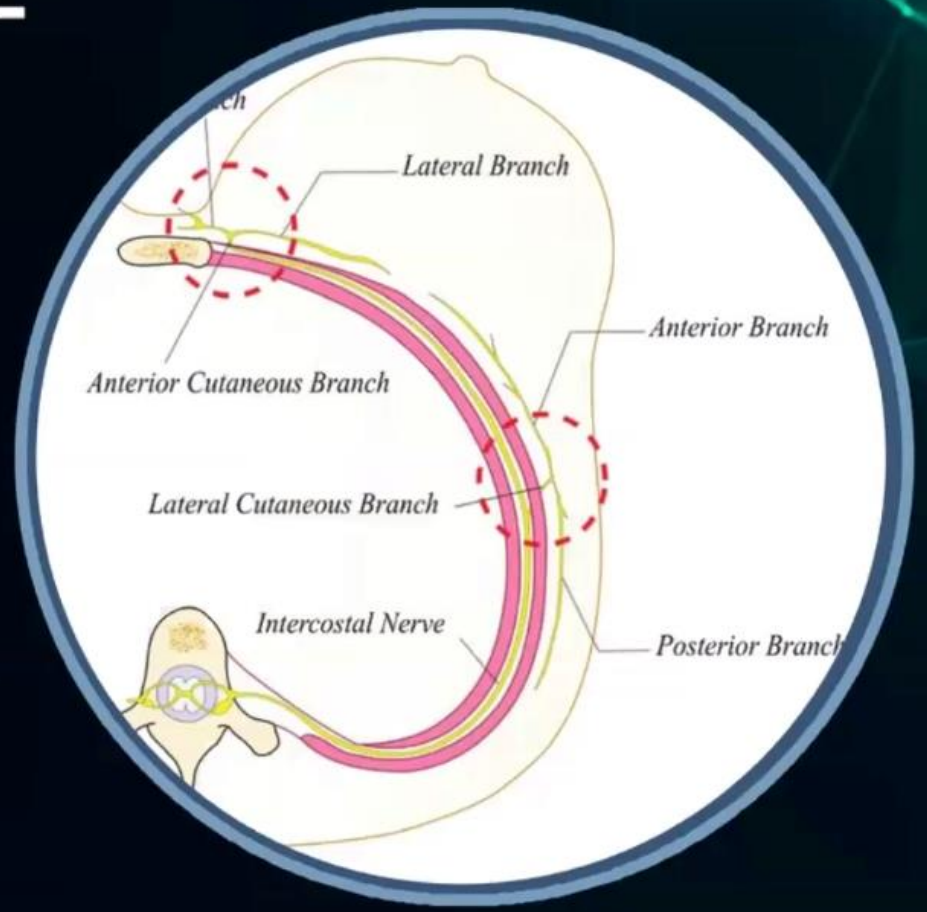

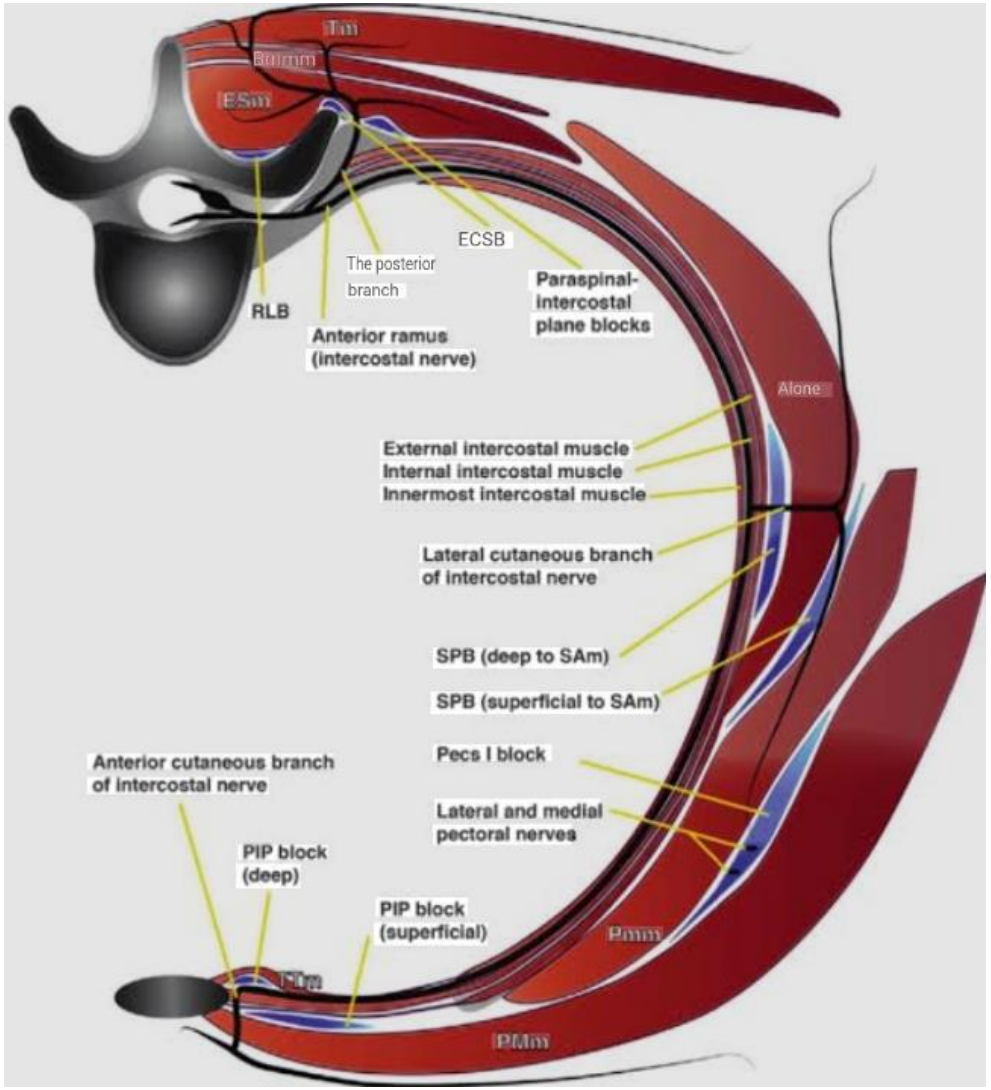
Tm
ESm
ECSB
The posterior branch
RLB
Anterior ramus (intercostal nerve)
Paraspinal-intercostal plane blocks
Alone
External intercostal muscle
Internal intercostal muscle
Innermost intercostal muscle
Lateral cutaneous branch of intercostal nerve
SPB (deep to SAm)
SPB (superficial to SAm)
Pecs I block
Anterior cutaneous branch of intercostal nerve
Lateral and medial pectoral nerves
PIP block (deep)
PIP block (superficial)
Pmm
PMm

1. BRILMA BLOCK

Blocking the Branches of the Intercostal Nerves in the Middle Axillary Line.



Rev Esp Anestesiol Reanim. 2013;60(7):365–370

Revista Española de Anestesiología y Reanimación

www.elsevier.es/redar

ORIGINAL

Abordaje guiado por ultrasonidos de los nervios intercostales en la línea media axilar para cirugía de mama no reconstructiva y de la axila

P. Diéguez Garcia[a,*], M. Fajardo Pérez[b], S. López Álvarez[a], P. Alfaro de la Torre[b] y A.P. Pensado Castiñeiras[c]

ERGONOMICS

- Supine position with arm abducted at 90 degree
- Linear high frequency probe
- Probe placement in mid axillary line
- Needle direction: Caudal to cranial



INTRODUCTION

Plane between the serratus anterior and external intercostal muscles.

Approximately the fourth rib in the midaxillary region.

Cutaneous branches of the intercostal nerves supplying the lateral thoracic wall.

Breast surgery and anterolateral chest wall analgesia.

SERRATUS ANTERIOR MUSCLE

ORIGIN

External surfaces of the upper 8 –9 ribs

INSERTION

It inserts along the anterior (cost al) surface of the medial border of the scapula

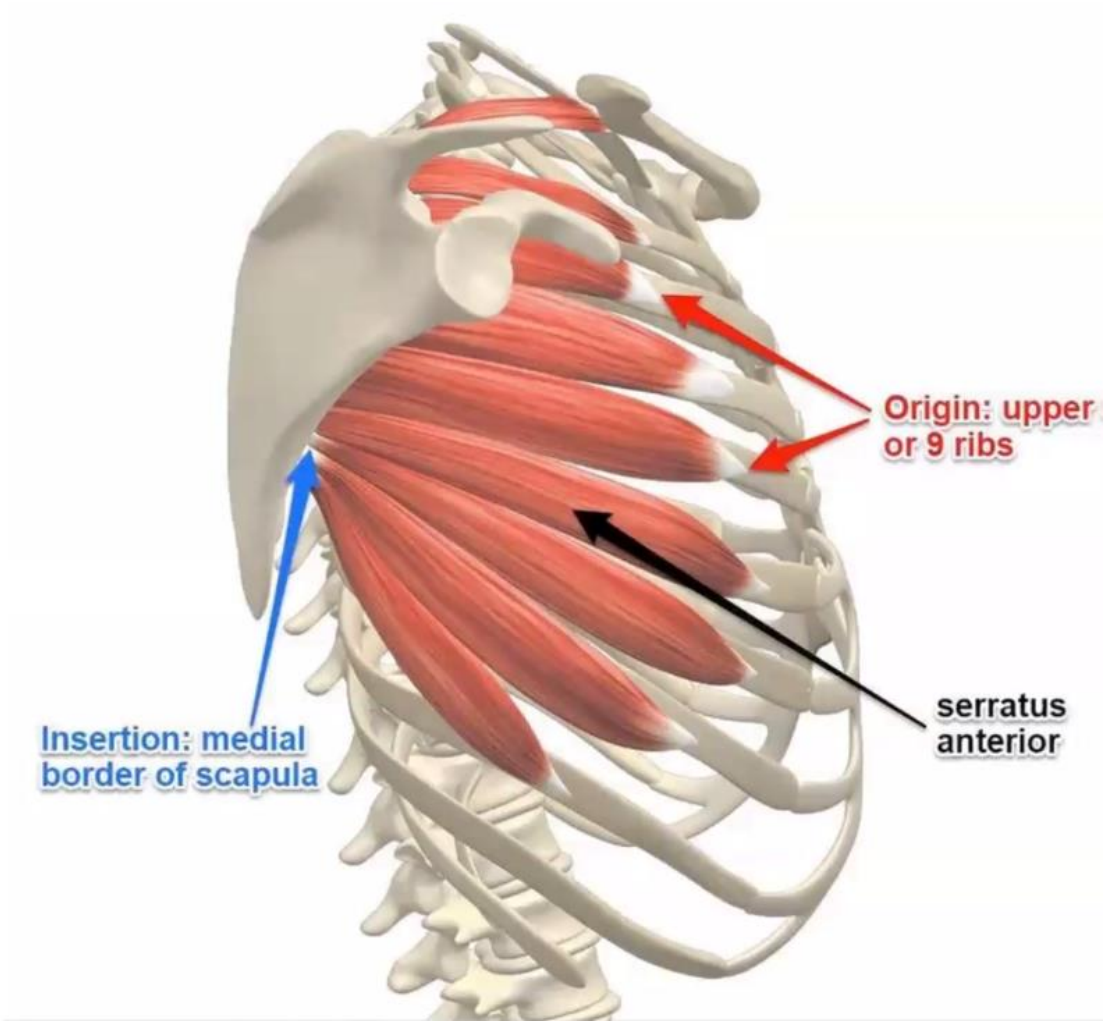

SONOANATOMY

- ✓ SAM: Serratus anterior muscle
- ✓ ICM: Intercostal muscles



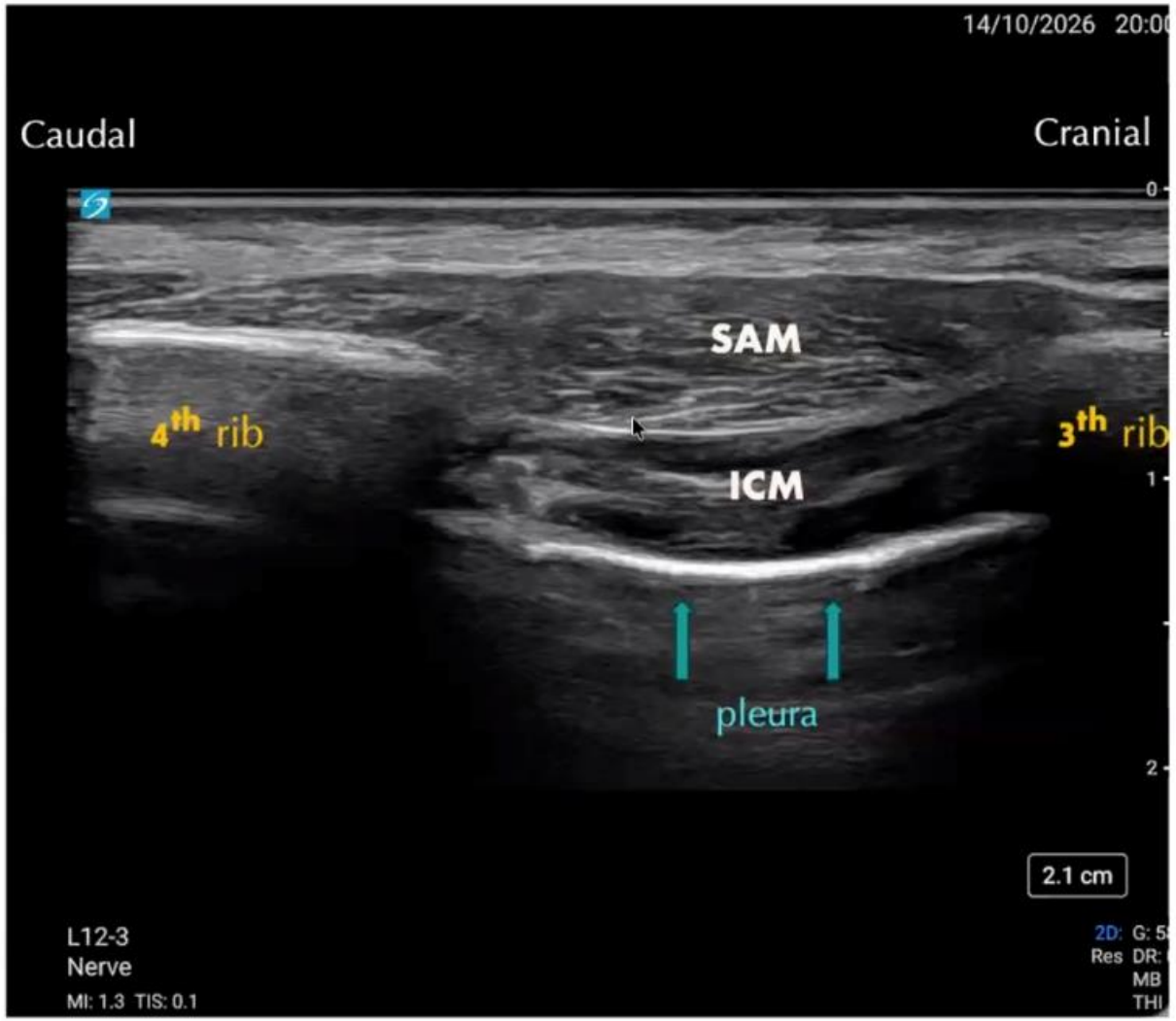

DEPOSITION OF LOCAL ANAESTHETIC

BETWEEN SAM AND ICS

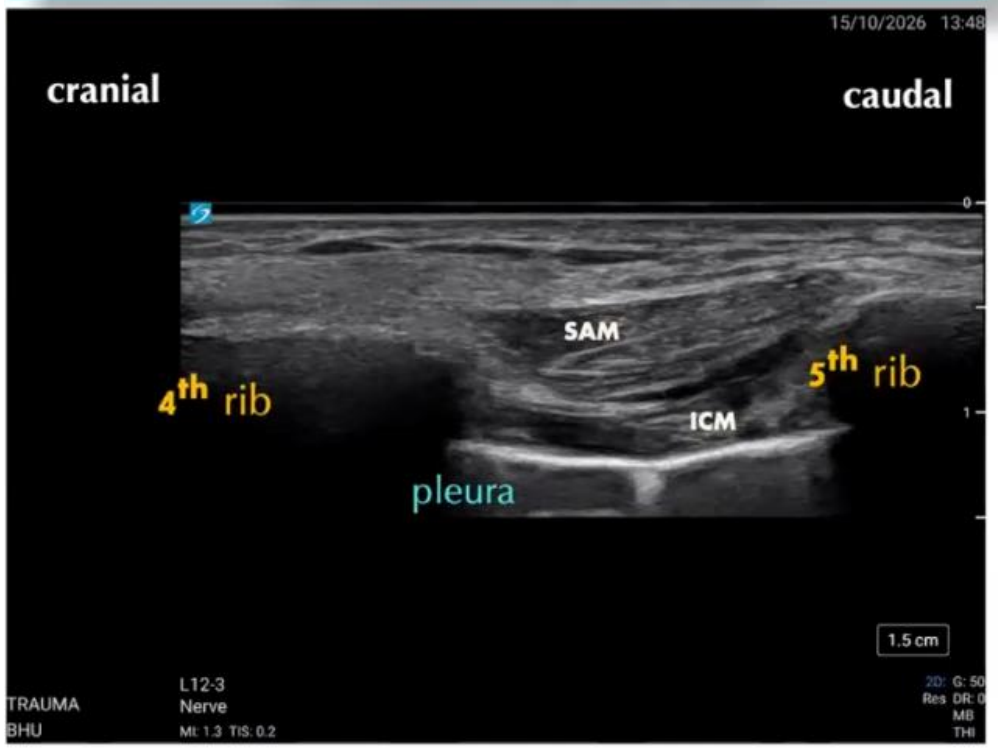

In plane needle, caudal to cranial, 20 ml of 0.2% ropivacaine

BETWEEN SAM AND 4th rib

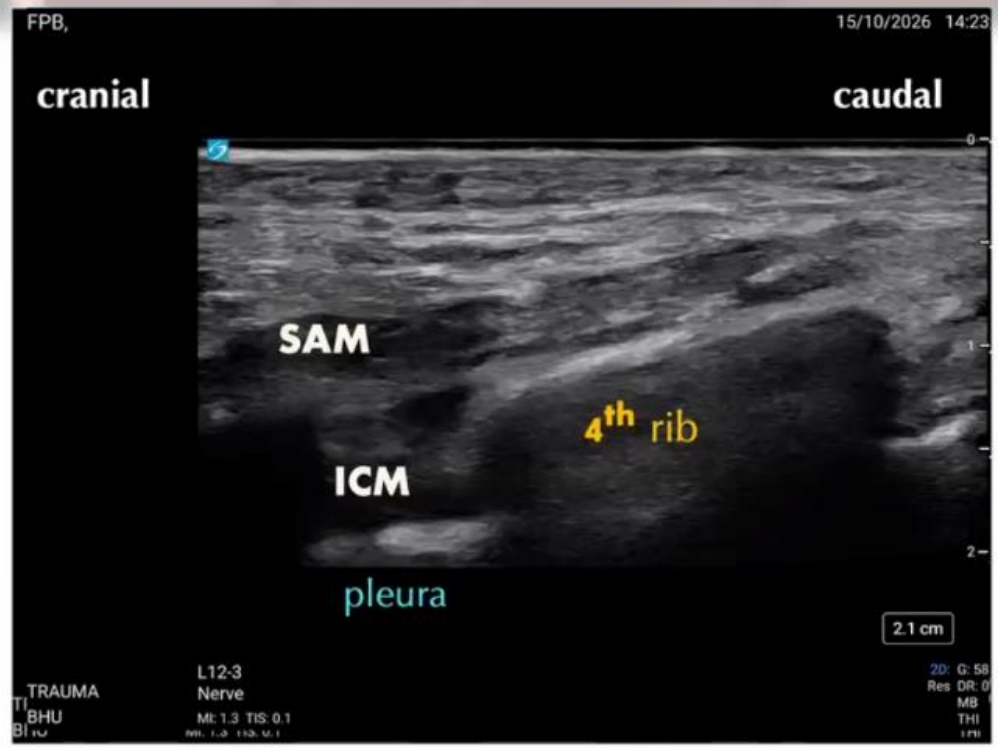

In plane needle, caudal to cranial, 20 ml of 0.2% ropivacaine

2. SPSIP BLOCK

Serratus posterior superior intercostal plane block



Cureus

Open Access Original Article

DOI: 10.7759/cureus.34582

Serratus Posterior Superior Intercostal Plane Block: A Technical Report on the Description of a Novel Periparavertebral Block for Thoracic Pain

Serkan Tulgar [1], Bahadır Ciftci [2], Ali Ahiskalioglu [3,4], Bora Bilal [5], Bayram U. Sakul [6], Ali O. Korkmaz [6], Nureda N. Bozkurt [6], Alessandro De Cassai [7], Augusto J. Torres [8], Hesham Elsharkawy [9], Haci A. Alici [10]

1. Anesthesiology, Samsun University, Samsun, TUR 2. Anesthesiology and Reanimation, Istanbul Medipol University, Istanbul, TUR 3. Clinical Research, Development, and Design Application and Research Center, Ataturk University School of Medicine, Erzurum, TUR 4. Anesthesiology and Reanimation, Ataturk University School of Medicine, Erzurum, TUR 5. Anesthesiology and Reanimation, Kahramanmaras Sutcu Imam University, Kahramanmaras, TUR 6. Anatomy, Istanbul Medipol University, Istanbul, TUR 7. Anesthesiology, University of Padova, Padova, ITA 8. Anesthesiology and Reanimation, Pain and Healing Center MetroHealth, Cleveland, USA 9. Anesthesiology, Cleveland Clinic, Cleveland, USA 10. Algology, Medipol University Faculty of Medicine, Istanbul, TUR

Review began 01/26/2023
Review ended 01/31/2023
Published 02/03/2023

© Copyright 2023
Tulgar et al. This is an open access article distributed under the terms of the Creative Commons Attribution License CC-BY 4.0., which permits unrestricted use, distribution, and reproduction in any medium, provided the original author and source are credited.

ERGONOMICS

- Prone/Sitting/Lateral position
- Linear high frequency probe
- Target rib: 3rd rib
- Probe placement: with oblique visualization is obtained (inferomedial-superolateral) with the upper medial border of the scapula
- Needle direction: Caudal to cranial



INTRODUCTION



- Plane between the serratus posterior superior muscle and the intercostal muscles.
- Upper posterior thorax, near the medial scapular region.
- Intercostal nerve branches and posterior thoracic neural structures through fascial spread.
- Upper hemithorax, shoulder, posterior neck and scapular region, although coverage is variable. (C7-T7)
- Thoracic surgery, upper thoracic wall pain and selected breast procedures.

ANATOMY

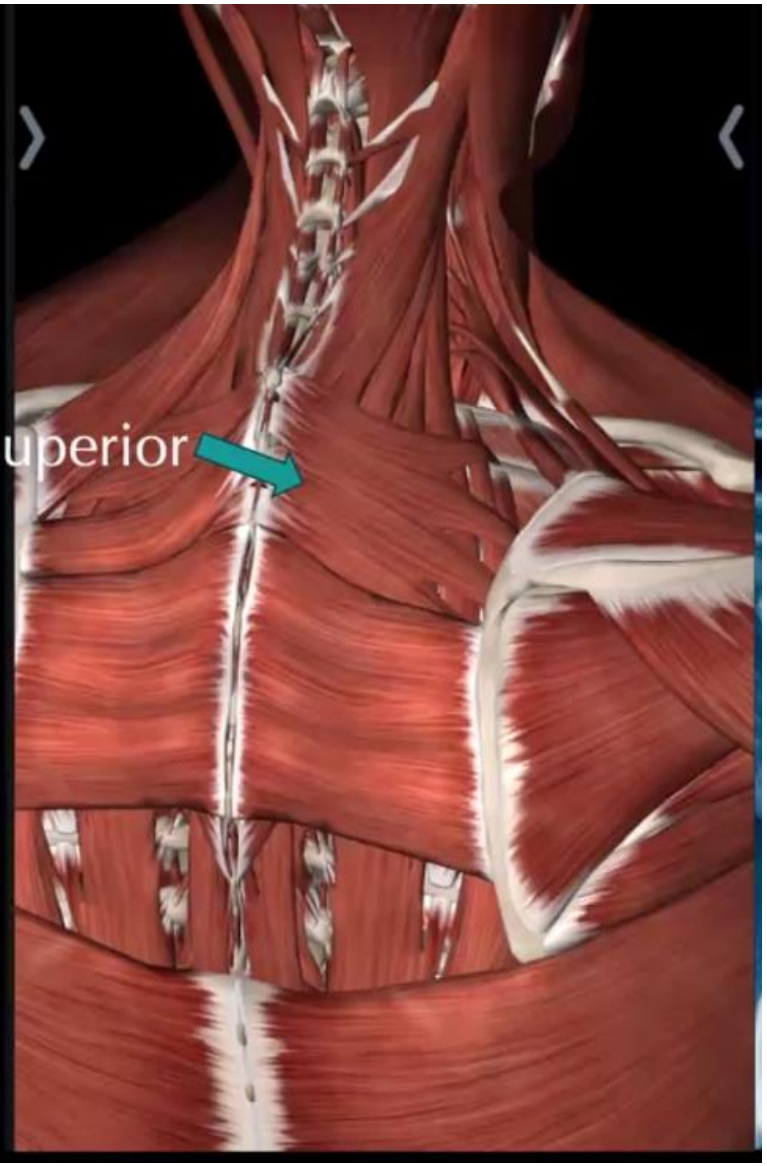

- Origin: Spinous process of C7-T3, supraspinous ligament.
- Insertion: Upper border ribs 2nd-5th

ANATOMY

SPSM lie on the superomedial side of scapula, from superficial to deep.

Originates from C7-T2 (sometimes T3) spinous processes, progressing obliquely and inserting on the lateral of the second to fifth ribs' angles.



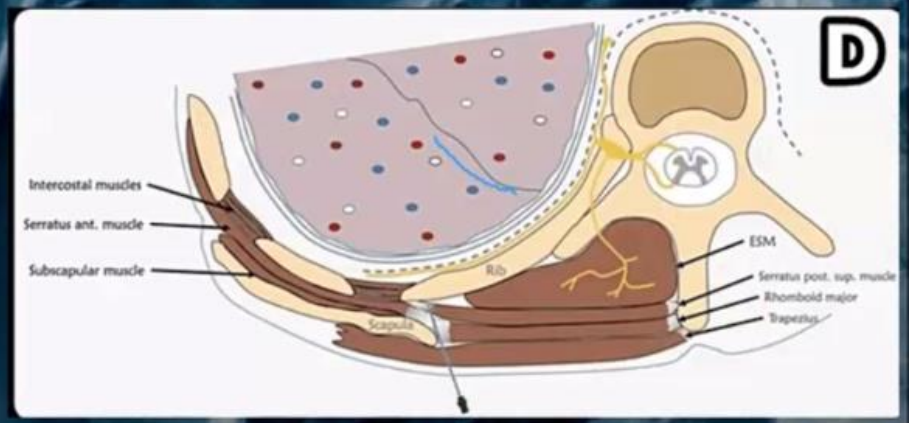

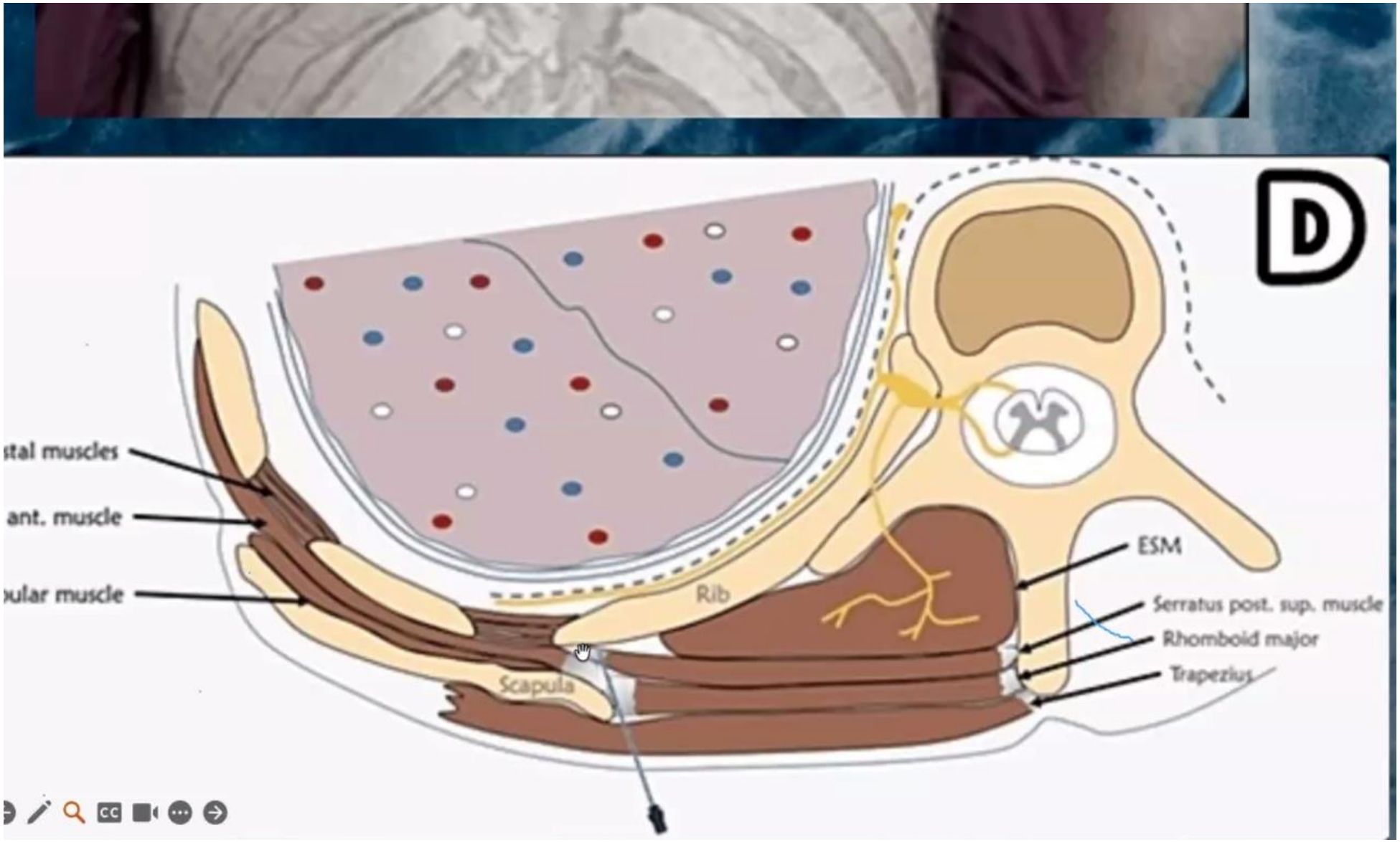
D
stal muscles
ant. muscle
ular muscle
Rib
Scapula
ESM
Serratus post. sup. muscle
Rhomboid major
Trapezius

DERMATOMAL COVERAGE

Sensory blockage of the neck, shoulder, and axilla and caudally to nearly the 7th and 8th thoracic dermatome

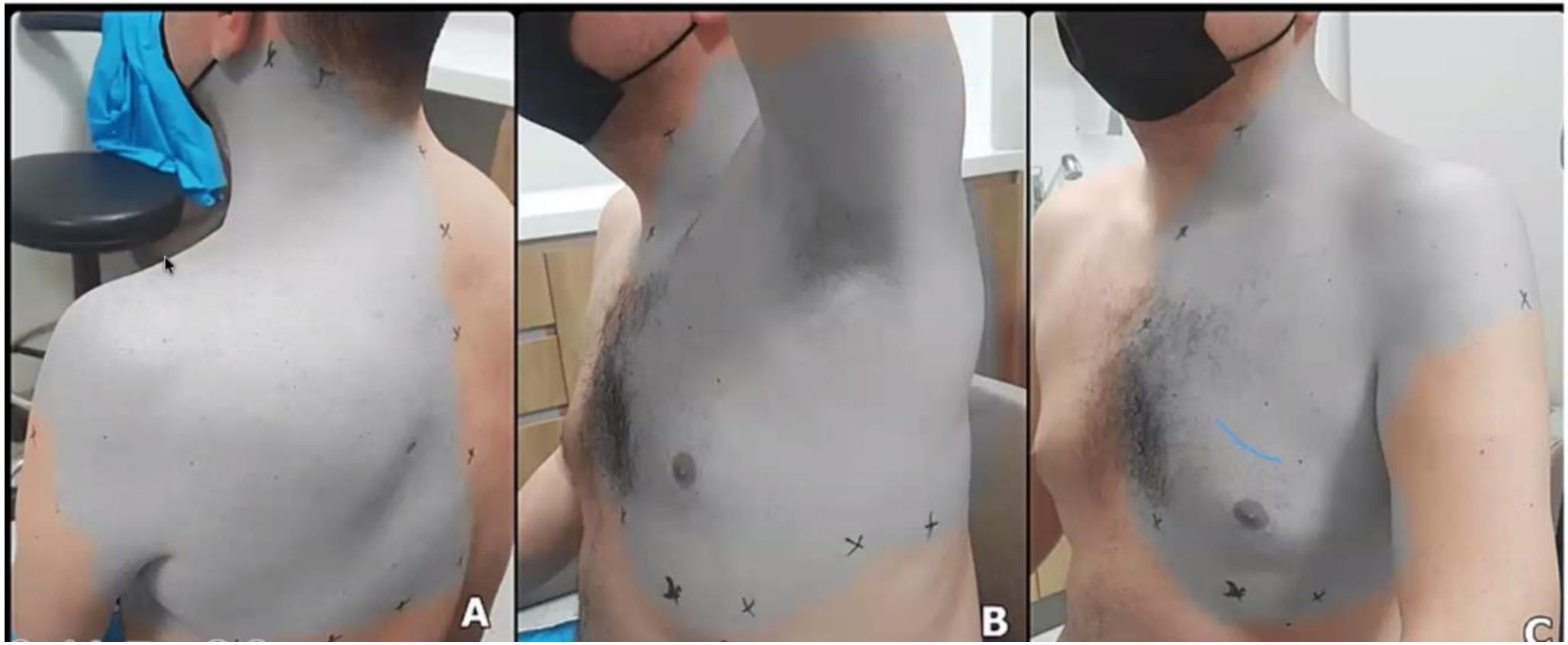

SONOANATOMY

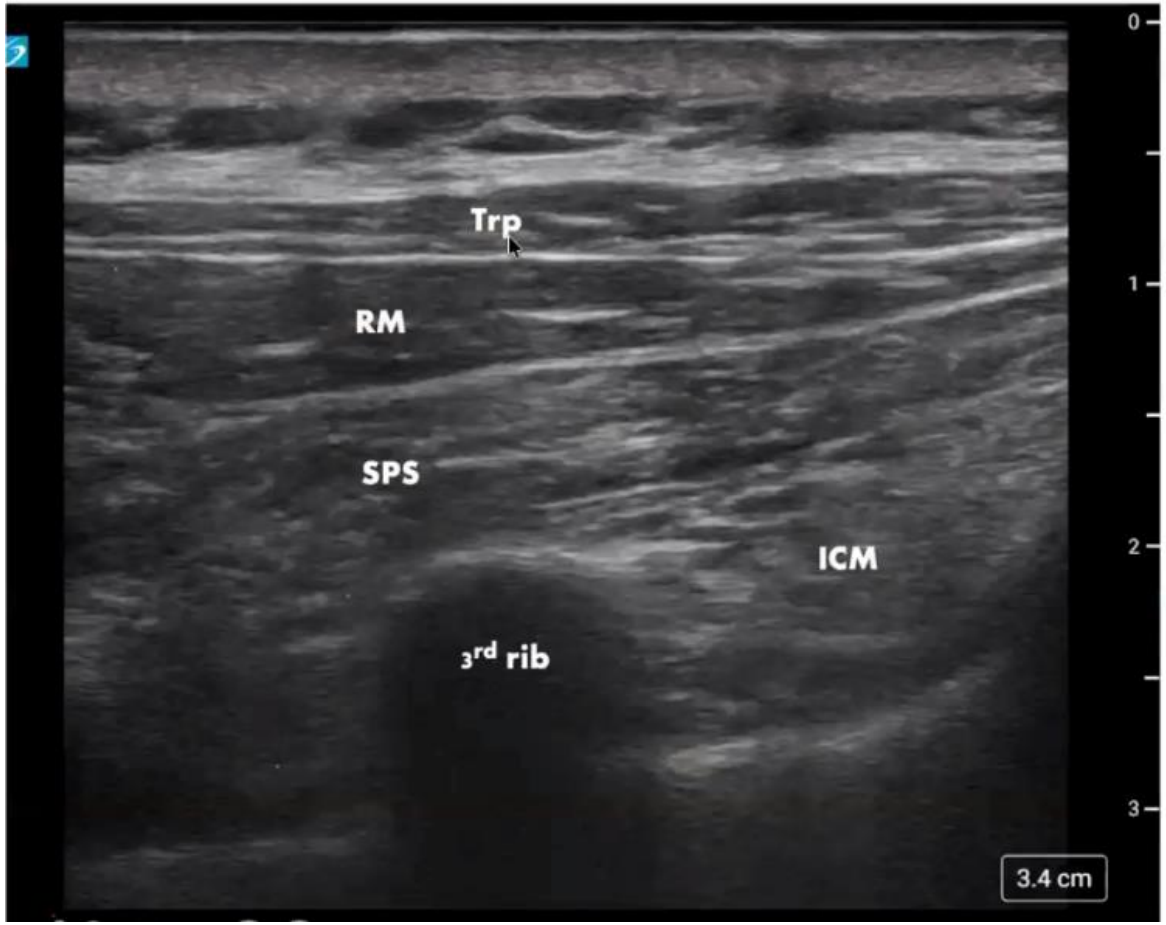

- Trp: Trapezius
- RM: Rhomboid Major
- SPS: Serratus posterior superior
- ICM: Intercostal muscles

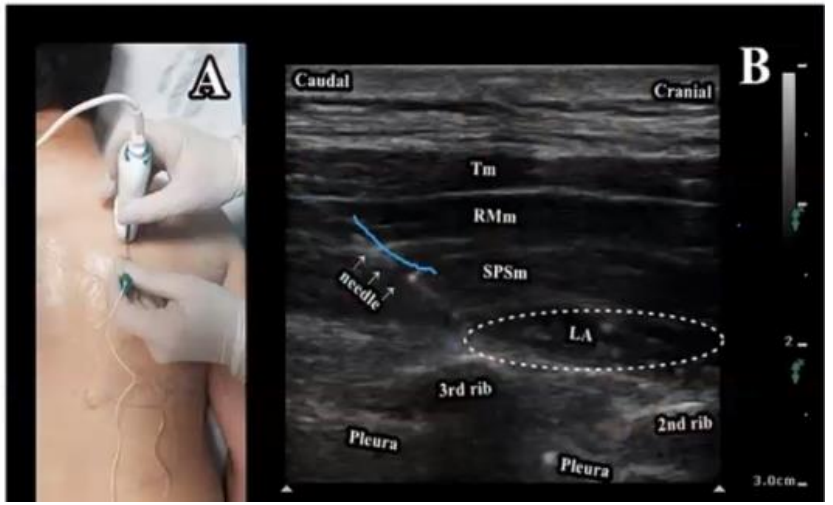

LOCAL ANAESTHESIA DEPOSITION

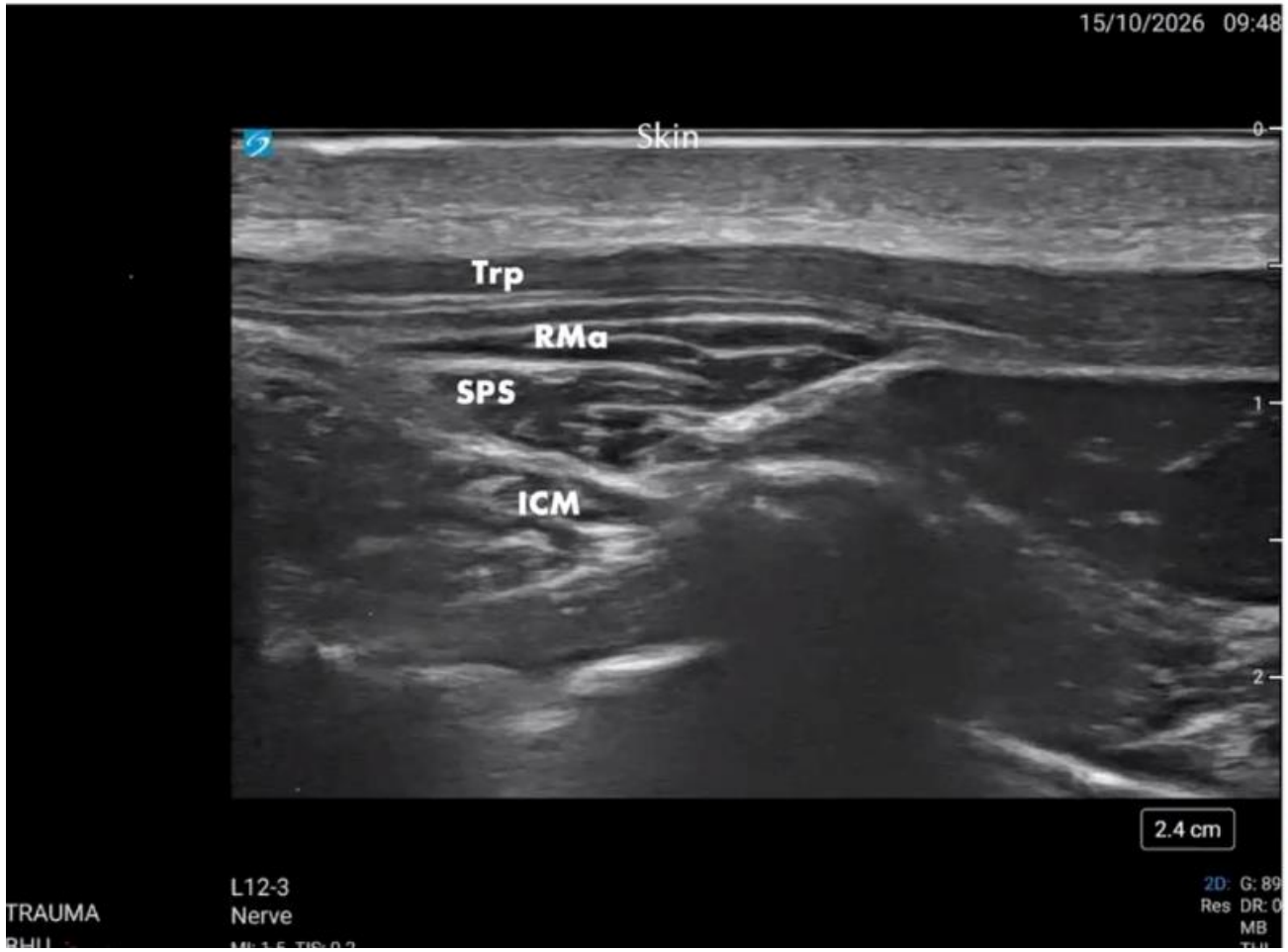

- ✓ In plane/out of plane needling
- ✓ Deposit the drug between ICS and SPSM
- ✓ 30 ml of 0.2 % ropivacaine is injected
- ✓ Caudal to cranial needling
- ✓ Keep the needle in vision
- ✓ Look for the unzippering of the fascial plane

LITERATURE



DOI: 10.4274/TJAR.2024.231431

Case Report
Regional Anaesthesia

Turkish Journal of Anaesthesiology & Reanimation

Breast surgery

Turk J Anaesthesiol Reanim 2024;52(1):33-35

Novel Serratus Posterior Superior Intercostal Plane Block Provided Satisfactory Analgesia after Breast Cancer Surgery: Two Case Reports

Gökçen Kültüroğlu, Savaş Altınsoy, Yusuf Özgüner, Cem Koray Çatıroğlu

Arık et al. BMC Anesthesiology (2026) 26:11
https://doi.org/10.1186/s12871-025-03531-y

BMC Anesthesiology

RESEARCH Open Access

Is the serratus posterior superior intercostal plane block a viable alternative to the erector spinae plane block for postoperative analgesia in breast surgery? A prospective, randomized trial

Emine Arık[1*], Musa Zengin[1], Gaye Şeker[2], Onur Küçük[3], Ezgi Güngördü[1], Yusuf Özgüner[1], Ali Alagöz[4] and Jülide Ergil[1]

Original Article

VATS surgery

Efficacy of serratus posterior superior intercostal plane block (SPSIPB) on post-operative pain and total analgesic consumption in patients undergoing video-assisted thoracoscopic surgery (VATS): A double-blinded randomised controlled trial

Address for correspondence:
Dr. Oğuz Gündoğdu,
Department of Anesthesiology

Onur Avci, Oğuz Gundogdu, Fatih Balci, Muhammed N. Tekcan, Mahmut Ozbey[1]
Departments of Anesthesiology and Reanimation and [1]Thoracic Surgery, Sivas Cumhuriyet University School of Medicine, Sivas/Turkey

Results: The SPSIPB group had lower NRS values during post-operative 24 hours ($P < 0.001$). Mean (standard deviation) total tramadol consumption was 58.33 (26.23) mg in the SPSIPB group and 144.17 (13.11) mg in the control group ($P < 0.001$). Rescue analgesic need was lower in the SPSIP group in the first 18 post-operative hours ($P < 0.05$). **Conclusion:** Serratus posterior superior intercostal plane block provides good analgesia in the thoracic region after video-assisted thoracoscopic surgery.

Case Report

Thoracic cell wall mass on scapular region

Serratus posterior superior intercostal plane block provides effective analgesia for patients undergoing dorsal mass excision: The first report of use in anesthesia practice

BLOCKS OF ABDOMEN

- M-BRILMA (SIPB)
- TAPA
- M-TAPA
- EOIPB

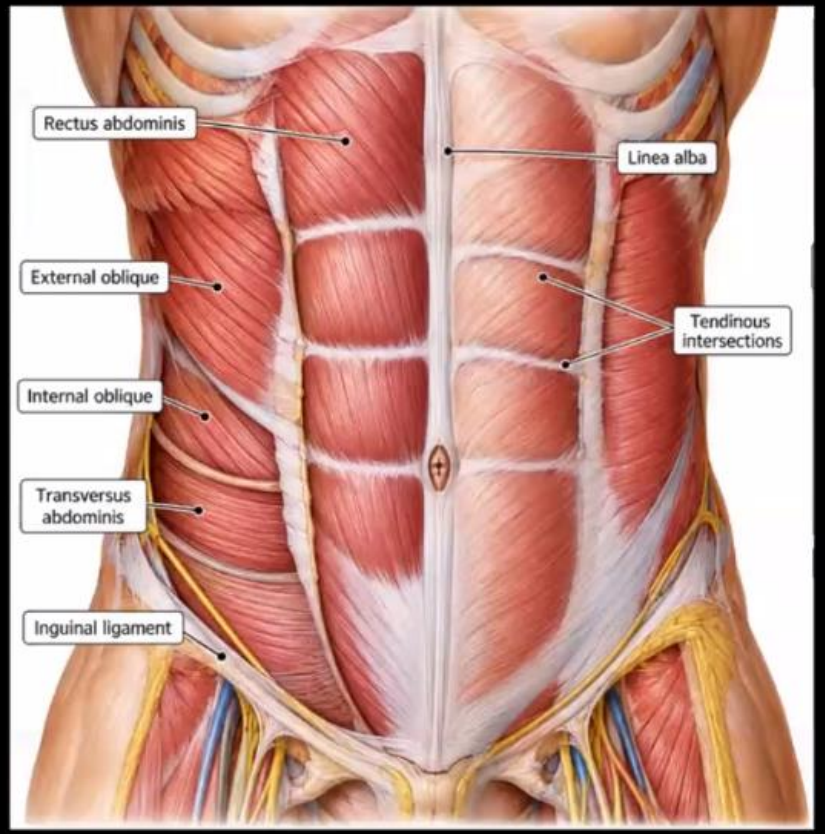

Segmental distribution of cut. nerve on the anterolateral trunk

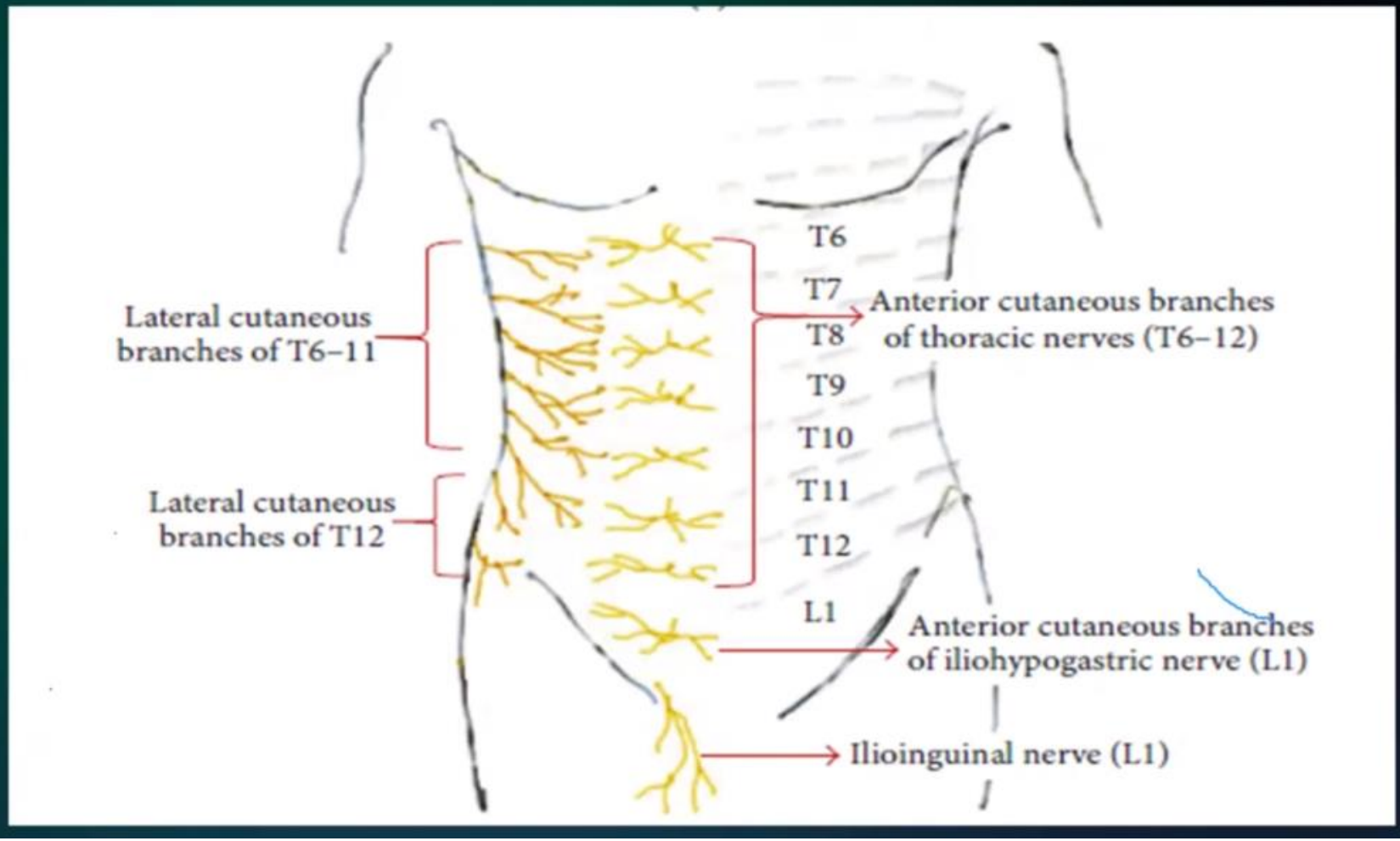

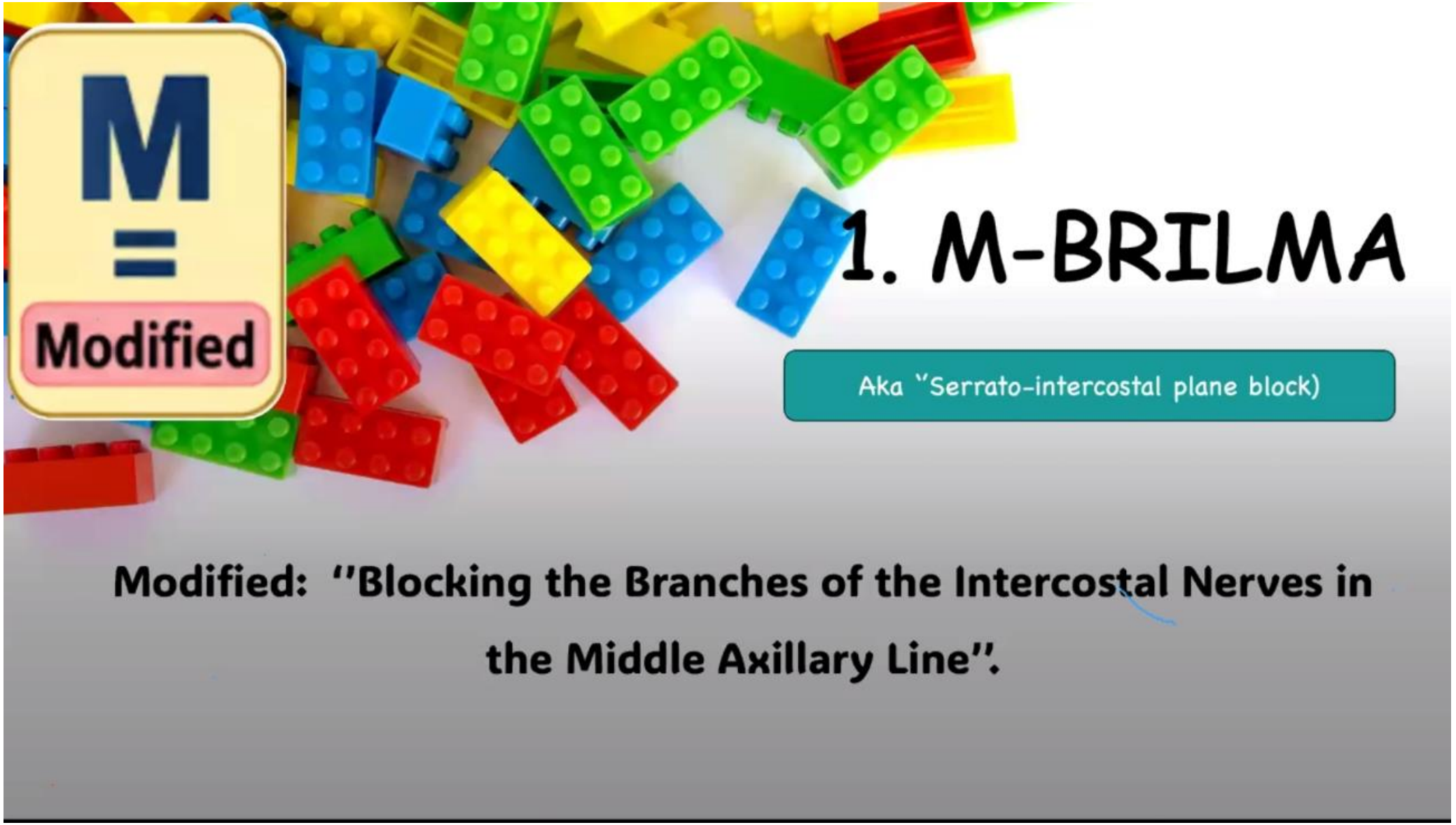
M
=
Modified
1. M-BRILMA
Aka "Serrato-intercostal plane block)
Modified: "Blocking the Branches of the Intercostal Nerves in the Middle Axillary Line".

ERGONOMICS

- ✓Supine position
- ✓Linear high frequency probe
- ✓Probe placement in mid axillary line in 8th rib
- ✓Needle direction: Caudal to cranial



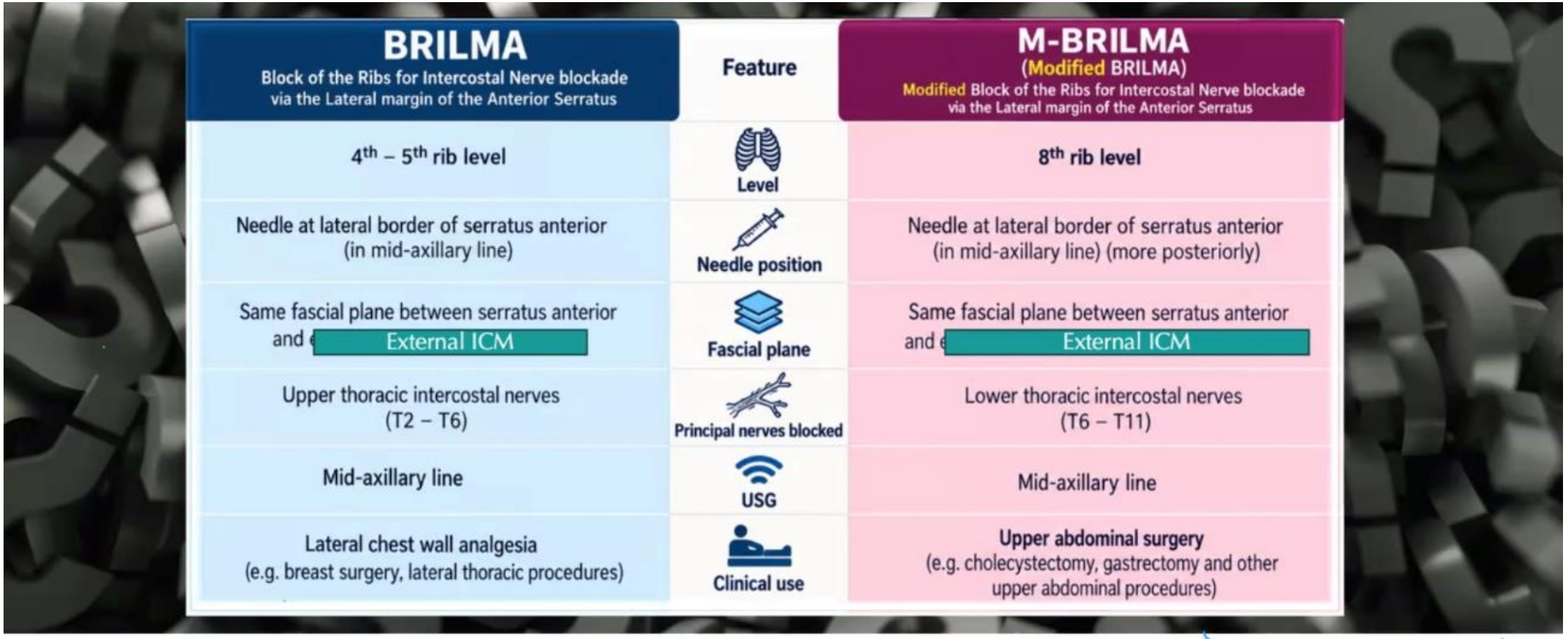

BRILMA Block of the Ribs for Intercostal Nerve blockade via the Lateral margin of the Anterior Serratus	Feature	M-BRILMA (Modified BRILMA) Modified Block of the Ribs for Intercostal Nerve blockade via the Lateral margin of the Anterior Serratus
4th – 5th rib level	Level	8th rib level
Needle at lateral border of serratus anterior (in mid-axillary line)	Needle position	Needle at lateral border of serratus anterior (in mid-axillary line) (more posteriorly)
Same fascial plane between serratus anterior and External ICM	Fascial plane	Same fascial plane between serratus anterior and External ICM
Upper thoracic intercostal nerves (T2 – T6)	Principal nerves blocked	Lower thoracic intercostal nerves (T6 – T11)
Mid-axillary line	USG	Mid-axillary line
Lateral chest wall analgesia (e.g. breast surgery, lateral thoracic procedures)	Clinical use	Upper abdominal surgery (e.g. cholecystectomy, gastrectomy and other upper abdominal procedures)

HOW M-BRILMA DIFFERS FROM BRILMA?

INTRODUCTION





Anatomical target: Serratus–intercostal plane at lower rib levels.

Injection level: Usually around the Eighth rib

Expected coverage: Predominantly lower thoracic intercostal branches, T6–T11.

Clinical application: Open cholecystectomy, gastrectomy and upper abdominal incisions.

SONOANATOMY

- ✓ SAM: Serratus anterior muscle
- ✓ ICM: Intercostal muscles

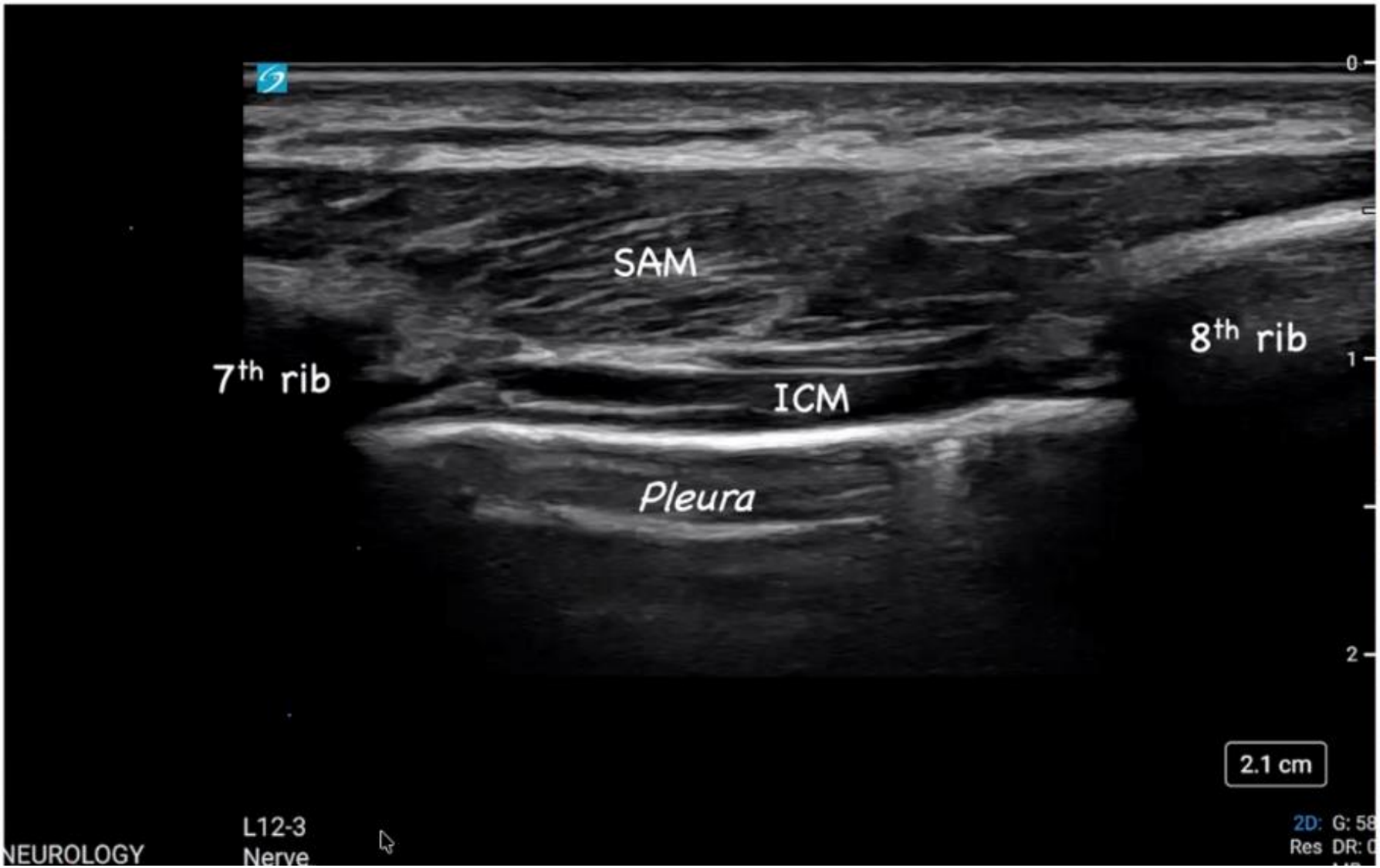



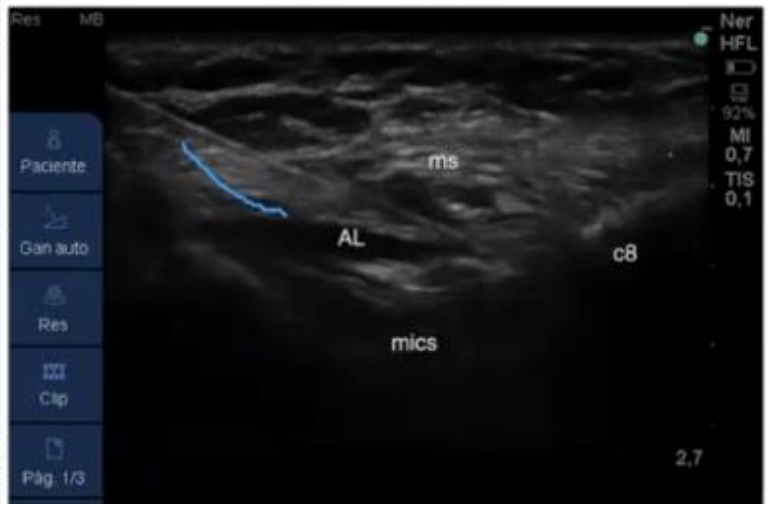


EQUALLY EFFECTIVE
Local and Regional Anesthesia
Dovepress
ORIGINAL RESEARCH
Comparison of Ultrasound-Guided Modified BRILMA Block with Subcostal Transversus Abdominis Plane Block for Postoperative Analgesia in Laparoscopic Cholecystectomy – A Randomized Controlled Trial
Revista Española de Anestesiología y Reanimación
www.elsevier.es/redar
ORIGINAL BREVE
Bloqueo interfascial serrato-intercostal como estrategia ahorradora de opioides en cirugía supraumbilical abierta
M.T. Fernández Martín, S. López Álvarez y M.A. Pérez Herrero
Original Article
Block of the Lateral Branches of the Intercostal Nerve in the Midaxillary Line (BRILMA) for Costal Cartilage Harvest in Plastic Surgery Procedures
Sona Dave, Minal Harde, Esha Kodal, Shubham B. Rathi, Mangesh Gore, Pravin Ubale
Department of Anaesthesiology, T. N. Medical College and BYL Nair Ch. Hospital, Mumbai, Maharashtra, India
Ultrasound-guided modified blocking the branches of intercostal nerves in the middle axillary line (BRILMA) block as the sole anaesthetic technique for incision and drainage of truncal abscess in a high-risk patient
Revista Española de Anestesiología y Reanimación
CASE REPORT
BRILMA block for costal cartilage excision: Case report
T. Silva Pereira, C. Rodrigues Silva, N.F. Veiga, P. Alfaro de la Torre,
LITERATURE SEARCH

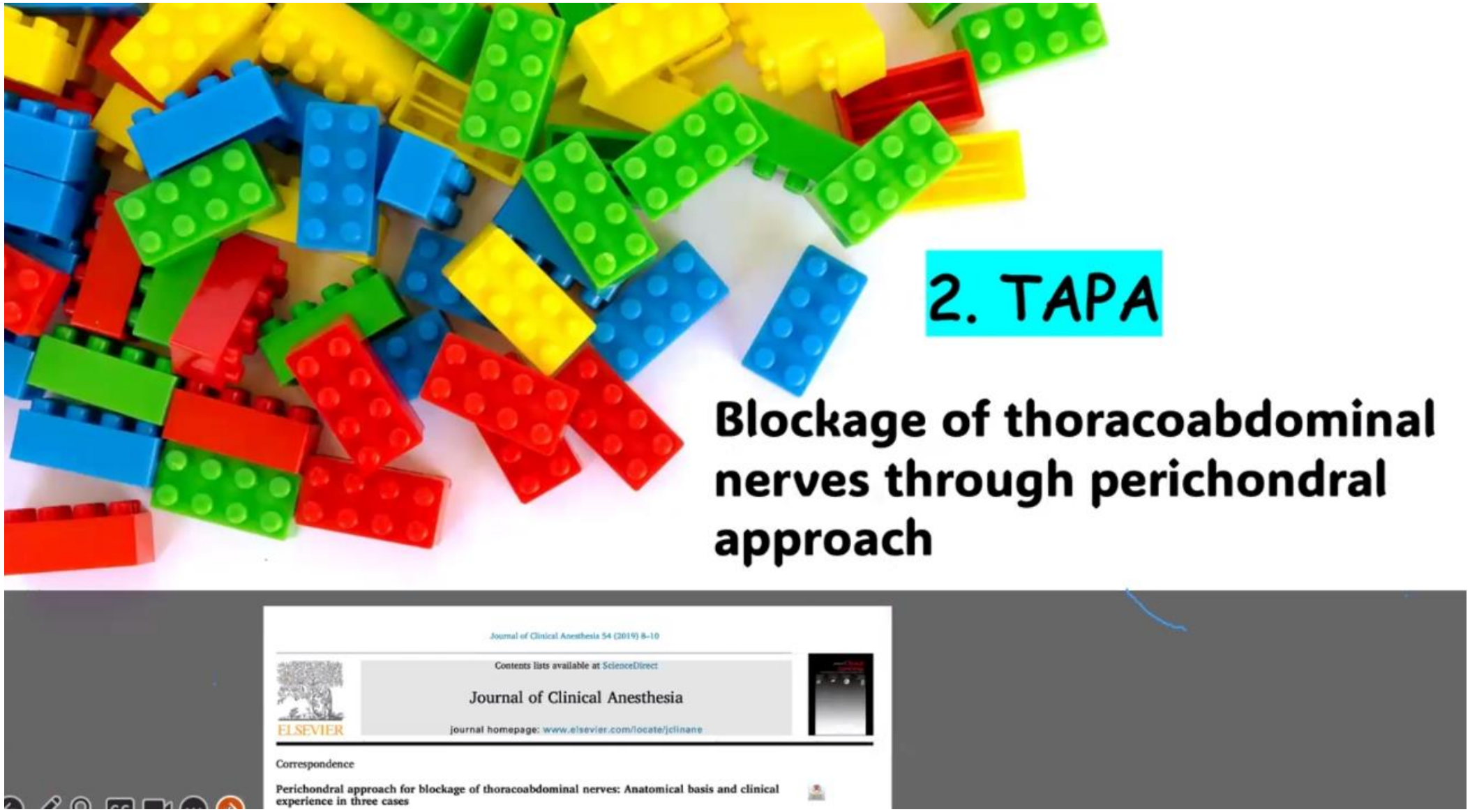
2. TAPA
Blockage of thoracoabdominal nerves through perichondral approach
Journal of Clinical Anesthesia 54 (2019) 8–10
Contents lists available at ScienceDirect
Journal of Clinical Anesthesia
journal homepage: www.elsevier.com/locate/jclinane
ELSEVIER
Correspondence
Perichondral approach for blockage of thoracoabdominal nerves: Anatomical basis and clinical experience in three cases

ANATOMICAL DESCRIPTION

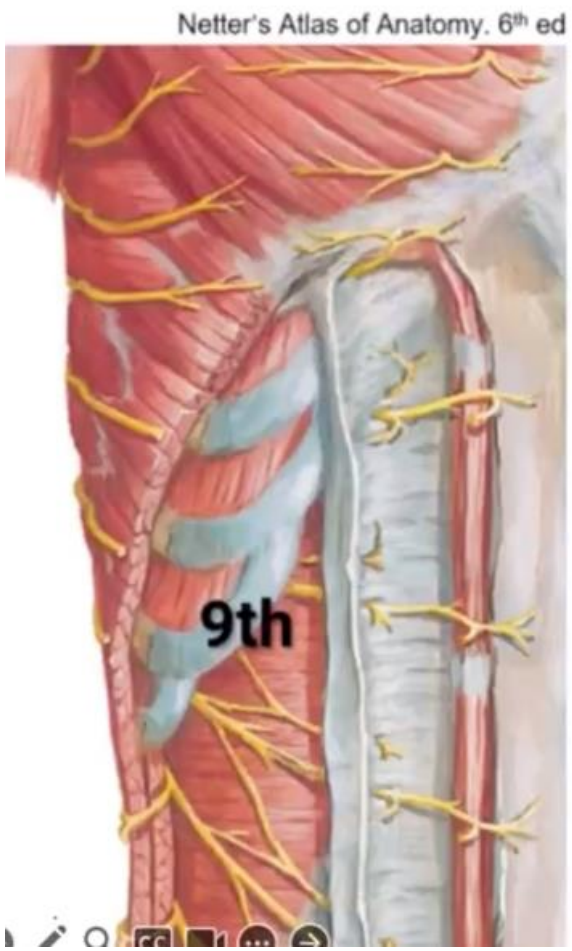





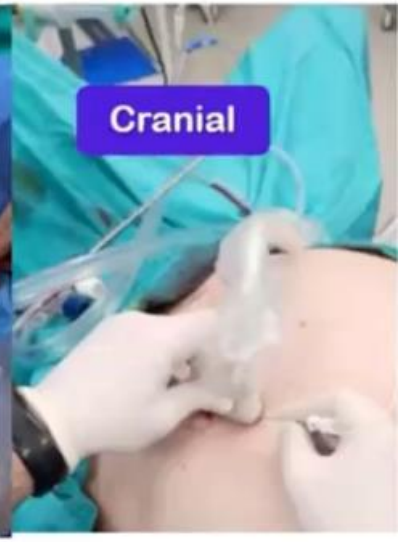

- ✓ The 6th to 10th ICN pass under the chondrium, between the origin of the TAM and the cartilage
- ✓ LA administered above and below block the 9th–10th costal cartilages both the anterior and lateral cut. branches of ICN

INTRODUCTION

Perichondrial region around the lower costal cartilage, typically the tenth costal cartilage.

Injection technique: Two injections, one superficial and one deep to the costal cartilage.

Neural target: Anterior and lateral cutaneous branches of the thoracoabdominal nerves.

Sensory distribution: Approximately T5–T12, although actual spread varies.

Clinical application: Laparoscopic and open abdominal surgery.

BLOCK PERFORMANCE

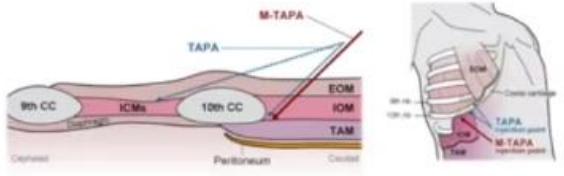

- Supine position
- Linear high frequency probe
- Probe placement between mid axillary line and AAL at 9th CC
- Needle direction: Caudal to cranial

- 2 injections: one between CC and TA muscle
- 2nd between CC and EO muscle

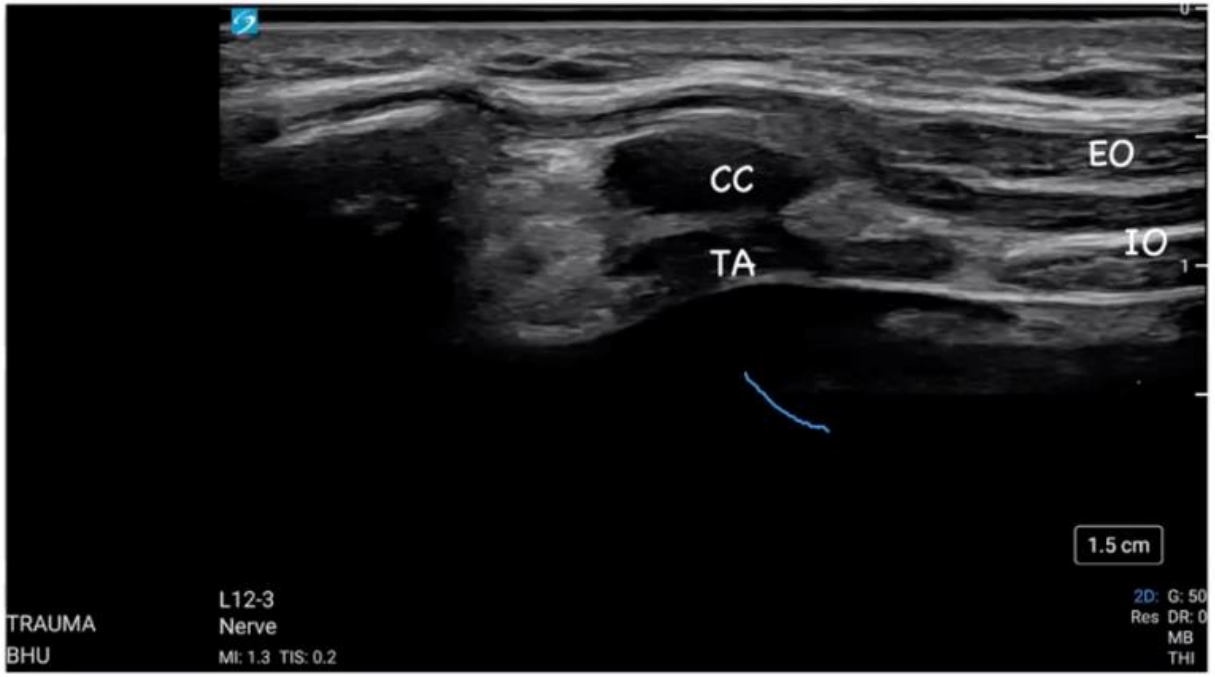



3. M-TAPA

Modification of Blockage of thoracoabdominal nerves through perichondral approach

Contents lists available at ScienceDirect

Journal of Clinical Anesthesia

journal homepage: www.elsevier.com/locate/jclinane

Correspondence

Modified thoracoabdominal nerves block through perichondrial approach (M-TAPA) provides effective analgesia in abdominal surgery and is a choice for opioid sparing anesthesia

THE MODIFICATION

Single injection below the 9th CC (between the CC and TA muscle)

Caudal to cranial in plane needling

25 ml of 0.2% Ropi-

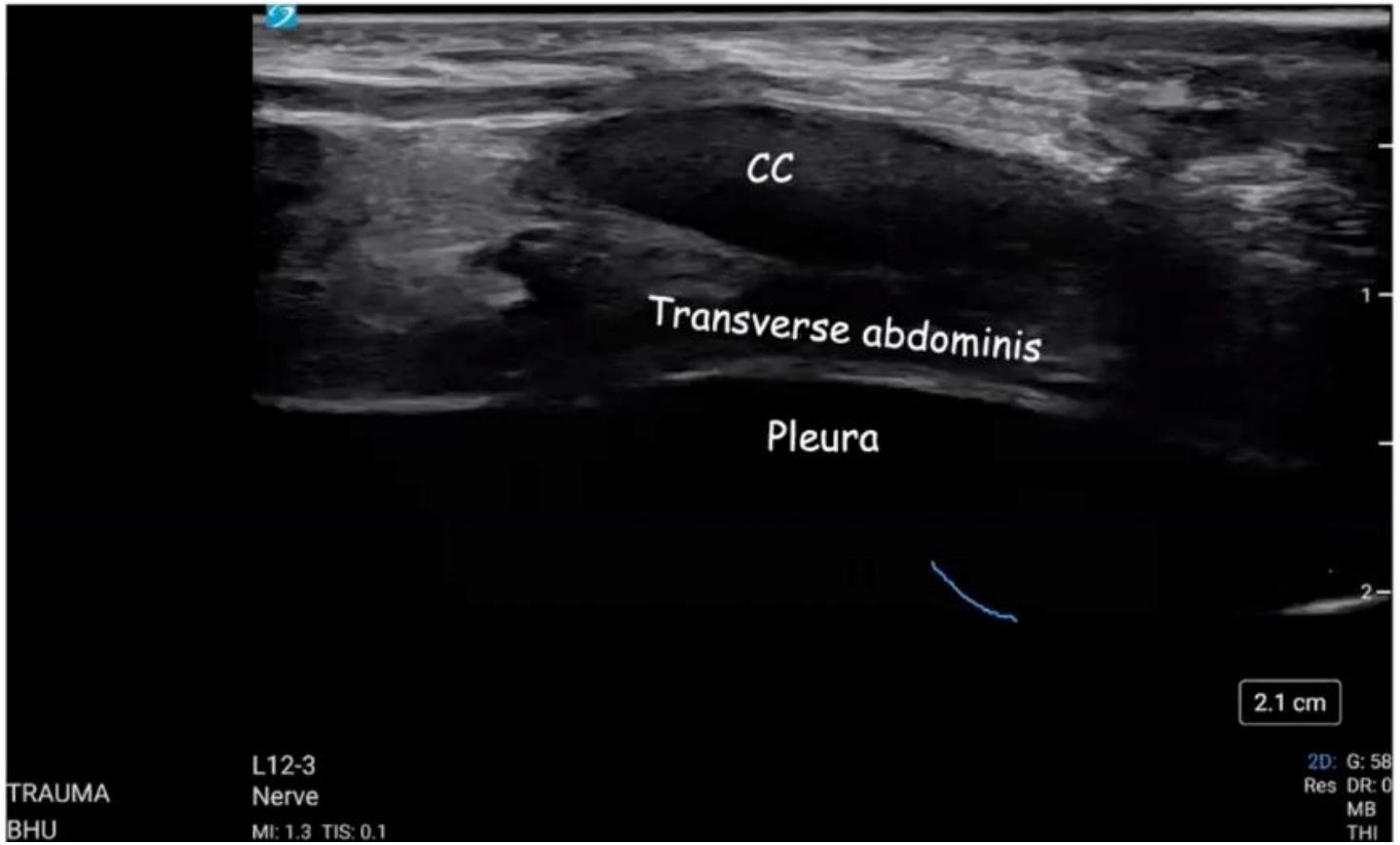

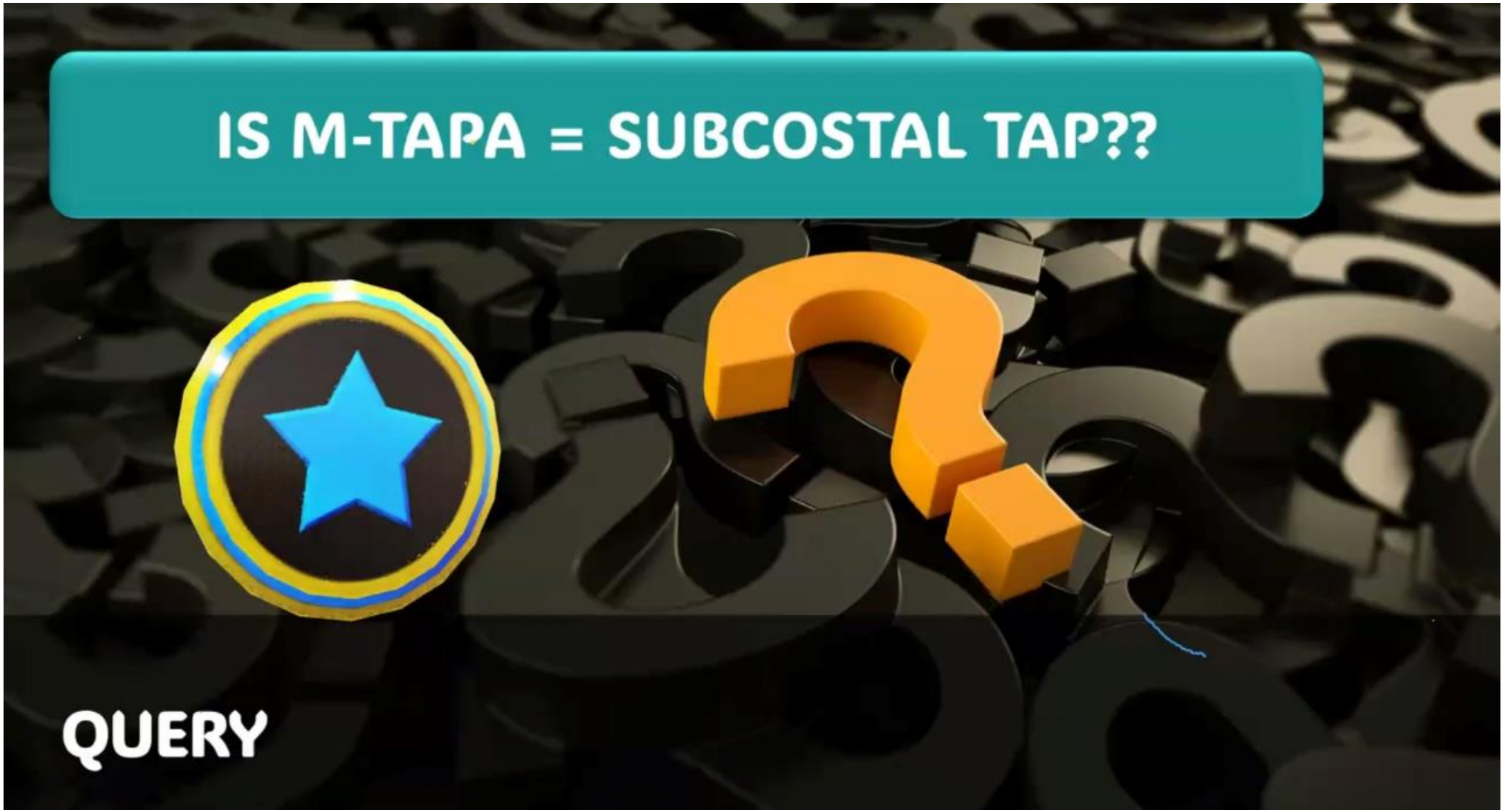
IS M-TAPA = SUBCOSTAL TAP??
QUERY

KJP

Korean J Pain 2023;36(3):382-391
https://doi.org/10.3344/kjp.23114
pISSN 2005-9159, eISSN 2093-0569

Clinical Research Article

Comparison of modified thoracoabdominal nerve block through perichondral approach and subcostal transversus abdominis plane block for pain management in laparoscopic cholecystectomy: a randomized-controlled trial

Hye-Yeon Cho[1], In Eob Hwang[2], Mirang Lee[3], Wooil Kwon[3,4], Won Ho Kim[1,2], and Ho-Jin Lee[1,2]

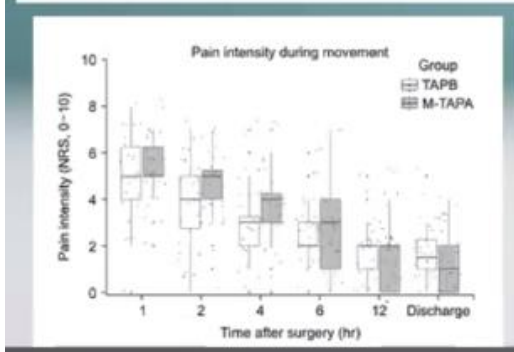

- No difference in pain scores at rest/movement
- 24-hour opioid consumption same

Bilge et al. BMC Anesthesiology (2023) 23:139
https://doi.org/10.1186/s12871-023-02106-z

BMC Anesthesiology

RESEARCH Open Access

Comparing ultrasound-guided modified thoracoabdominal nerves block through perichondrial approach with oblique subcostal transversus abdominis plane block for patients undergoing laparoscopic cholecystectomy: a randomized, controlled trial

Ayşegül Bilge[1*], Betül Başaran[1], Başak Altıparmak[2], Tayfun Et[1], Muhammet Korkusuz[1] and Rafet Yarımoğlu[1]

LITERATURE

4. EOICPB BLOCK

External oblique intercostal plane block

Is a Thoracic Fascial Plane Block the Answer to Upper Abdominal Wall Analgesia?

Accepted for publication: April 7, 2018.

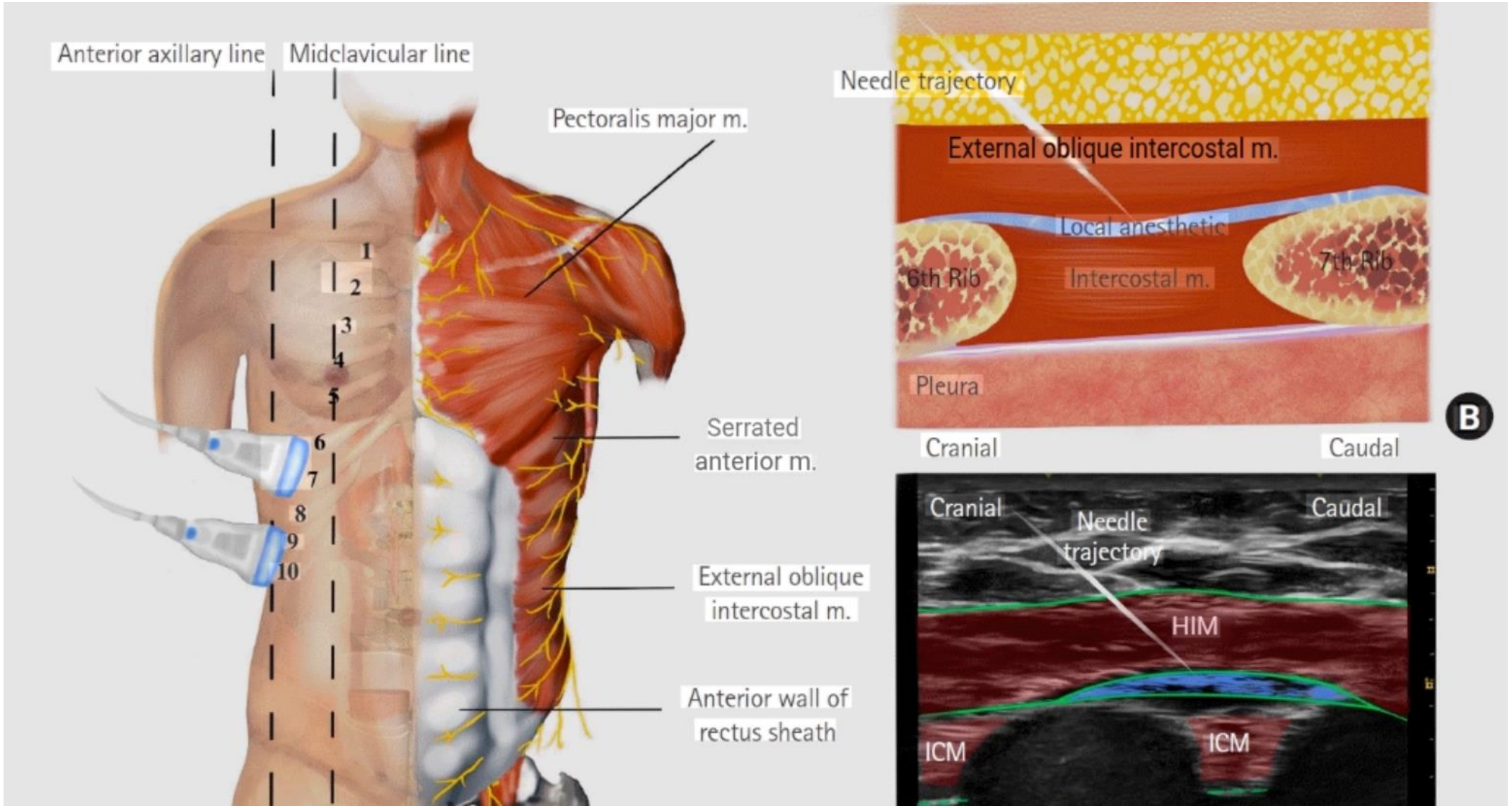
Anterior axillary line
Midclavicular line
Pectoralis major m.
Serrated anterior m.
External oblique intercostal m.
Anterior wall of rectus sheath
1
2
3
4
5
6
7
8
9
10
Needle trajectory
External oblique intercostal m.
Local anesthetic
6th Rib
Intercostal m.
7th Rib
Pleura
Cranial
Caudal
B
Cranial
Needle trajectory
Caudal
HIM
ICM
ICM

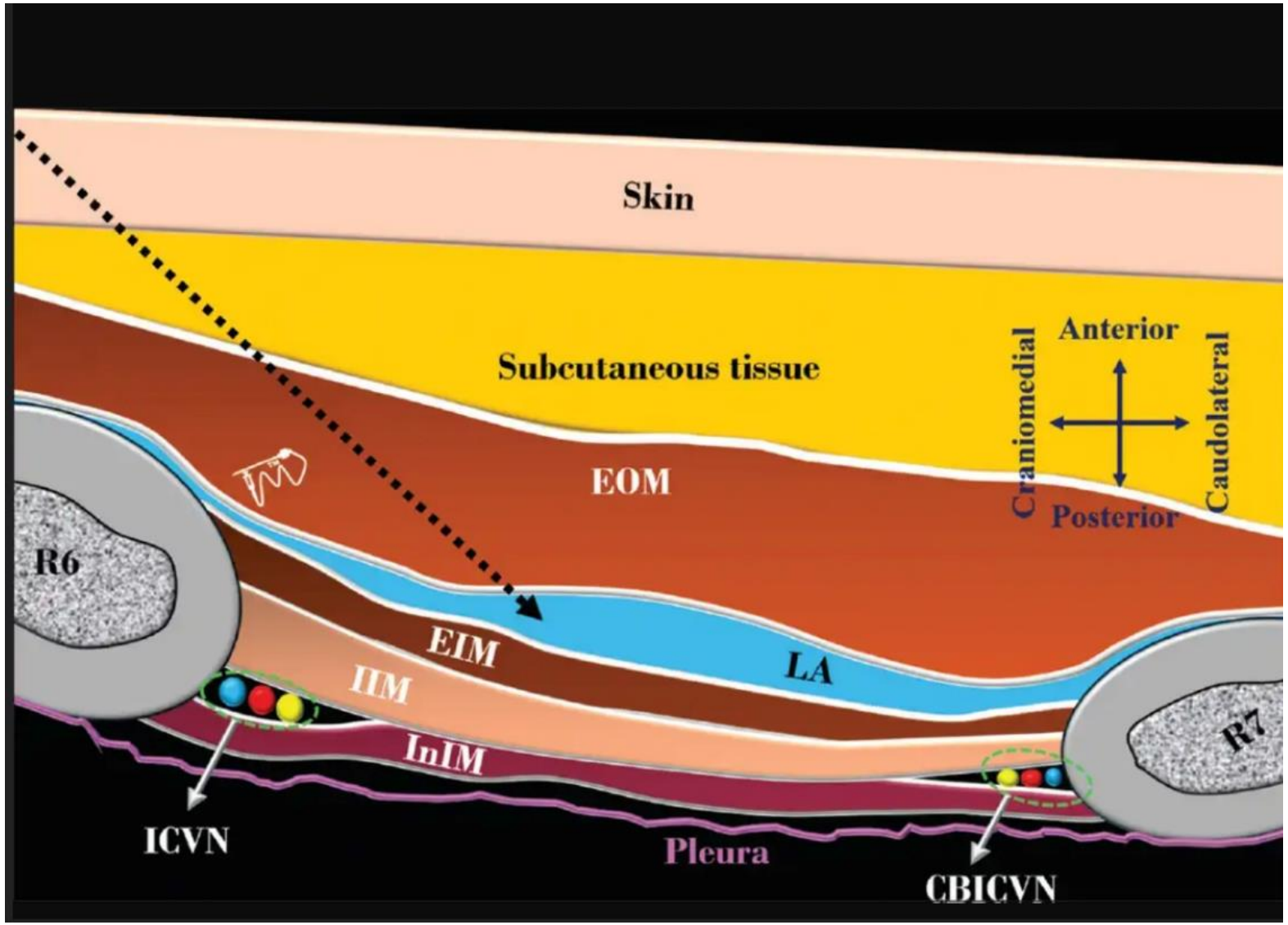
Skin
Subcutaneous tissue
EOM
Anterior
Craniomedial
Caudolateral
Posterior
R6
EIM
IIM
LA
InIM
R7
ICVN
Pleura
CBICVN

External oblique intercostal block

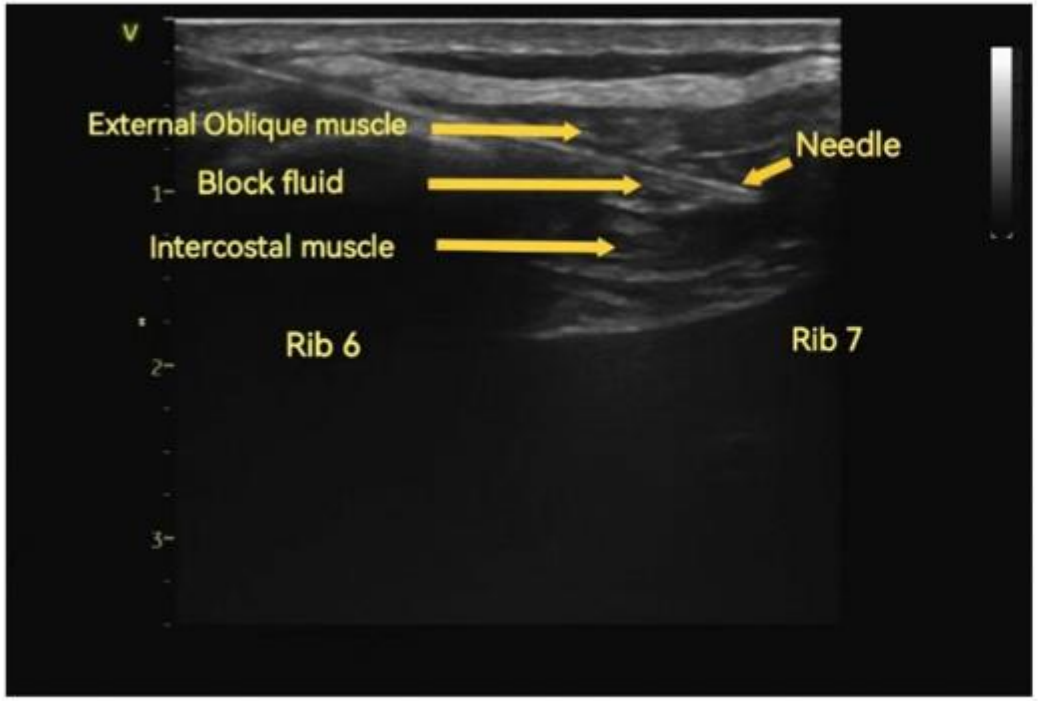

Target: plane between external oblique and intercostal muscles

Upper abdominal applications

Head-to-head studies include EOI versus M-TAPA.

New anatomy needs procedure-specific comparative evidence.

EXTERNAL OBLIQUE INTERCOSTAL PLANE BLOCK

Inter-fascial plane block between ICM and EOM

Performed at the level of 6th rib between MCL and AAL

Blocks the anterior (T6-T9) and lateral(T7-T10) cutaneous branches of the intercostal nerve

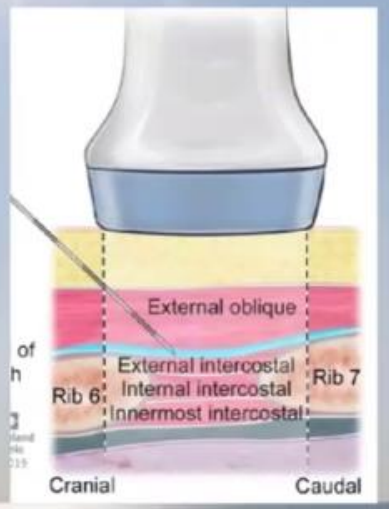

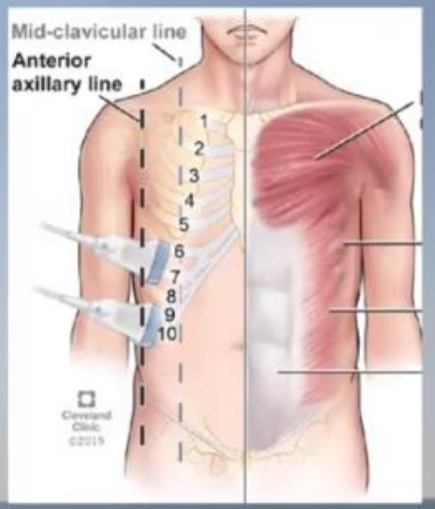

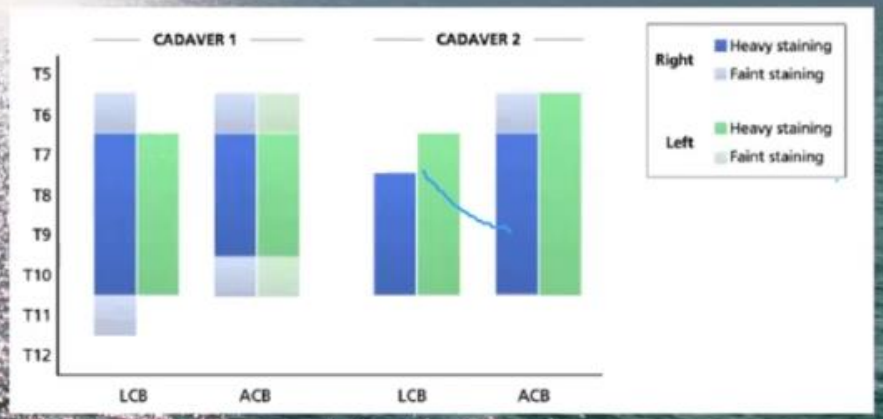

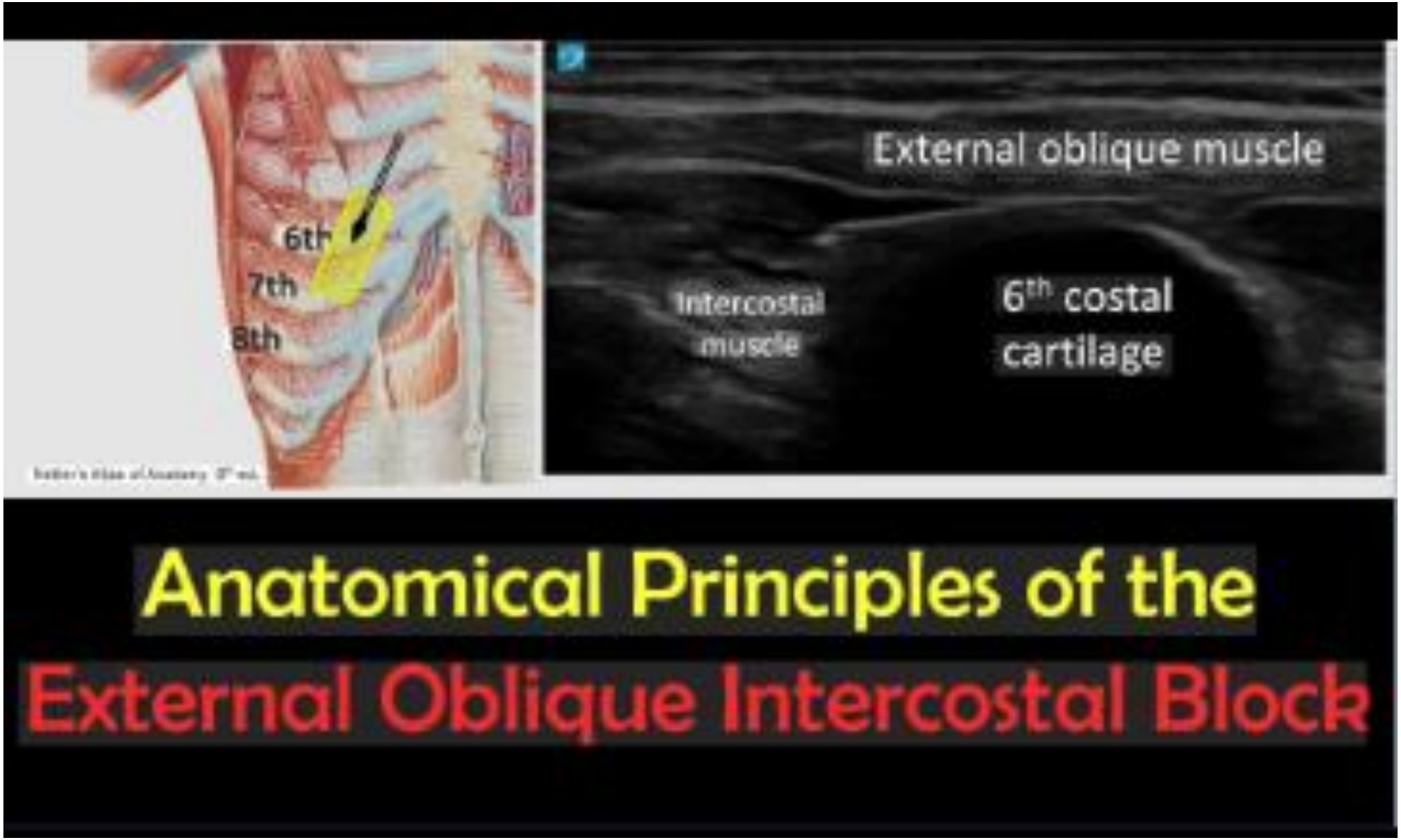
6th
7th
8th
External oblique muscle
Intercostal muscle
6th costal cartilage
Anatomical Principles of the
External Oblique Intercostal Block

EXTERNAL OBLIQUE MUSCLE



Origin: External surfaces of the 5th–12th ribs (lower eight ribs).

- Upper five digitations interdigitate with the serratus anterior muscle.
- Lower three digitations interdigitate with the latissimus dorsi muscle.

Insertion

- Linea alba via its broad aponeurosis.
- 5th-7th costal cartilage
- Anterior half of the iliac crest

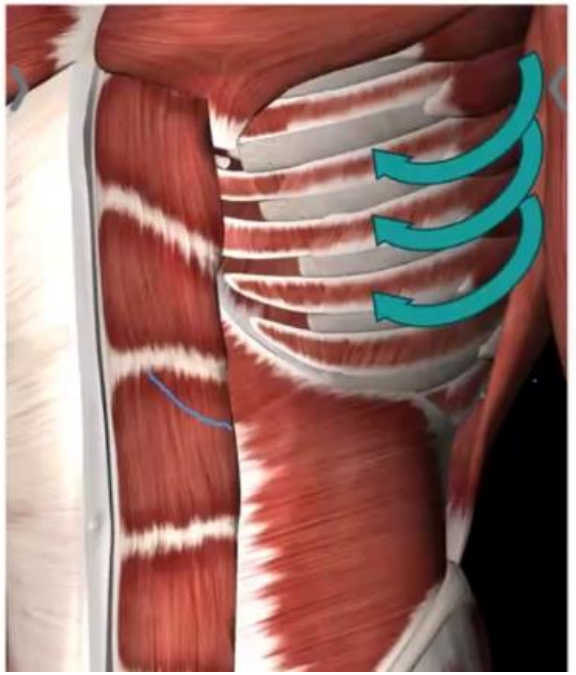

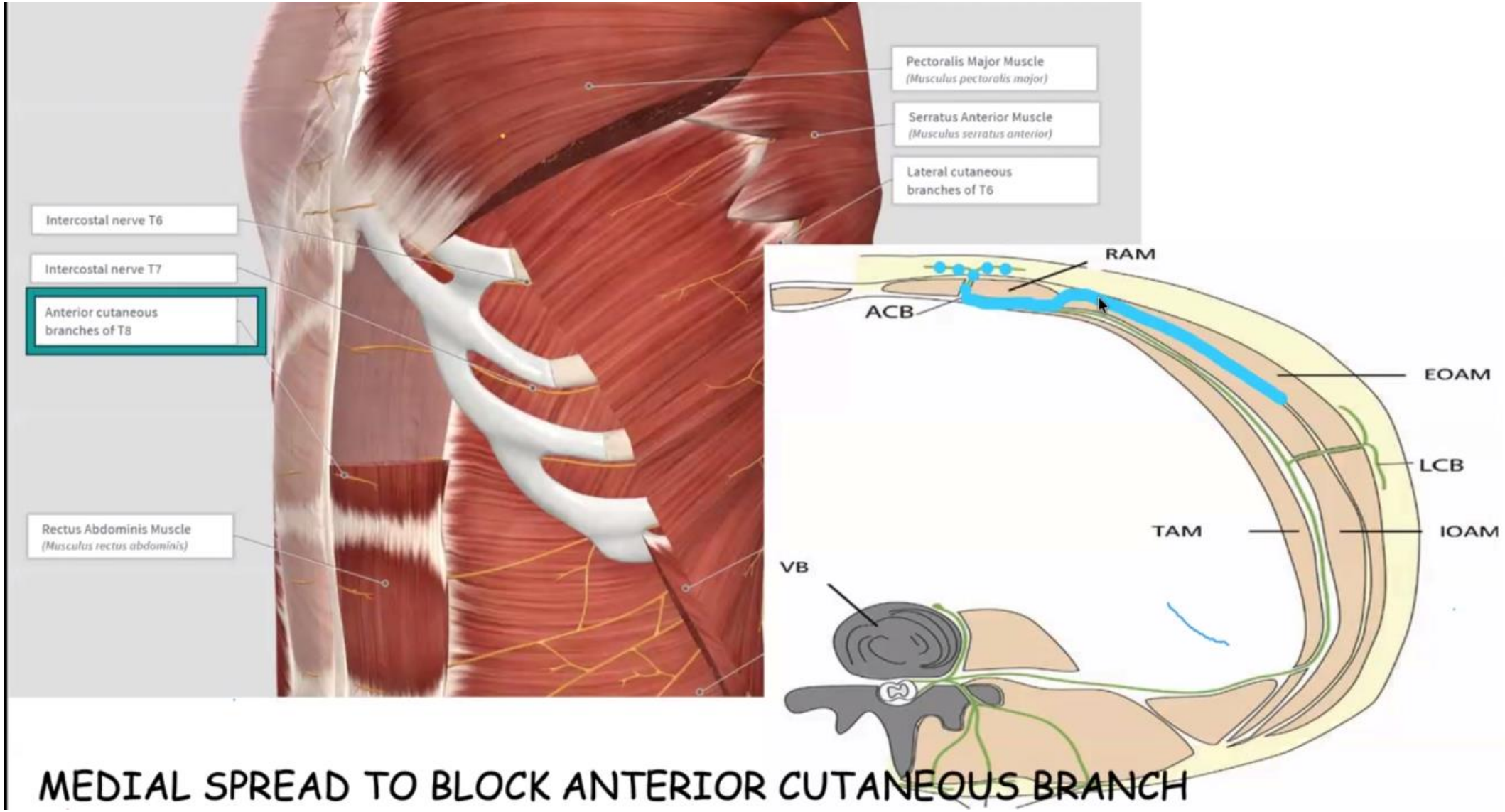
Pectoralis Major Muscle
(Musculus pectoralis major)
Serratus Anterior Muscle
(Musculus serratus anterior)
Lateral cutaneous branches of T6
Intercostal nerve T6
Intercostal nerve T7
Anterior cutaneous branches of T8
Rectus Abdominis Muscle
(Musculus rectus abdominis)
RAM
ACB
EOAM
LCB
TAM
IOAM
VB
MEDIAL SPREAD TO BLOCK ANTERIOR CUTANEOUS BRANCH

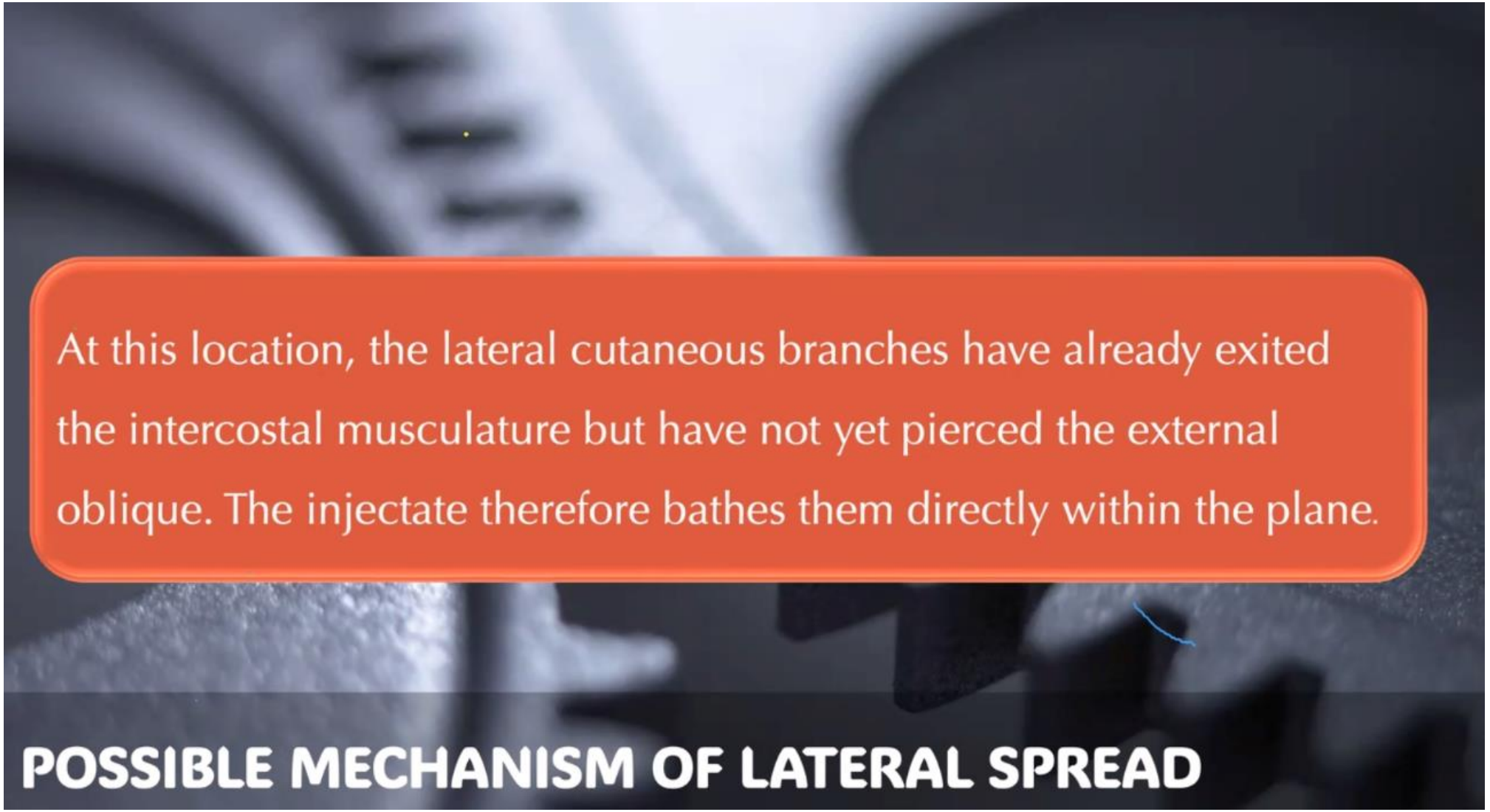
At this location, the lateral cutaneous branches have already exited the intercostal musculature but have not yet pierced the external oblique. The injectate therefore bathes them directly within the plane.
POSSIBLE MECHANISM OF LATERAL SPREAD

INDICATION

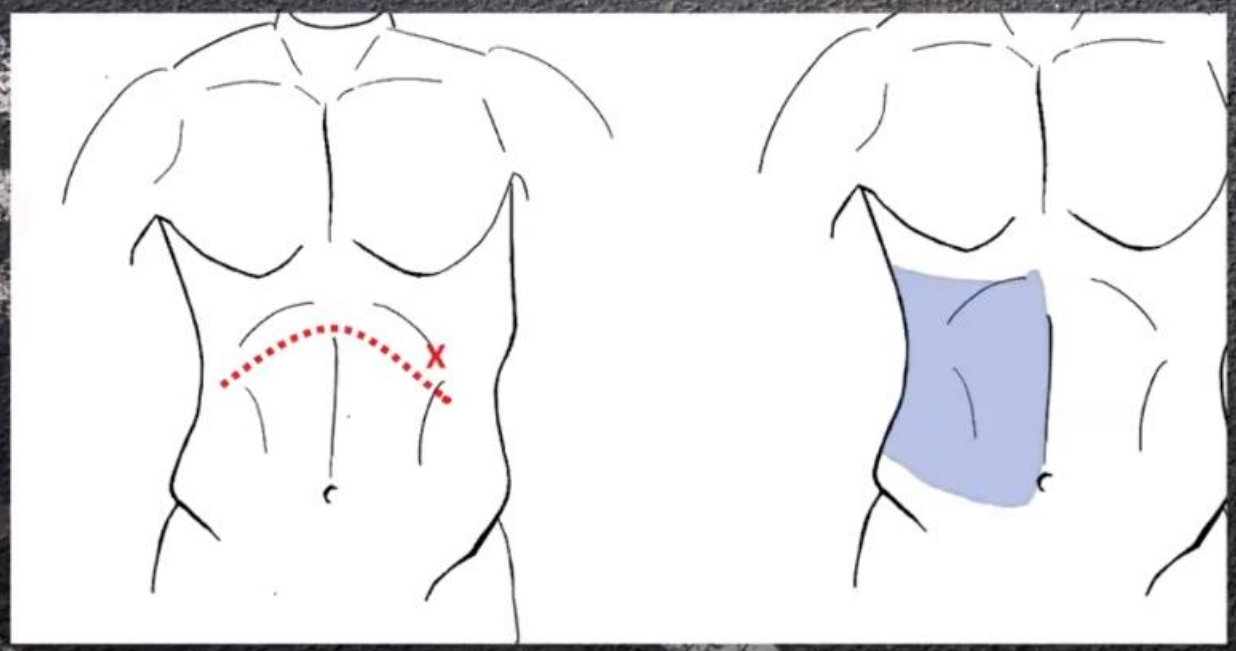

Operation	EOI Technique
Small bowel resection	Single injection
Partial colectomy	Catheters
Laparoscopic Whipple's	Single injection
Ileocolectomy	Single injection
Retroperitoneal mass excision	Single injection
Laparoscopic sigmoidectomy	Single injection
Liver transplantation	Catheters
Laparoscopic gastrectomy	Single injection
Laparoscopic proctopexy	Single injection
Exploratory laparotomy	Catheters
Partial colectomy	Single injection
Small bowel resection	Single injection
Exploratory laparotomy	Single injection
Liver transplant	Single injection
Donor nephrectomy	Catheters
Nissen fundoplication	Single injection
Donor hepatectomy	Catheters
Revision biliary anastomosis	Catheters
Biliary-enteric anastomosis	Single injection
Excision of ampulla of Vater	Single injection
Renal transplantation	Single injection
Closure enterostomy	Single injection

ERGONOMICS



- Supine position with side to be blocked tilted up
- Mark the midclavicular and anterior axillary line
- Linear high frequency probe
- Place the probe over the 6th rib in a paramedian sagittal oblique orientation with cephalad end facing medial and caudad end of probe facing lateral

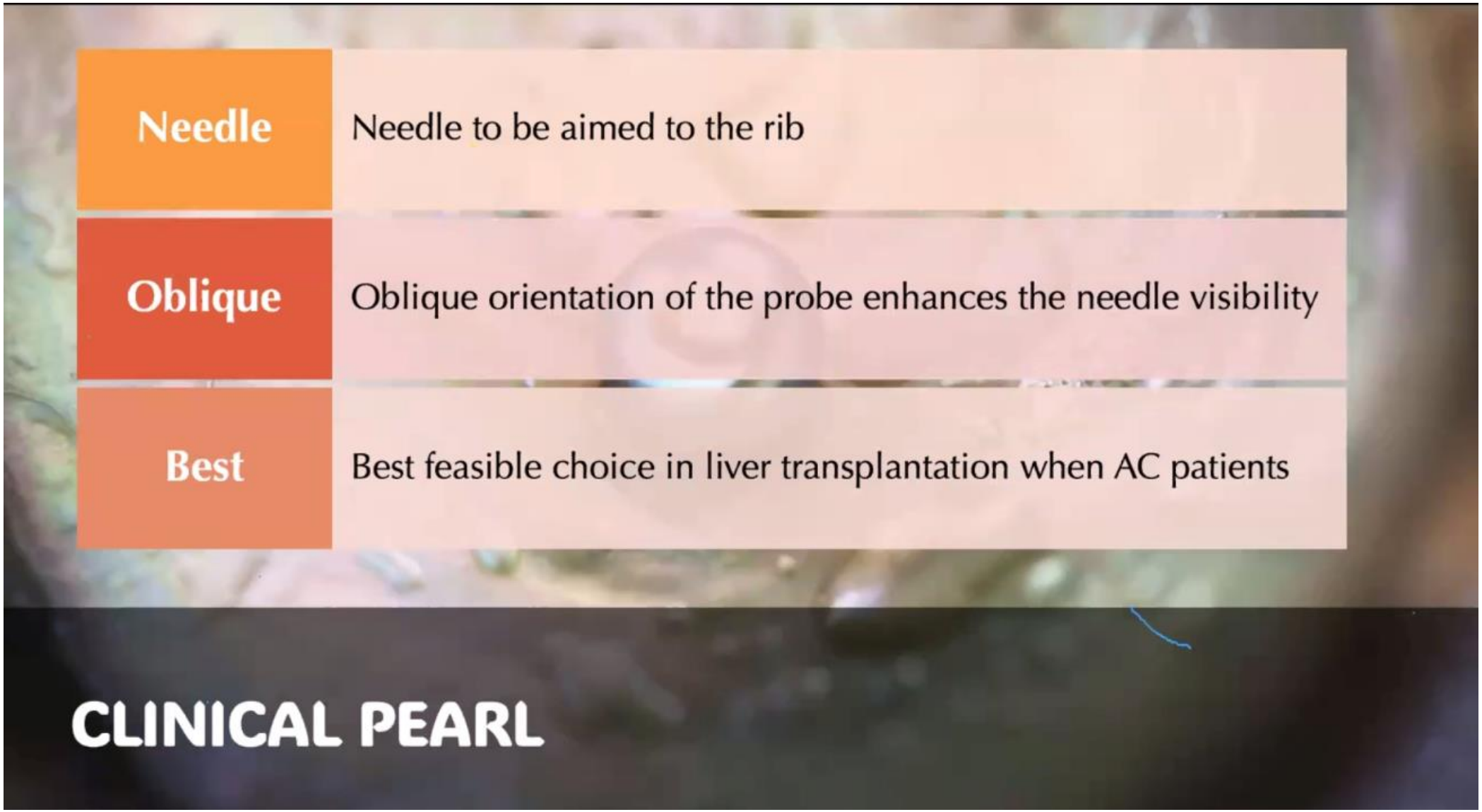
Needle
Needle to be aimed to the rib
Oblique
Oblique orientation of the probe enhances the needle visibility
Best
Best feasible choice in liver transplantation when AC patients
CLINICAL PEARL

a

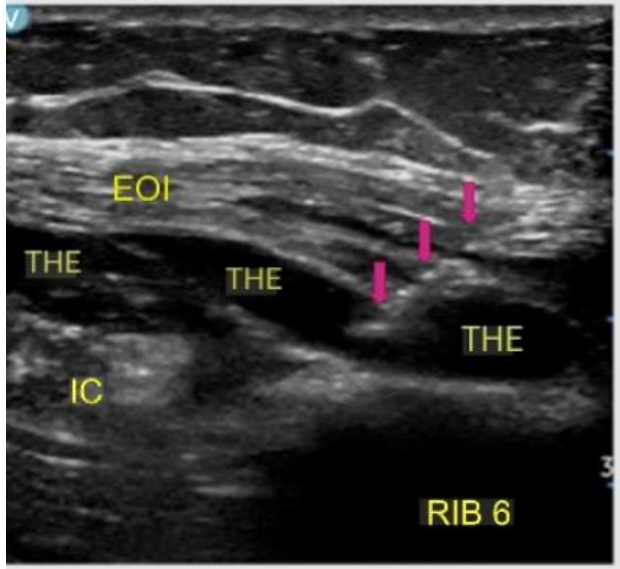

EOI: External oblique muscle
IC: Intercostal muscle
RIB 6: 6th rib
LA: Local anaesthetic
Pink arrows: Needle
Purple arrows: Catheter

b

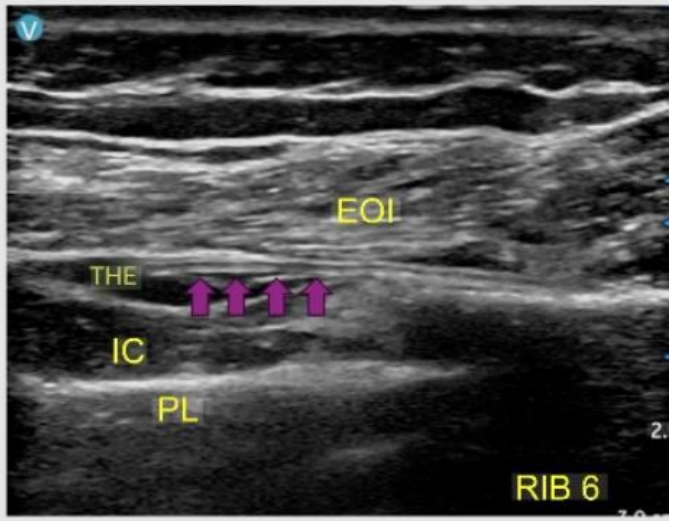

c



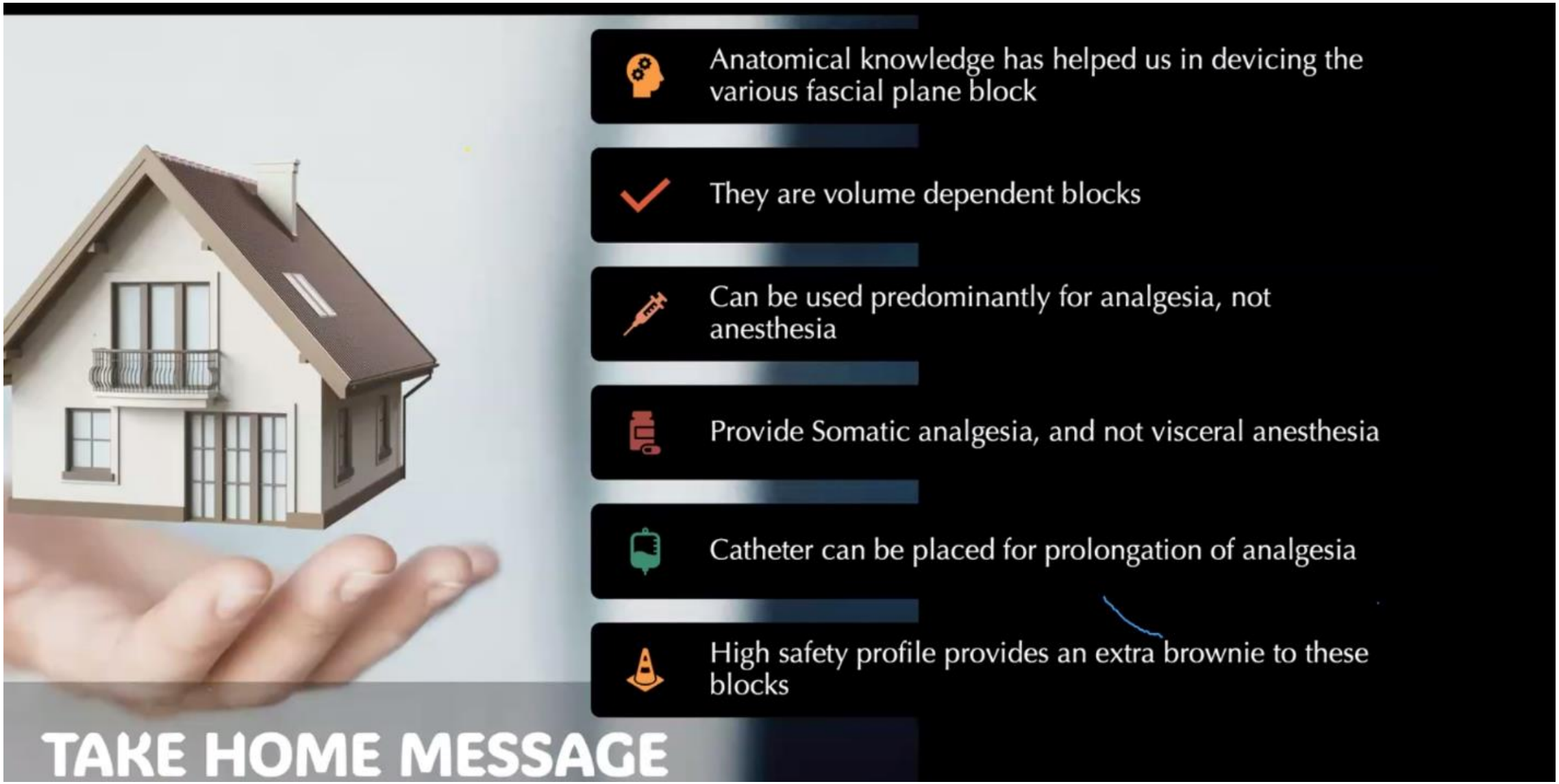
Anatomical knowledge has helped us in devicing the various fascial plane block
They are volume dependent blocks
Can be used predominantly for analgesia, not anesthesia
Provide Somatic analgesia, and not visceral anesthesia
Catheter can be placed for prolongation of analgesia
High safety profile provides an extra brownie to these blocks
TAKE HOME MESSAGE

References

1-Joshi et al. ASA Practice Guideline. Anesthesiology 2026;144:19–43. doi:10.1097/ALN.0000000000005790

2-partyka et al. SABRE trial. JAMA Surg 2024;159:810–817. doi:10.1001/jamasurg.2024.0969

3-Coppens et al. ESP versus intercostal block. Anesthesiology 2025. doi:10.1097/ALN.0000000000005625

4-van de Wijgert et al. ESP after lumbar fusion. doi:10.1213/ANE.0000000000007611

5-Bilgili et al. M-TAPA in major abdominal surgery. 2025. doi:10.4274/TJAR.2025.241752

Image credits

ASRA–ESRA nomenclature consensus, 2021.
doi:10.1136/rapm-2020-102451

ASRA antithrombotic guidelines, fifth edition, 2025.
doi:10.1136/rapm-2024-105766

Randomized evaluation of assistive ultrasound AI, 2024.
doi:10.1136/bmjsit-2024-000264

Clinical image atlas: J Clin Med 2024;13:1104. CC BY 4.0.
https://pmc.ncbi.nlm.nih.gov/articles/PMC10889232/

M-TAPA image: Clin Transplant 2025;39:e70224. CC BY 4.0.
EOI image: PLOS ONE 2026; doi:10.1371/journal.pone.0355377. CC BY 4.0.

Thank You for Your Attention

Questions and Discussion

alikhatibi2002@yahoo.com