18th International Congress of Anesthesiology, Critical Care and Pain

Lung Isolation and One-Lung Ventilation

Dr. Kobra Rafiei Badi
Assistant Professor of Anesthesiology
Shahid Beheshti University of Medical Sciences
Masih Daneshvari Hospital

18–20 November 2026 · Tehran, Iran · From Innovation to Resilience

Learning Objectives

- Define lung isolation and one-lung ventilation (OLV)
- Review historical development and device families
- Compare left/right DLTs and bronchial blockers (BB)
- Select and confirm the device with fiberoptic bronchoscopy (FOB)







Key Terminology and Clinical Objectives

Lung isolation

Separating one lung to prevent blood, pus or secretions from contaminating the contralateral lung

Lung separation

Enabling independent ventilation or different pressure/oxygen delivery to each lung

OLV

Ventilation of one lung while the non-ventilated lung collapses to provide surgical exposure

Goals: protect the healthy lung • improve surgical exposure • control air leak/fistula • provide differential ventilation in selected cases

Historical Overview

- 1930s: early selective bronchial intubation and OLV
- Carlens (1949) and Robertshaw (1960s): DLT development
- Bronchial blockers: lung separation through a single-lumen tube
- Today: FOB is central to confirming device position

Airway Anatomy

- Right main bronchus: shorter, wider, more vertical
- RUL bronchus arises near the carina: key risk with right DLT
- Left main bronchus: longer, usually suits a left DLT

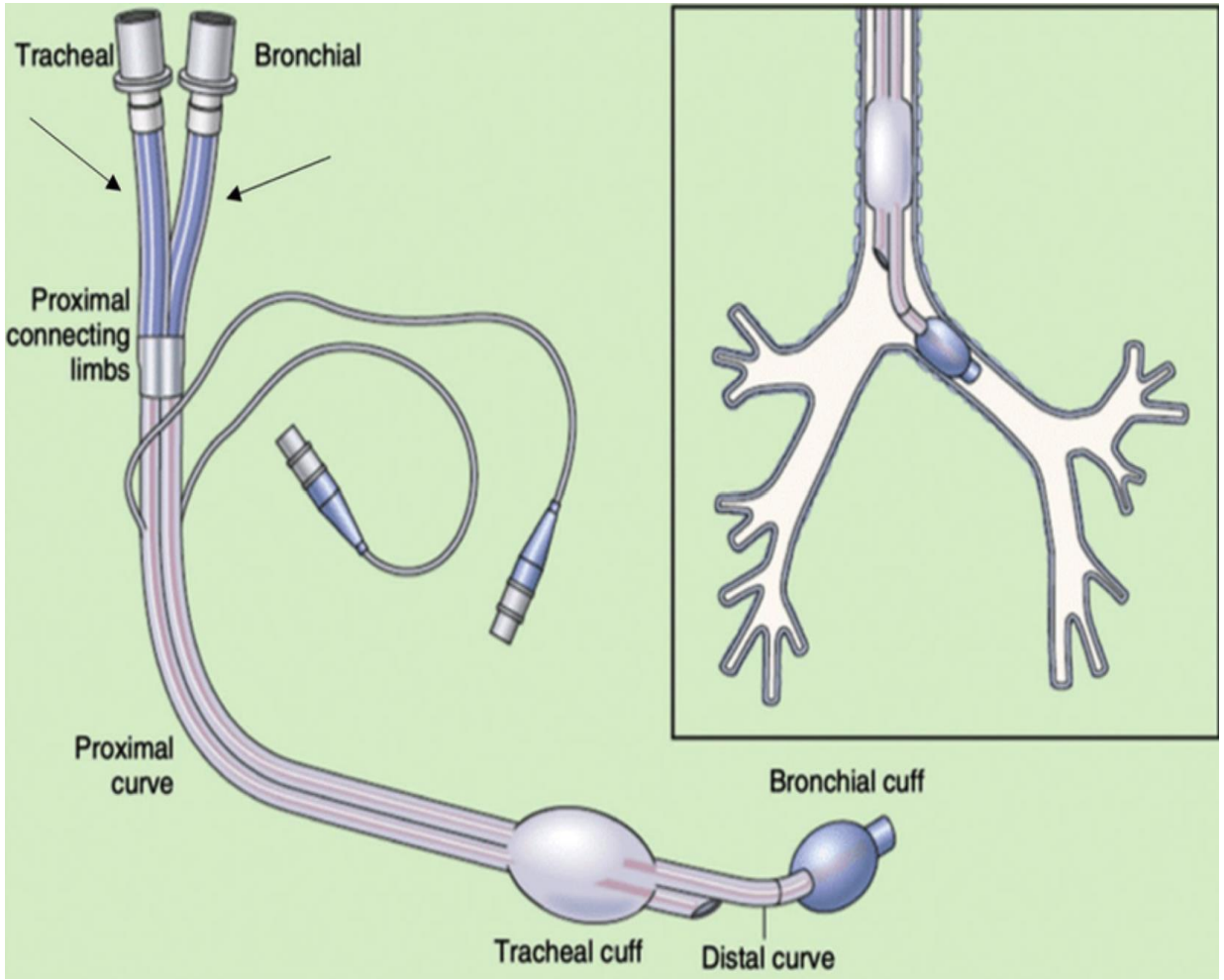

OLV Physiology

- Non-dependent lung collapse increases shunt; HPV response varies
- Oxygenation depends on position, cardiac output, FiO_2, PEEP, VT and disease
- Lung-protective: VT 4–6 mL/kg PBW, limited plateau pressure, individual PEEP
- Hypoxemia: check mechanical causes and device position first

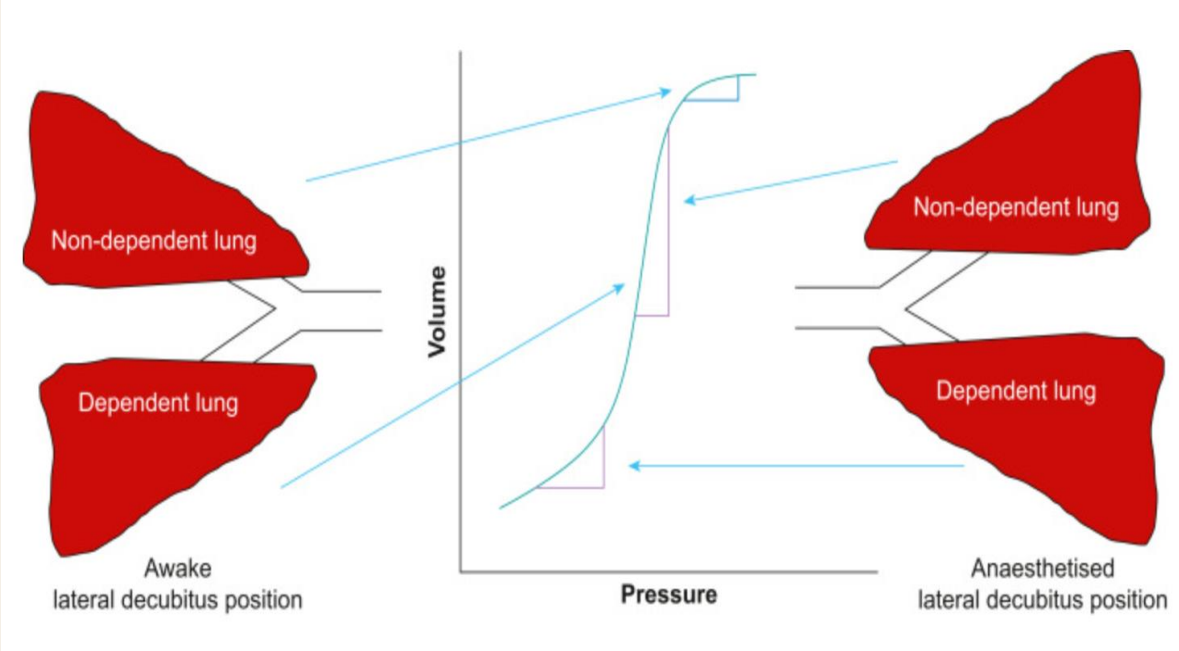

Lung Isolation Device Families

Double-lumen tube (DLT)

Two separate lumens—tracheal and bronchial—allow rapid separation and selective suction/CPAP

Bronchial blocker (BB)

A distal balloon is passed through an SLT; useful in difficult airways and when postoperative ventilation is planned

Single-lumen endobronchial intubation

A temporary/emergency option or an option in children; independent suction is usually more limited

Specialized tubes

For example, Univent: a single-lumen tube with an integrated channel for a blocker

Left-Sided Double-Lumen Tube (DLT)

- Two lumens and two cuffs (bronchial cuff usually blue)
- Bronchial tip in left main bronchus; side opening faces LUL
- Advantages: reliable separation, selective suction, CPAP, quick OLV/TLV switching

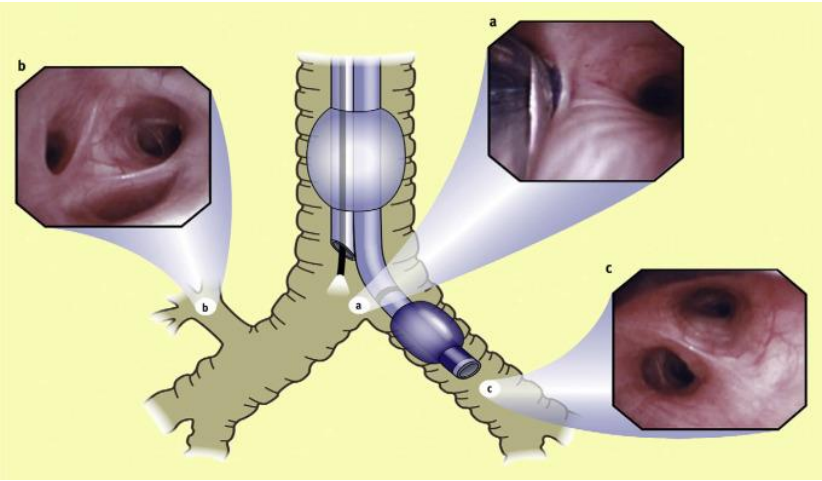

Right-Sided Double-Lumen Tube (DLT)

- Window/slot ventilates the RUL bronchus
- Harder to place; malrotation or wrong depth can obstruct RUL
- Use for left main surgery, left pneumonectomy, or when a left DLT is unsuitable

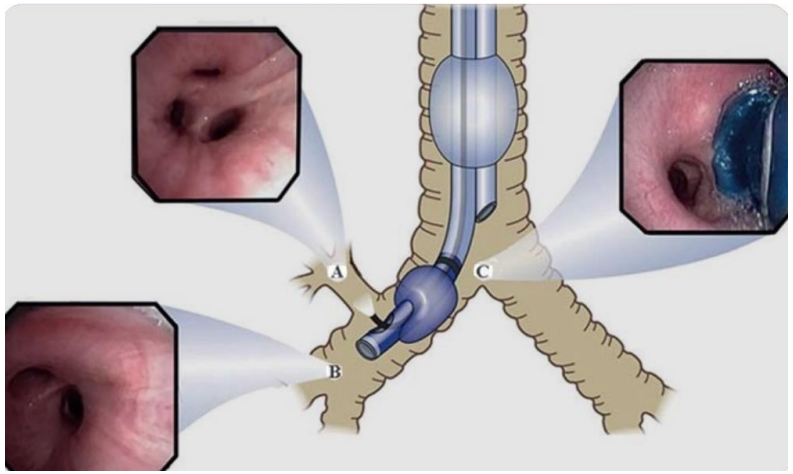

DLT Size Selection

- Height/sex sizing is unreliable; CT of trachea and left main bronchus may help
- Oversized tube: airway injury; undersized: leak and displacement
- Recheck with FOB in the final surgical position

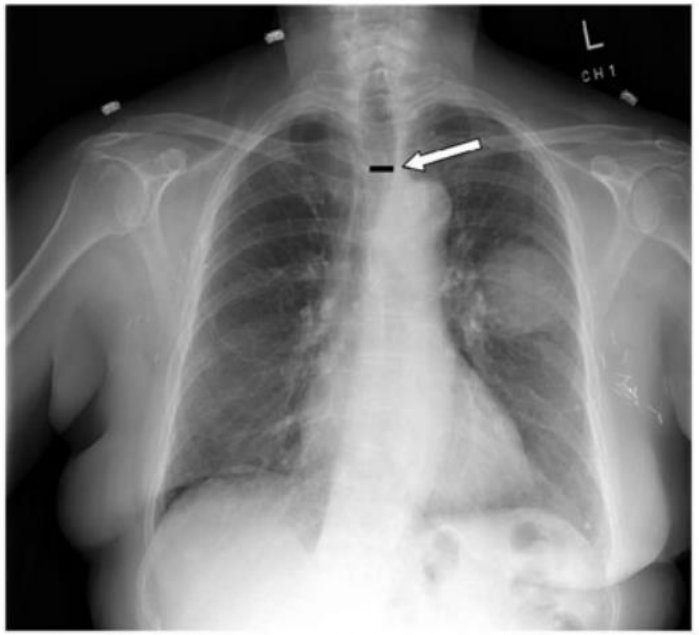

The arrow indicates the level of the clavicles. The black line indicates the width of the trachea.

Left Bronchocath Double-Lumen Endotracheal Tubes Guidelines

Measured Tracheal Width (mm)	Predicted Left Bronchus Width (mm)	Recommended DLT size (F)
≥ 18	≥ 12.2	41
≥ 16	≥ 10.9	39
≥ 15	≥ 10.2	37
≥ 14	≥ 9.5	35

Bronchial Blockers

- Balloon occludes a main or lobar bronchus; passed through an SLT
- Advantages: keeps single-lumen airway, suits difficult airways, no tube exchange
- Limitations: displacement, slower collapse, limited suction, no true differential ventilation

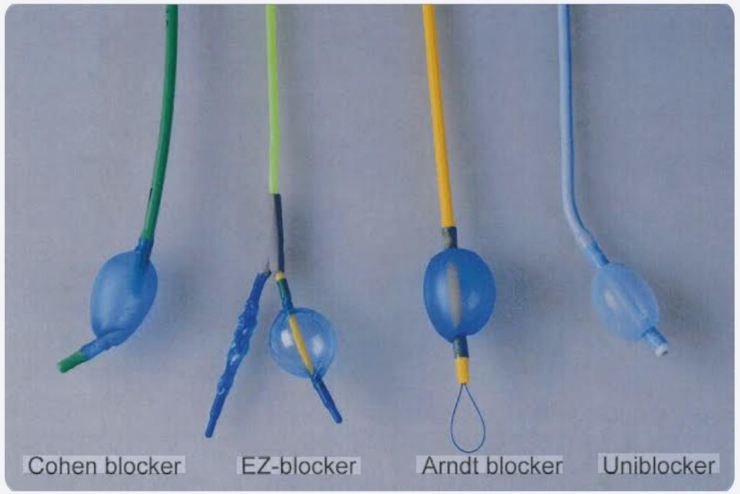

TABLE 16.5. Characteristics of the Arndt® blocker, the Cohen® flexitip endobronchial blocker, and the Fuji Uniblocker®.

	Cohen blocker	Arndt® blocker	Fuji Uniblocker®
Size	9 F	5 F, 7 F, and 9 F	4.5 F, 9 F
Balloon shape	Spherical	Spherical or elliptical	Spherical
Guidance mechanism	Wheel device to deflect the tip	Nylon wire loop that is coupled with the fiberoptic bronchoscope	None, preshaped tip
Smallest recommended *ETT for coaxial use	9 F (8.0 ETT)	5 F (4.5 ETT), 7 F (7.0 ETT), 9 F (8.0 ETT)	4.5 F (4.5 ETT) 9 F (8.0 ETT)
Murphy eye	Present	Present in 9F	Not present
Center channel	1.6-mm internal diameter	1.4-mm internal diameter	2.0-mm internal diameter

Reprinted from Campos [55], with permission
ETT single endotracheal tube

Common Types of Bronchial Blocker

Arndt

Wire-loop/guide-loop: a guiding loop passes around the FOB to steer the blocker



Cohen

Flex-tip: a steerable tip controlled by a rotating mechanism



Uniblocker

Angled/steerable tip; a design independent of the SLT



EZ-Blocker

Y-shaped design; one limb for each main bronchus



Univent

An SLT with an integrated internal blocker channel



Device selection

Depends on SLT internal diameter, FOB diameter, access and operator experience

Bronchial Blocker Placement

- Use an SLT large enough for both blocker and FOB
- Advance FOB to identify carina and target bronchus
- Guide blocker under direct vision; use minimal balloon volume
- Recheck position after patient positioning

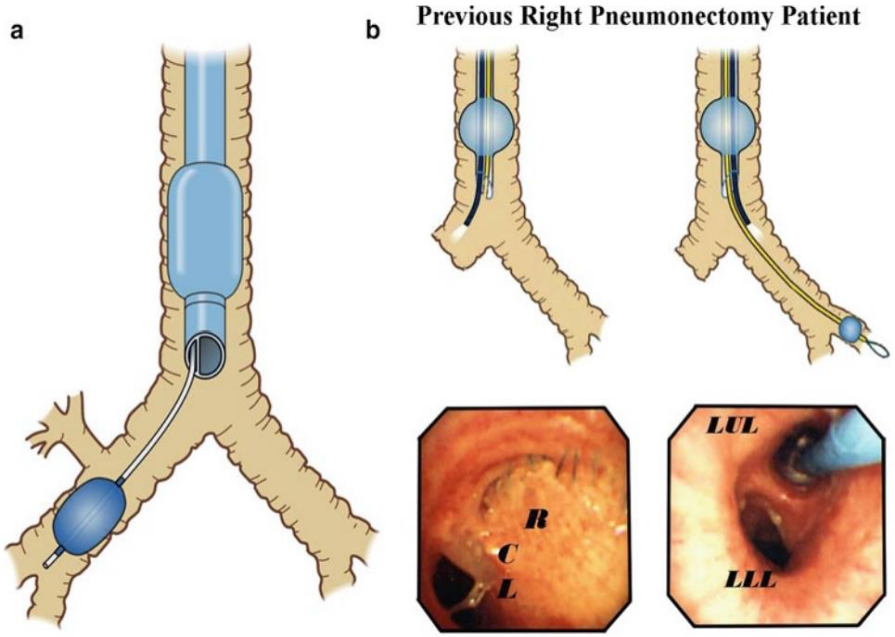



Indications for Lung Isolation

- Protect healthy lung from bleeding, abscess or contamination
- Surgical exposure for lung, esophageal and mediastinal surgery
- Control air leak and provide differential ventilation in selected cases
- Unilateral lavage (e.g., PAP) and other complete-separation needs

Precautions and Limitations | Contraindications

- No absolute contraindication; depends on reserve and surgical need
- Severe hypoxemia, pulmonary hypertension or RV failure: higher risk, needs a rescue plan
- Difficult airway or anatomy, stenosis, tumor: DLT may be unsuitable; BB often preferred in small children

Device Selection | DLT or BB?

DLT Is Generally Preferred

- Routine thoracic surgery in adults
- Need for separate lung suction
- Need for rapid switching between TLV and OLV
- Need for selective CPAP
- Need for reliable separation in unilateral contamination

BB May Be More Suitable

- Difficult airway or an existing SLT
- Postoperative ventilation without exchanging the tube
- Pediatric patient/small airway
- Previous surgery or unusual anatomy
- Need for selective lobar blockade

Difficult Airway | Airway Strategy

- Difficult airway: prioritize oxygenation and airway security
- Common approach: SLT first, then FOB-guided BB
- If a DLT is needed: SLT first, exchange over catheter with careful planning

FOB Confirmation: DLT and BB

- After intubation, FOB through tracheal lumen checks carina and bronchial cuff
- DLT: tip in target bronchus, cuff not over carina, RUL orifice patent (right-sided)
- BB: balloon entirely within target bronchus; check each limb
- Repeat FOB after any position change; auscultation and clamp test are adjuncts only



Hypoxemia During OLV | Stepwise Approach

- Inform surgeon; FiO_2 100%; assess hemodynamics
- Check anesthetic depth, circuit, secretions and tube position with FOB
- Dependent lung: cautious recruitment and individual PEEP
- Persistent hypoxemia: temporarily resume TLV, treat cause, then restart OLV

Complications and Prevention

- Injury: mucosal, bleeding, tracheal/bronchial rupture, laryngeal; more likely with oversized tubes
- Hypoxemia, hypercapnia, high airway pressure, instability
- Prevention: correct sizing, minimal cuff pressure, FOB guidance, secure fixation

Clinical Scenarios for Discussion

Scenario A

Adult undergoing right lobectomy with normal airway: a left-sided DLT is usually the initial choice; confirm with FOB.

Scenario B

Patient with a difficult airway, already secured with an SLT, who requires OLV: an FOB-guided BB is a reasonable option.

Scenario C

Left main bronchial surgery: a right-sided DLT may be required; pay particular attention to the RUL slot.

Scenario D

Massive unilateral bleeding: prioritize protection of the healthy lung and reliable separation; choose a DLT or emergency strategy according to the airway situation.

Key Take-Home Messages

- DLT is standard for many adult procedures; BB is a useful complement
- Choose device by anatomy, goal, airway difficulty and postoperative needs
- Confirm position with FOB; plan a rescue strategy before OLV

References

1. Campos JH. Lung separation and the difficult airway. (Review literature; see current thoracic anesthesia guidance).

2. Lung separation in adult thoracic anesthesia. Saudi Journal of Anaesthesia. 2021;15:272–281. doi:10.4103/sja.sja_100_21. (Open access, CC BY-NC-SA 4.0).

3. Double-lumen tubes and bronchial blockers. BJA Education. 2023;23(11):416–424. doi:10.1016/j.bjae.2023.07.001.

4. Lung Isolation and One-Lung Ventilation. StatPearls [Internet]. NCBI Bookshelf. Updated review.

5. Airway Management in Thoracic Anesthesia: EACTAIC Consensus Document. 2025. PubMed PMID: 41353026.

6. Pasch STM et al. Nuances of perioperative lung isolation and airway management. J Thorac Dis. 2026. doi:10.21037/jtd-2026-1170.

Thank You for Your Attention

