An Invitation to Learn TSSA



Old but Gold

Thoracic Segmental Spinal Anesthesia

Masoud Saberi

Vailati *et al. J Anesth Analg Crit Care* (2025) 5:35
https://doi.org/10.1186/s44158-025-00259-6

2025

Journal of Anesthesia, Analgesia and Critical Care

SIAARTI
PRO VITA CONTRA DOLOREM SEMPER

EDITORIAL Open Access

A bundle for thoracic segmental spinal anaesthesia: it is time to move forward!

Davide Vailati[1*], Benedetta Basta[2], Roberto Starnari[3] and Fabrizio Fattorini[4]

Thoracic segmental spinal anesthesia: rediscovering an "old but gold" regional technique for management of a high-risk patient

Breaking the Taboo: Four Cases of Thoracic Segmental Spinal Anesthesia in Modern Surgical Practice

2026

Paolo Scimia [1], Massimiliano Luca D'Agostino [2], Antonio De Cato [2], Franco Marinangeli [2], Luca Gentili [3]

1. Department of Anesthesia, Intensive Care Unit, Giuseppe Mazzini Hospital, Teramo, ITA 2. Department of Clinical Medicine, Public Health, Life, and Environmental Sciences, University of L'Aquila, L'Aquila, ITA 3. Department of Anesthesia, Intensive Care Unit, Santa Maria Goretti Hospital, Latina, ITA

Thoracic segmental spinal anesthesia

Annual PubMed publications / 2000–2026 / 92 included records

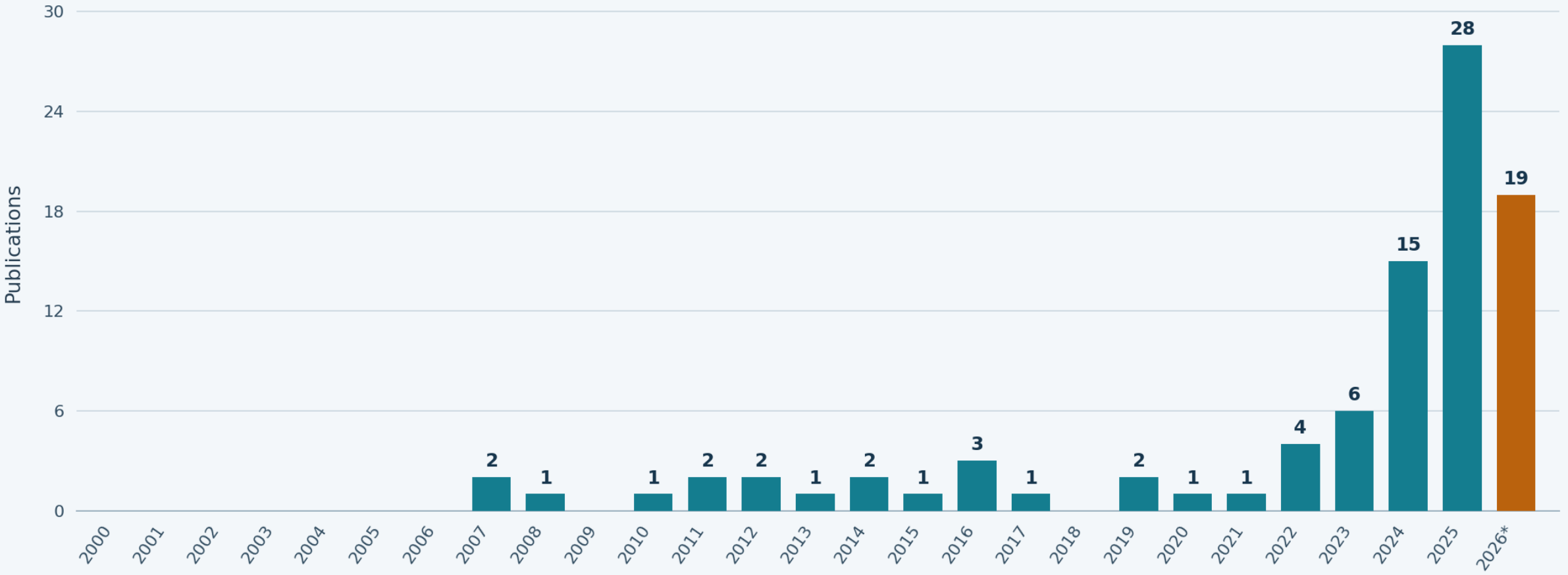

Source: PubMed title/abstract search. Year is based on the earliest online or issue publication date in PubMed.

* 2026 includes records available through 18 November only. Indexing delays may affect recent counts.

First steps

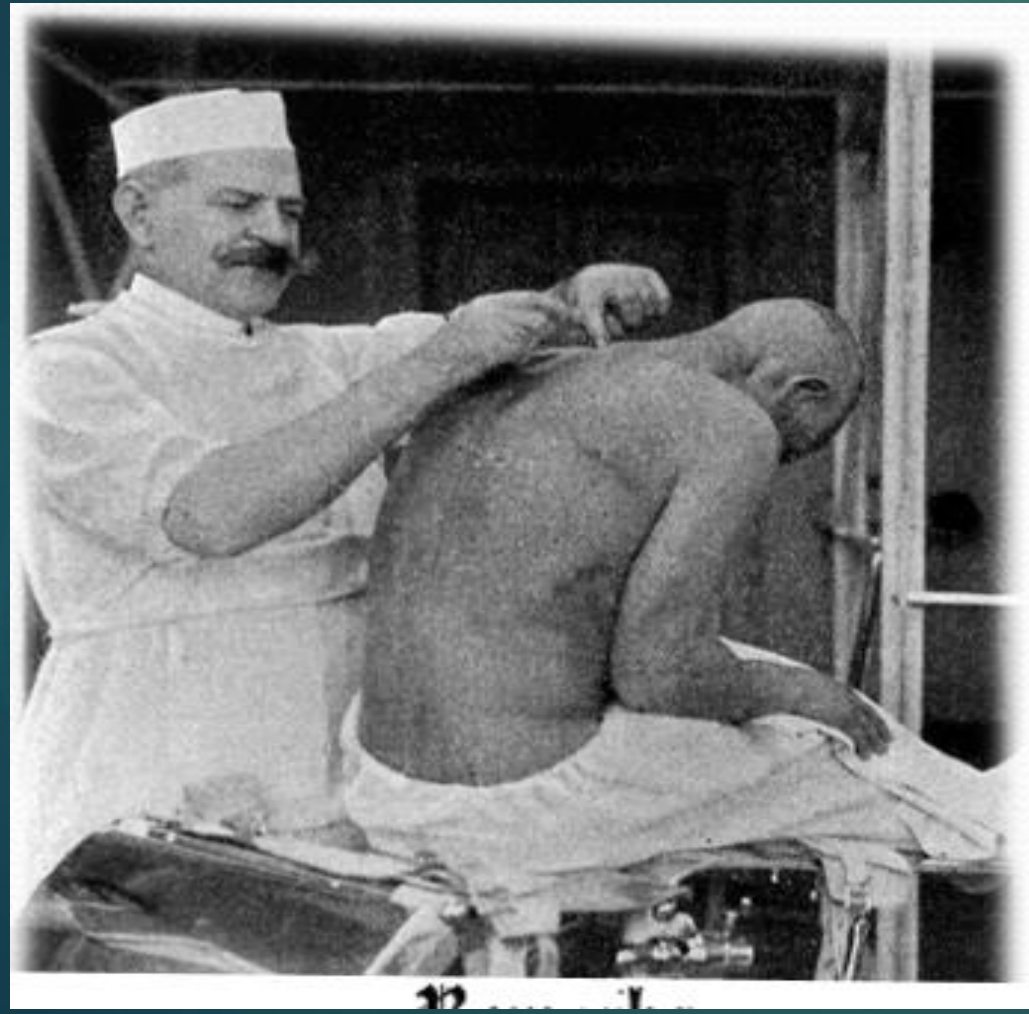

- **In 1909**, ***Thomas Jonnesco*** proposed the use of thoracic spinal block for surgeries of the neck, and thorax.
- He performed punctures between T1 and T2 vertebrae
- ' *I have a total of 1,015 thoracic spinal analgesia all without death and without any serious complication*'

FRACTIONAL SEGMENTAL SPINAL ANESTHESIA IN POOR RISK SURGICAL PATIENTS: REPORT OF 600 CASES •

SEYMOUR BROWN, M.D.†

St. Louis, Missouri

Received for publication September 25, 1951

loaded from http://pubs.asahq.org



- **In 2006, *Andre Van Zundert*** *et al.* proposed segmental spinal block, for lap cholecystectomy in a patient with severe obstructive lung disease, using a low thoracic puncture (T10) for CSE block.

British Journal of Anaesthesia 96 (4): 464–6 (2006)
doi:10.1093/bja/ael036

BJA

Case Report

Segmental spinal anaesthesia for cholecystectomy in a patient with severe lung disease

A. A. J. van Zundert[1]*, G. Stultiens[2], J. J. Jakimowicz[2], B. E. E. M. van den Borne[3], W. G. J. M. van der Ham[1] and J. A. W. Wildsmith[4]

Korean J Anesthesiol 2009 Mar; 56(3): 330-3
DOI: 10.4097/kjae.2009.56.3.330

☐ Case Report ☐

Laparoscopic cholecystectomy performed under regional anesthesia in patient who had undergone pneumonectomy

— A case report —

Department of Anaesthesiology and Pain Medicine, East-West Neo Medical Center, College of Medicine, Kyung Hee University, Seoul, Korea

Jae-Woo Yi, Soo-Eun Choi, and **Jun-Young Chung**

Seventy-one years old, ASA physical status III, male patient underwent laparoscopic cholecystectomy due to acute cholecystitis with gall bladder (GB stone). He had undergone right pneumonectomy nine years ago. Moderate obstructive and restrictive pattern was found on PFT and hypokinesia of apical anterior and septum segments was seen on echocardiography. Due to patient's refusal of receiving general anesthesia, we decided to perform regional anesthesia. Epidural catheter was inserted at 10th thoracic intervertebral space and segmental spinal anesthesia was performed at L2-L3 intervertebral space with 5 mg of hyperbaric bupivacaine 0.5% and 20 ug of fentanyl. A segmental sensory block, extending from T3 through L2 dermatomes, was obtained. Surgery was performed smoothly and uneventfully. Patient discharged from hospital at 3 days after surgery. **(Korean J Anesthesiol 2009; 56: 330~3)**

Where TSSA publications come from

First-author affiliation in PubMed / 2000–18 Nov 2026 / 92 publications

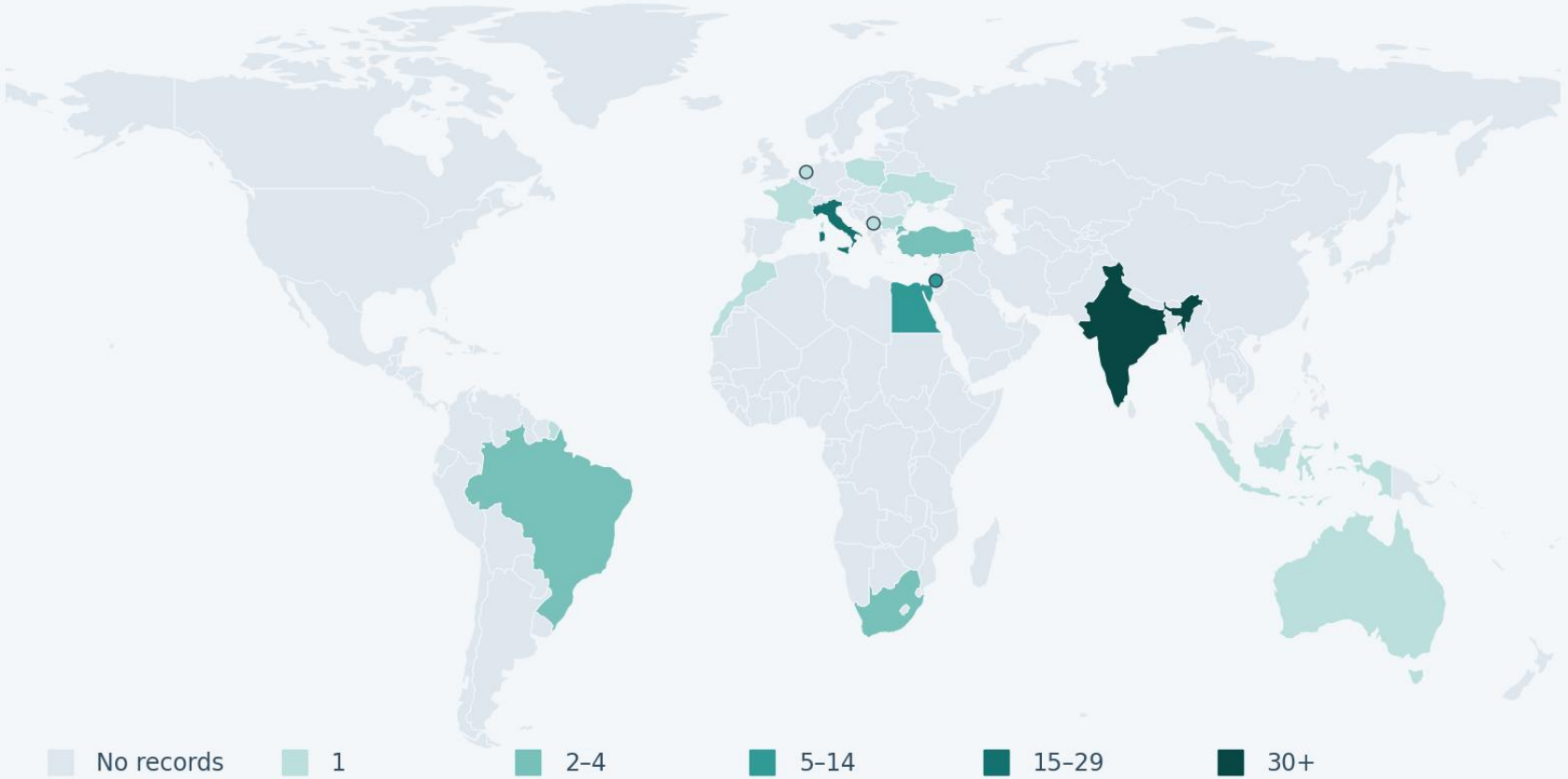

India	42
Italy	16
Palestine	7
Egypt	5
Türkiye	4
Brazil	3
South Africa	2
Australia	1
Bulgaria	1
France	1
Indonesia	1
Kosovo	1
Morocco	1
Netherlands	1
Poland	1
Ukraine	1
Unassigned	4

Affiliation indicates where the first author was based. Study sites may differ, and multinational papers are counted once.

Sources: PubMed affiliation metadata and Natural Earth boundaries.

Fraud



TSSA

ABDOMINAL SURGERY	BREAST & THORACIC	OTHER REPORTED USES
Laparoscopic cholecystectomy	Mastectomy	Percutaneous nephrolithotomy
Open cholecystectomy	Breast-conserving surgery	Nephrectomy
Gastrectomy	Chest wall surgery	Gynecological surgery[1]
Colorectal resection	Thoracotomy	Upper-limb surgery
Exploratory laparotomy	Thoracoscopic surgery	Kyphoplasty
Inguinal / incisional hernia	Lipoma excision	Selected spine surgery

Response to Comments

2025

Thoracic spinal anaesthesia – An effective alternative to general anaesthesia in breast surgeries: A randomised, non-blinded study

Dear Editor

Letters to

2025

Thoracic segmental spinal block as an alternative to general anesthesia in patients with ventricular dysfunction for thoracic spine surgery

2026

Clinical Application and Safety of Intrathecal Adjuvants in Single-Shot Thoracic Segmental Spinal Anesthesia: A Narrative Review

Review began 09/04/2026
Review ended 09/10/2026
Published 09/16/2026

Imran Ahmed Khan [1, 2], Naresh Wamanrao Paliwal [3], Harbhajan S. Saini [4]

Clinical concerns	Adjuvant class	References
Pruritus	Fentanyl and morphine	[11,13,15,70]
Sedation	Buprenorphine, dexmedetomidine, and ketamine	[19,26,37,38,41,59,83]
Bradycardia and hypotension	Dexmedetomidine and clonidine	[16,17,26,37,50,51,76]
Respiratory depression	Fentanyl and morphine	[44,58]
Urinary retention	Fentanyl and morphine	[44,58]



3 FENTANYL | 15–25 µg

Improves visceral analgesia and intraoperative comfort.

⚠ **Risks:** pruritus, respiratory depression, urinary retention.



4 DEXMEDETOMIDINE | 5–10 µg

Prolongs sensory block and delays rescue analgesia.

⚠ **Risks:** bradycardia and hypotension, especially in vulnerable patients.



5 MORPHINE | 100–300 µg

Longer postoperative analgesia.

⚠ **Key concern:** delayed respiratory depression; also nausea, pruritus, urinary retention.



6 CLONIDINE

Prolongs analgesia and reduces opioid requirements.

⚠ Hypotension and prolonged sedation may delay recovery.

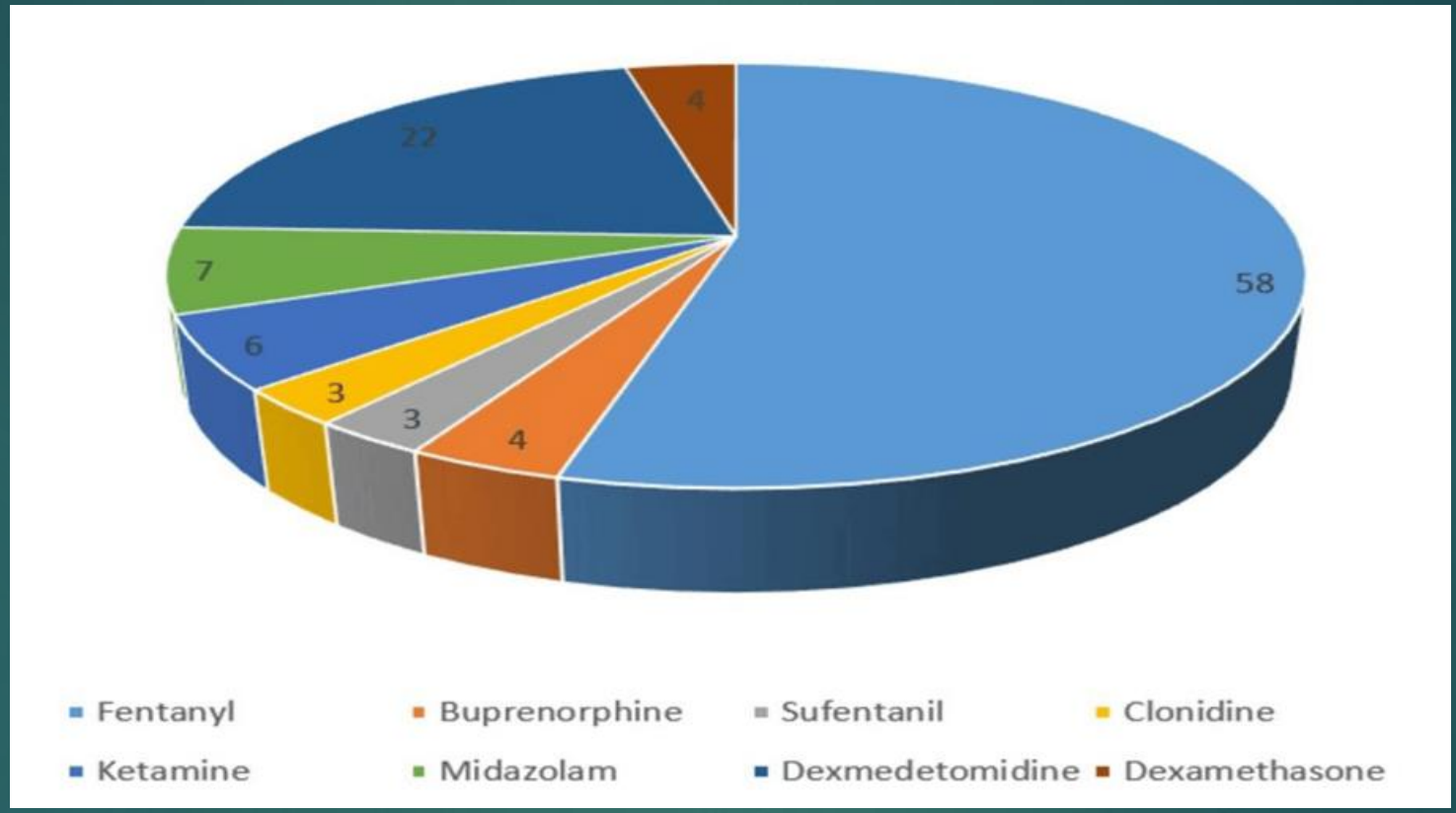
58
22
4
7
6
3
3
4
Fentanyl
Buprenorphine
Sufentanil
Clonidine
Ketamine
Midazolam
Dexmedetomidine
Dexamethasone

Breaking the Taboo: Four Cases of Thoracic Segmental Spinal Anesthesia in Modern Surgical Practice

2026

Paolo Scimia [1], Massimiliano Luca D'Agostino [2], Antonio De Cato [2], Franco Marinangeli [2], Luca Gentili [3]

2 CASE 1: EARLY PREGNANCY



A 29-year-old at 8 weeks + 6 days underwent emergency laparoscopic adnexal detorsion. T10–T11: hyperbaric bupivacaine 5 mg + isobaric ropivacaine 11.25 mg; no intrathecal adjuvant.

4 CASE 3: SEVERE COPD



A 78-year-old with cor pulmonale underwent emergency laparoscopic appendectomy. T9–T10: hyperbaric bupivacaine 5 mg + isobaric ropivacaine 11.25 mg + intrathecal morphine 50 µg.

5 CASE 4: OBESITY AND SLEEP APNEA



A 52-year-old underwent laparoscopic cholecystectomy. T11–T12: hypobaric ropivacaine 5 mg + isobaric ropivacaine 10 mg. Home CPAP was used at 8 cmH_2O.

3 CASE 2: RESTRICTIVE LUNG DISEASE



A 46-year-old with arthrogryposis and rotoscoliosis underwent RIRS. T11–T12: isobaric levobupivacaine 10 mg + intrathecal dexmedetomidine 4 µg, followed by hypobaric levobupivacaine 5 mg.

Breaking the Taboo: Four Cases of Thoracic Segmental Spinal Anesthesia in Modern Surgical Practice

2026

Paolo Scimia [1], Massimiliano Luca D'Agostino [2], Antonio De Cato [2], Franco Marinangeli [2], Luca Gentili [3]

9 EARLY RECOVERY WAS ENCOURAGING



End-of-surgery Bromage score was 0 in all four. QoR-15 scores were 142–148; discharge occurred on postoperative day 2–3. No delayed neurological or respiratory complications were reported at day 30.

8 FAVORABLE INTRAOPERATIVE PHYSIOLOGY



No patient required a vasopressor. Reported $EtCO_2$ was 35–45 mmHg, and SpO_2 ranged from 94% to 99%. No clinically relevant respiratory deterioration was reported.

Journal of Anaesthesia and Pain, 2022, Volume: 3, No.1: 1-4
https://jap.ub.ac.id

2022

P-ISSN : 2722-3167
E-ISSN : 2722-3205

Case Report

Thoracic Spinal Anaesthesia for Modified Radical Mastectomy (MRM)

Derajad Bayu Atmawan[1], Hanifa Agung Kurniawan[1], Priyambada[2]
[1]Departement of Anesthesiology Intensive Therapy and Pain Management, Dr. Soehadi Prijonegoro Hospital, Indonesia
[2]Departement of Oncology Surgery, Dr. Soehadi Prijonegoro Hospital, Indonesia

3 patients

Small case series

Women aged 50, 57 and 74 underwent mastectomy with axillary dissection after neoadjuvant chemotherapy.

T7–T8

Reported spinal technique

Paramedian approach at the intended level. Intrathecal hyperbaric bupivacaine 10 mg plus fentanyl 25 µg.

0 conversions

All three operations completed

Surgery lasted 75–100 minutes. Patients stayed awake. No significant haemodynamic instability was reported.

Feasibility

What the evidence supports

Three cases suggest feasibility. Without a comparison group, relative safety and effectiveness remain unknown.

A Comparison of General anesthesia and segmental thoracic Spinal Anesthesia regarding hemodynamic and respiratory stability for laparoscopic cholecystectomy

Dr Leena Goel[1], Dr Shivam Goel[2], Dr Megha Goel[3]

2022

1 STUDY POPULATION



90 adults aged 18–60, ASA I–II; sealed-envelope allocation:

GA 45 vs TSSA 45.

⚠ Findings apply to selected, relatively healthy elective patients.

2 EXACT TSSA TECHNIQUE



Sitting position; paramedian T10–T11 puncture; 25 G pencil-point needle.

Confirm clear CSF; then supine.

Target sensory block: T4–T12.

3 INTRATHECAL STUDY DOSE



Plain bupivacaine 0.5%, 1 mL (5 mg) + fentanyl 25 µg.

Oxygen 5 L/min; IV midazolam or fentanyl as needed.

⚠ Reported regimen, not a universal dosing recommendation.

4 THE GA COMPARATOR



Propofol + fentanyl + atracurium induction; tracheal intubation, controlled ventilation and sevoflurane maintenance.

A Comparison of General anesthesia and segmental thoracic Spinal Anesthesia regarding hemodynamic and respiratory stability for laparoscopic cholecystectomy

Dr Leena Goel[1], Dr Shivam Goel[2], Dr Megha Goel[3]

2022

6 LOWER HEART RATE AND BP WITH TSSA



At pneumoperitoneum:

- **Pulse: 83.6 vs 116.9/min**
- **Systolic BP: 121.9 vs 153.6 mmHg** (TSSA vs GA).

⚠ Lower values alone do not prove greater haemodynamic stability.

7 SPINAL ADVERSE EVENTS OCCURRED



- TSSA: hypotension 5/45 (11.1%); bradycardia 2/45 (4.4%).
- SpO_2 reportedly remained above 97–98% in both groups.

⚠ This alone does not establish equivalent ventilation.

8 PONV: NUMERICALLY LOWER, NOT SIGNIFICANT



PONV: 5/45 (11.1%) with TSSA vs 12/45 (26.7%) with GA.

⚠ The paper explicitly reports no statistically significant difference.

9 EARLY PAIN BENEFIT; INCONSISTENT TIMING



Table 8 shows lower VAS with TSSA at 1 and 2 hours, but no significant difference at 3–5 hours.

⚠ Methods, table and narrative conflict; a six-hour benefit is not reliably supported.

Challenges in Implementing Thoracic Segmental Spinal Anesthesia in Routine Anesthesia Practice

2025

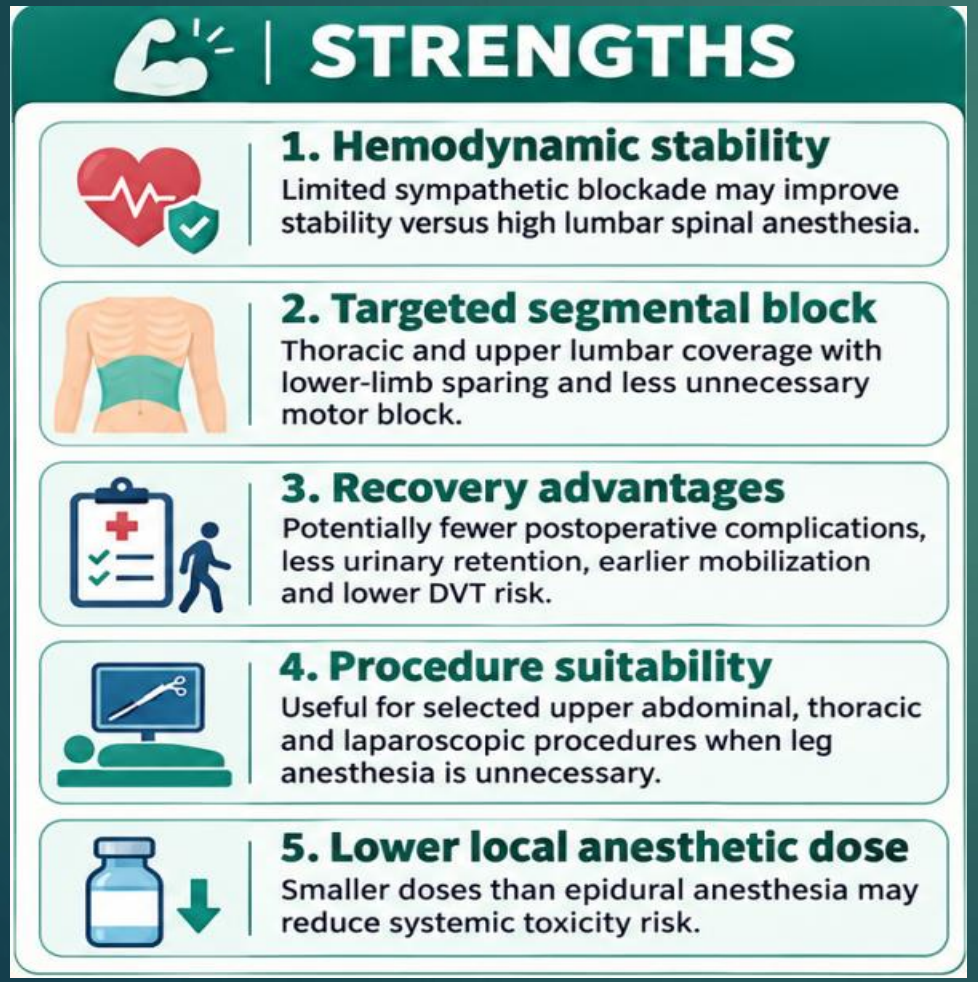

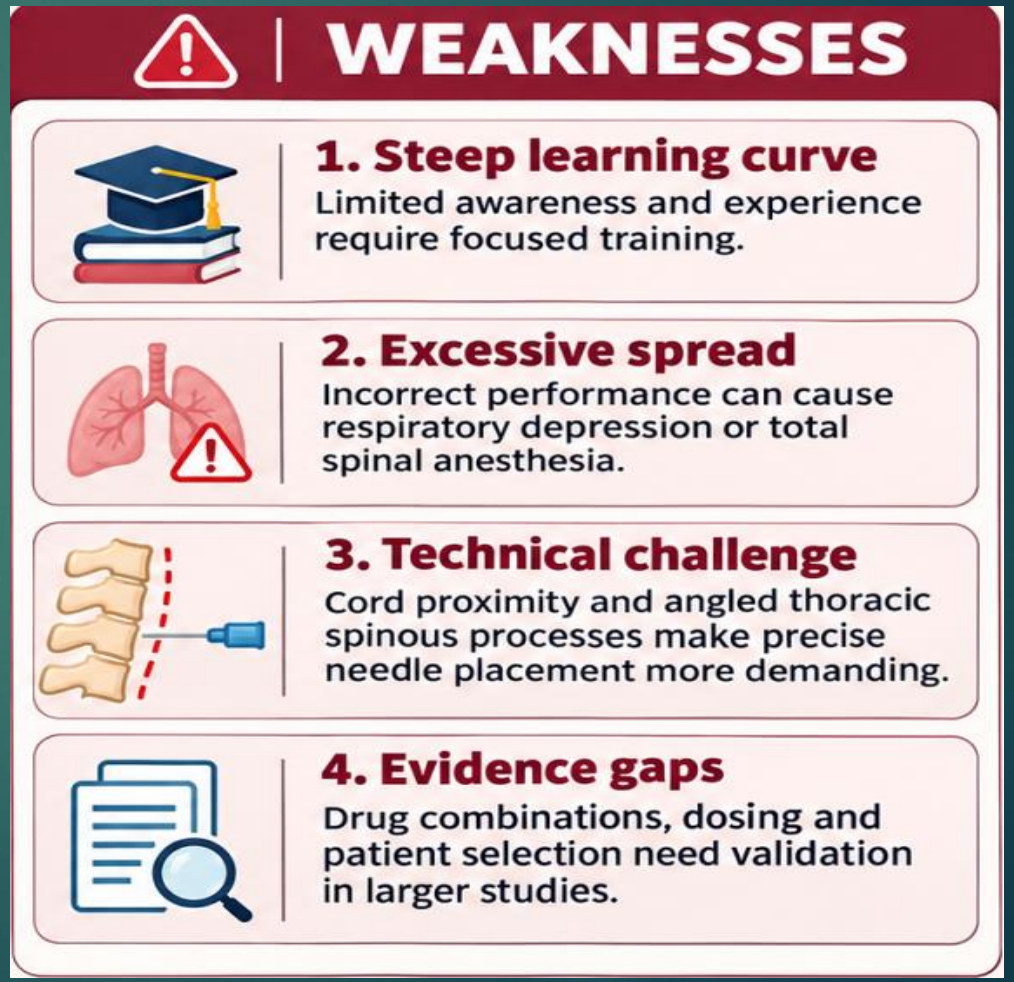

Brief Communication

Challenges in Implementing Thoracic Segmental Spinal Anesthesia in Routine Anesthesia Practice

2025

OPPORTUNITIES



1. Expanding applications

Potential roles in laparoscopic and thoracic surgery and selected high-risk obstetric patients.



2. High-risk patient care

A possible alternative for elderly patients or those with cardiovascular comorbidities; comparative safety needs confirmation.



3. Technology advances

Real-time ultrasound guidance and new needle designs may improve accuracy and safety.



4. Stronger evidence

Further studies can define best practices and support appropriate adoption.



5. Adjunct strategies

Dexmedetomidine, opioids or combined epidural techniques may enhance benefits.

THREATS



1. Preference for established techniques

Preference for general anesthesia or lumbar spinal anesthesia may slow adoption.



2. Serious complications

High spinal anesthesia and direct spinal cord injury may occur and discourage uptake.



3. Training and mentorship gaps

Few structured programs and limited expert mentorship hinder implementation.



4. Resource limitations

Hospitals may lack equipment, expertise or protocols for safe implementation.

HYPERBARIC + SUPINE

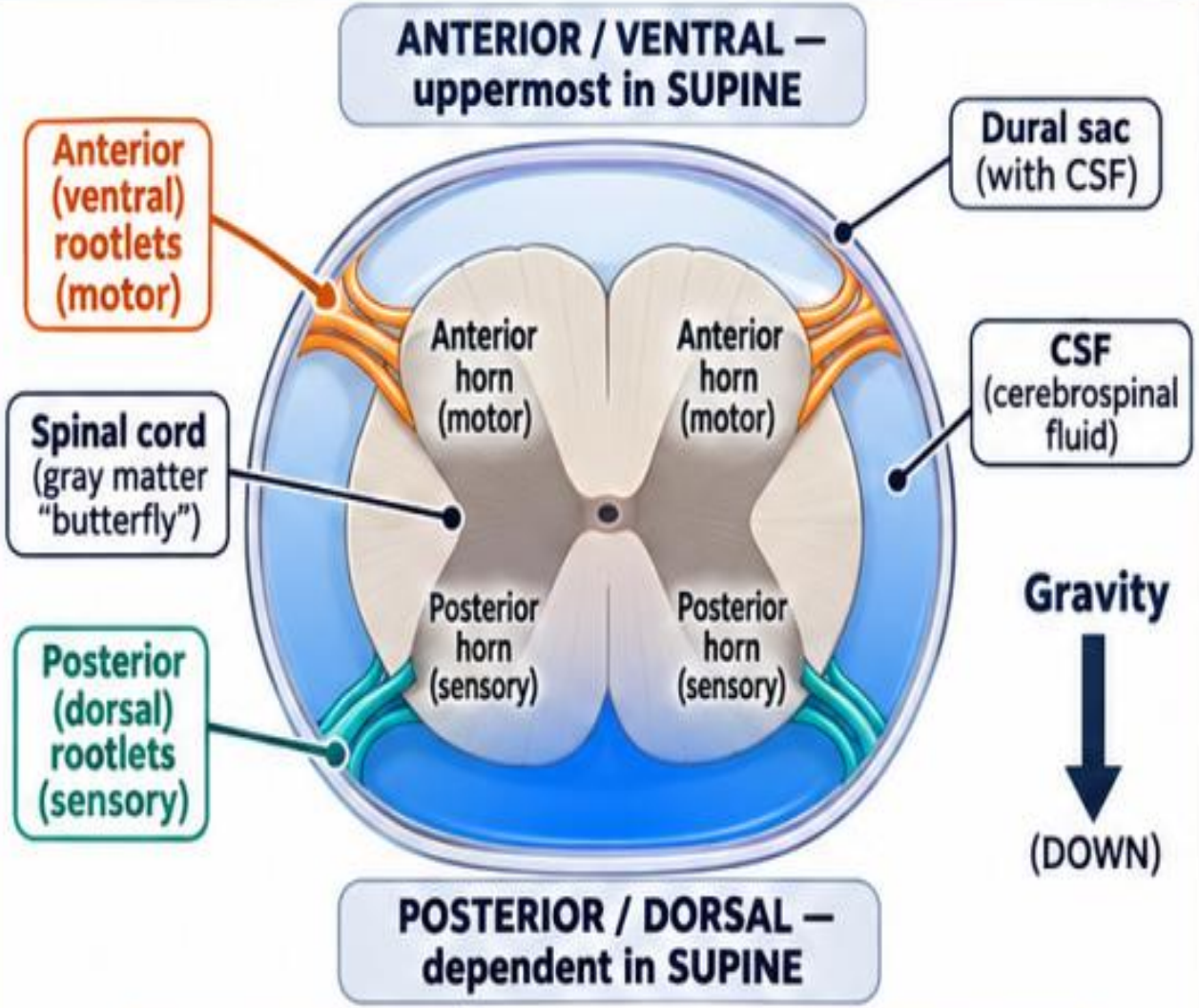

- Tends toward dependent CSF.
- May favor exposure of posterior sensory roots.

HYPOBARIC + SUPINE

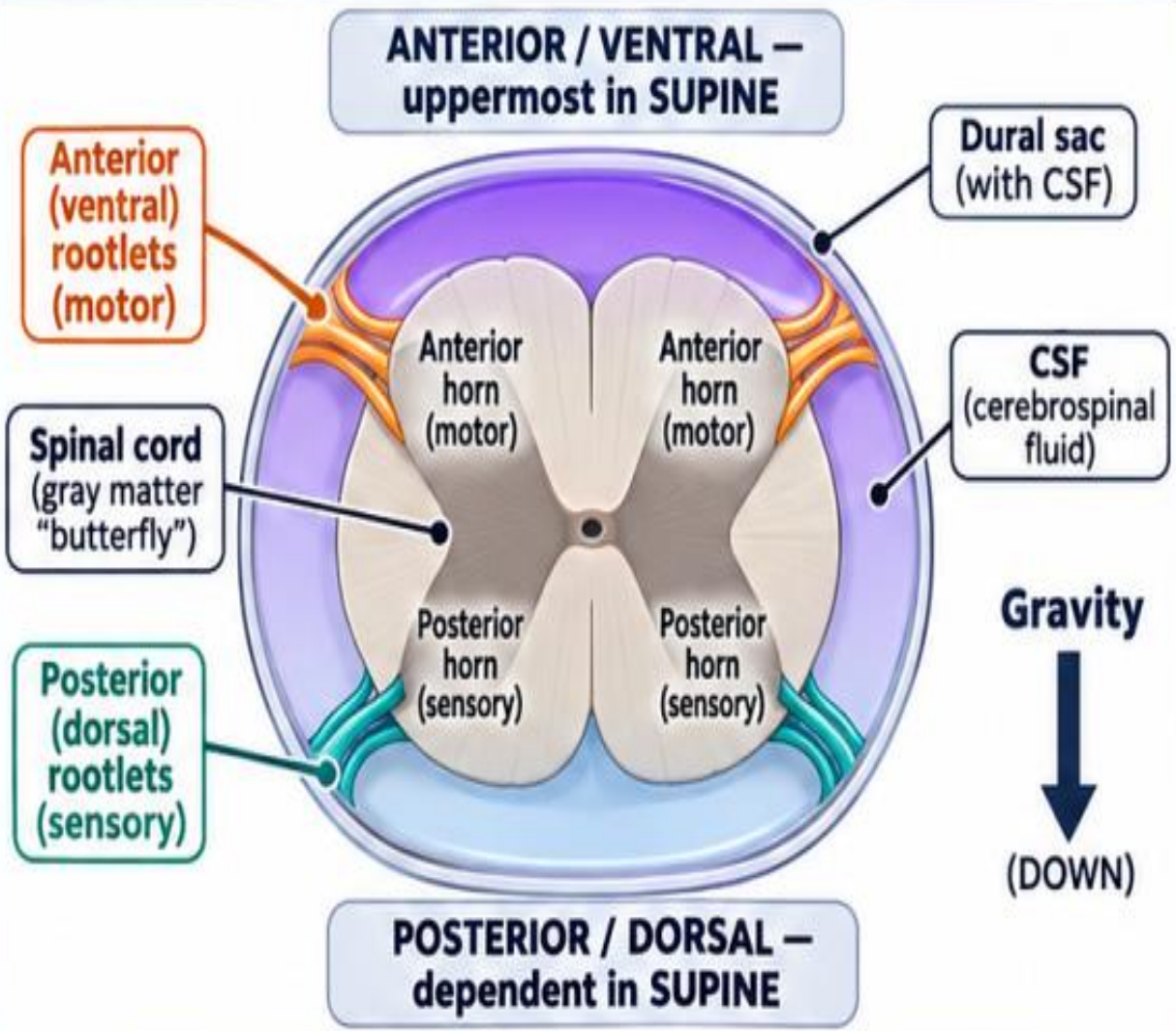

- Tends toward **nondependent** CSF.
- May favor exposure of anterior motor roots.

شواهد مقایسه‌ای نشان داده‌اند که TSSA در بوپیواکائین هیپربار نسبت به ایزوبار می‌تواند بلوک حسی طولانی‌تر و بلوک حرکتی کوتاه‌تری ایجاد کند؛ اما برای مقایسهٔ مستقیم هیپوبار با هیپربار، شواهد کافی در دست نیست

CONTINUOUS THORACIC SPINAL ANESTHESIA

Needles, catheters and insertion levels reported in four articles

CASTELLANI et al. | 2018

Position:	Sitting
Puncture level:	**T10–T11**
Needle:	**21G** Tuohy-shaped spinal needle
System:	Spinolong / Temena
Intrathecal catheter:	**24G**
Advancement:	3–4 cm beyond needle tip after free CSF flow
DOI:	10.1177/1756287218795427



VINCENZI et al. | 2020

Position:	Sitting or lateral decubitus
Puncture level:	**Between T6 and T12,** according to surgery
Needle:	**21G** Tuohy-shaped spinal needle
System:	Spinolong / Temena
Intrathecal catheter:	**24G**
Advancement:	3–4 cm beyond needle tip after free CSF flow
DOI:	10.1016/j.sopen.2020.07.002



SANGADALA et al. | 2024

Position:	Sitting, then supine
Puncture level:	**T10–T11**
Needle:	**21G** Sprotte-tip spinal needle
System:	Pajunk
Intrathecal catheter:	**25G**
Advancement:	3–5 cm beyond needle tip after free CSF flow
DOI:	10.4103/ija.ija_729_23



THAKURIA et al. | 2024 VERIFIED FOR CASE 1 ONLY

Position:	Sitting, then supine
Puncture level:	**T10–T11**
Needle:	**21G** Sprotte-tip needle
System:	Pajunk IntraLong
Intrathecal catheter:	**25G**
Advancement:	4–5 cm within the subarachnoid space
	Case 2 equipment details not verified
DOI:	10.1213/XAA.0000000000001862



Insertion level ≠ final catheter tip level. Threaded length is not skin-to-tip depth.

Not specified in verified methods passages: insertion angle, midline versus paramedian approach, imaging-confirmed final tip level.

Reported study methods, not a standardized procedural protocol • G = gauge • CSF = cerebrospinal fluid

BJA

British Journal of Anaesthesia, 130 (1): e56—e65 (2023)

doi: 10.1016/j.bja.2022.03.008
Advance Access Publication Date: 4 April 2022
Review Article

THORACIC ANAESTHESIA AND RESPIRATION

Defining the role of thoracic spinal anaesthesia in the 21st century: a narrative review

Johannes J. le Roux*, Koji Wakabayashi and Zainub Jooma

Department of Anaesthesia, Faculty of Health Sciences, School of Clinical Medicine, University of the Witwatersrand, Johannesburg, South Africa

Editor's key points

- Thoracic spinal anaesthesia is an unorthodox technique infrequently used because of fear of spinal cord injury, cephalad spread of the block, and haemodynamic instability.
- In this narrative review, the authors describe the effectiveness and safety of thoracic spinal anaesthesia where a general anaesthetic poses a high risk in a variety of surgical procedures.
- Further well-designed randomised trials will be needed if the clinical utility of this practice is to be established.

1 A SELECTIVE ALTERNATIVE

The main rationale is to avoid general anaesthesia-related complications in carefully selected high-risk patients—**not to replace GA routinely.**

2 EVIDENCE REMAINS LIMITED

Search through October 2021: 35 publications included—15 original articles, 11 case reports, 4 reviews and 5 letters. **This is a narrative review, not a meta-analysis.**

3 MATCH THE PATIENT AND PROCEDURE

Reported uses include abdominal, breast, urological and lower-limb surgery. Potential candidates include frail older adults and patients with severe pulmonary disease or multiple comorbidities.

4 POTENTIAL RECOVERY BENEFITS

Selected comparisons suggest lower local anaesthetic requirements, less hypotension than conventional lumbar spinal, shorter motor block and earlier mobilisation. **These benefits are not established across all patients.**

5 ANATOMY HELPS, BUT DOES NOT GUARANTEE SAFETY

MRI studies show the widest posterior dura-to-cord separation near T5–T6. Measurements vary substantially; **spinal cord injury remains a central concern.**

6 EXPERTISE AND LEVEL CONFIRMATION MATTER

The authors advise ultrasound to confirm vertebral level and assess anatomy. TSSA should be performed by clinicians proficient in lumbar spinal and thoracic epidural techniques.

7 LOW VOLUME; NO UNIVERSAL REGIMEN

Bupivacaine, levobupivacaine and ropivacaine were reported, with varying baricity and adjuvants. Mean local anaesthetic volume was 1.8 mL across 1,327 reported cases; **volume alone does not define dose.**

8 PLAN FOR THE DURATION

Single-shot block may be too short for prolonged surgery. Continuous intrathecal or combined spinal–epidural techniques allow extension; continuous cases lasted up to 191 minutes in cited reports.

9 COMPLICATIONS STILL OCCUR

Reported paresthesia: 4–10%; bradycardia: up to 20%. One trial reported hypotension in 28.5%. **These are study-specific figures, not pooled rates.** Laparoscopic shoulder pain may require additional analgesia.

10 ABSENCE OF REPORTED HARM IS NOT PROOF

No permanent neurological injury or complete spinal block was identified in the included TSA literature. **Rare harm cannot be excluded; larger, well-designed randomised trials are needed before routine use.**

Hypobaric TSSA

1 SMALL, SELECTED CASE SERIES

Retrospective analysis of prospectively collected data; 9 elective cases in 2022. Mean age **75.7** years; **7/9** patients were **ASA III**. No control group.

2 THORACIC PUNCTURE

Sitting position; **T8–T9** interspace; midline or paramedian approach; **25 G** Whitacre needle. Clear CSF flow confirmed before injection.

3 OPIOID-FREE INTRATHECAL ADJUVANTS

Preservative-free midazolam **0.03 mg/kg** + preservative-free ketamine **0.3 mg/kg** were administered intrathecally.

⚠ *Experimental study regimen—not an established routine protocol.*

4 TWO ROPIVACAINE COMPONENTS



First: hypobaric ropivacaine **0.25%, 2 mL (5 mg)**, prepared using distilled water.
Then: saline-diluted ropivacaine **0.25%, 4 mL (10 mg)**, described as isobaric.
Total ropivacaine: **15 mg**.

5 HEAD-UP POSITIONING WAS CENTRAL



Initially **5°** head-up; increased to **20°** with slight left rotation after insufflation. Authors targeted sensory coverage from **C3–C4** to **T11–T12**.

⚠ *Reported high sensory target; requires particular caution.*

6 LOW-PRESSURE PNEUMOPERITONEUM



CO_2 pressure **8–10 mmHg**. All patients breathed spontaneously with supplemental oxygen. No patient required mechanical ventilation.

7 ALL NINE COMPLETED SURGERY



GA conversion: **0/9.** Intraoperative shoulder pain and abdominal discomfort: **0/9.** Mean operative time: **37.5 min;** mean sensory block duration: **145.2 min.**

8 HYPOTENSION WAS FREQUENT



4/9 (44.4%) developed hypotension and received ephedrine. Anxiety in **2/9** required IV ketamine and/or midazolam.
Opioid-free did not mean free of systemic medication.

9 RECOVERY WAS GENERALLY FAVOURABLE



No PONV, urinary retention or neurological complications were reported. **5/9** needed non-opioid rescue analgesia. Median stay: **2 days**; high patient satisfaction: **8/9.**

10 HYPOTHESIS-GENERATING, NOT PROOF



Nine uncontrolled cases cannot establish rare-event safety or superiority over GA. The separate effects of hypobaricity, adjuvants, positioning and low insufflation pressure cannot be determined.

Thoracic Spinal Anesthesia for Laparoscopic Cholecystectomy: An Observational Feasibility Study

Richa Chandra [1] , Gaurav Misra [2] , Gopal Datta [3]

1. Anaesthesiology, Subharti Medical College , Meerut, Bareilly, IND 2. Anesthesia, Shri Ram Murti Smarak Institute of Medical Sciences (SRMS IMS), Bareilly, IND 3. Laparoscopic Surgery, GD Hospital, Bareilly, IND

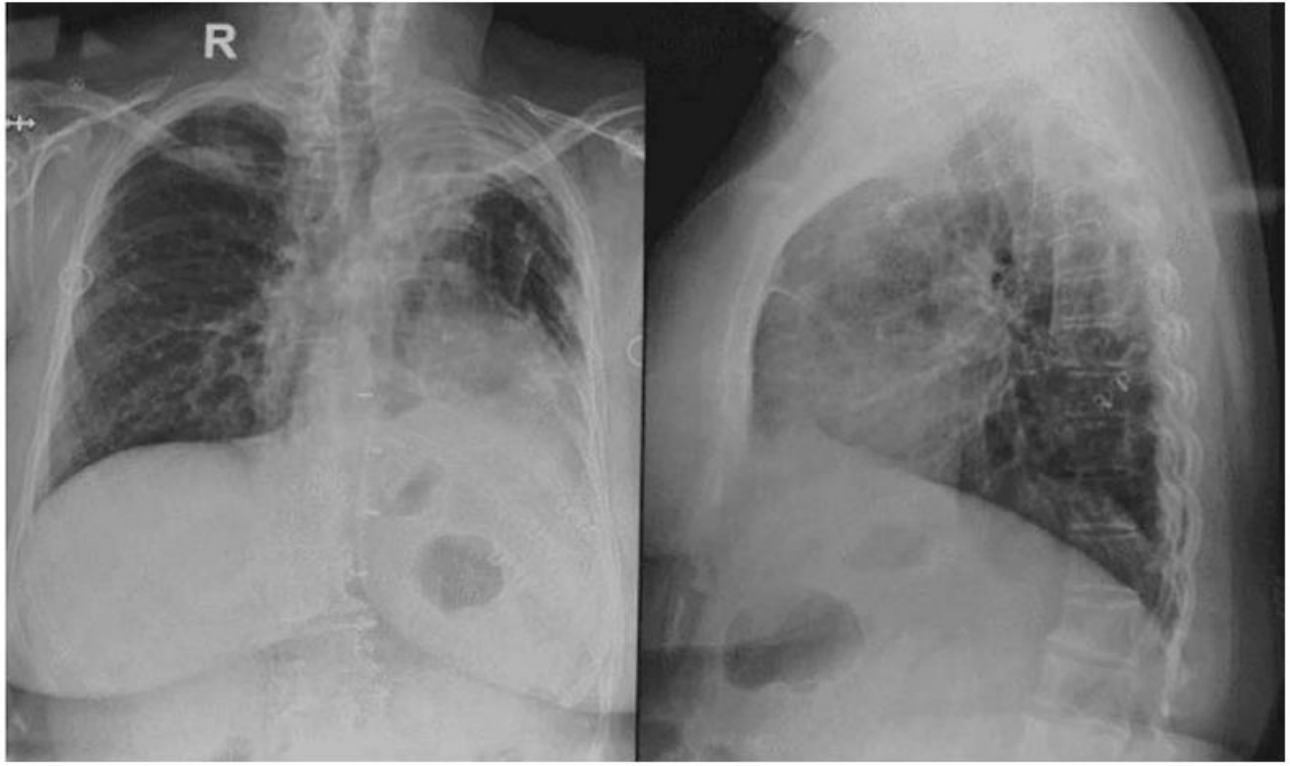

CASE REPORT

Thoracic Continuous Spinal Anesthesia in Patients With Destroyed Lung Resulted in Favorable Perioperative Outcome

2024

Ruma Thakuria, MD, Arun Jagath A. S., MD, Gourav Kumar, MD, and Praveen Talawar, MD

Among patients needing open abdominal surgery, those with high-risk medical conditions impose significant challenges from an anesthesia point of view. Thoracic continuous spinal anesthesia (TCSA) is an evolving technique that may be beneficial for a subset of patients with underlying high-risk medical conditions where general anesthesia (GA) becomes a relative contraindication. TCSA, as a primary anesthesia technique, is gaining favor for its advantages over GA in open abdominal surgery as it avoids airway intervention and mechanical ventilation. The current article focuses on TCSA in 2 patients at high risk for GA, which resulted in favorable perioperative outcomes. (A&A Practice. 2024;18:e01862.)

TSSA with Regional Block

DOI: 10.21088/ijaa.2349.8471.13226.1

2026

Indian Journal of Anesthesia and Analgesia
Volume 13 Number 2 April - June 2026

LETTER TO THE EDITOR

Successful Anesthetic Management using Segmental Spinal and Erector Spinae Plane Block in a High-Risk Patient with Severe Cardiac and Pulmonary Comorbidities Undergoing PCNL

2026

CASE REPORT

Segmental Spinal Anesthesia With Fascial Plane Block for Cesarean Delivery in Severe Mitral Stenosis: A Case Report

Mukesh K. Prasad, MD,[1] Tripta Kumari, MD,[1] and Kanchan Rani, MS[2]

TSSA with regional anesthesia

TSSA + ERECTOR SPINAE PLANE BLOCK

Deshpande et al. (2023)
Modified radical mastectomy + axillary dissection
T5–T6 TSSA + unilateral T5 ESPB
Prospective cohort, n = 40. Rescue analgesia in 11/40 within 24 h.
doi:10.22159/ajpcr.2023.v16i6.48397

Karthik et al. (2025)
Thoracoscopy for pleural drainage and biopsy
T5–T6 TSSA + T7 ESPB
Case series, n = 3. All maintained spontaneous ventilation.
doi:10.4103/sja.sja_378_24

Paul & Borkar (2023)
Unilateral gynecomastia surgery
TSSA for surgical anaesthesia + ESPB for analgesia
Case report of a 24-year-old man.
doi:10.7759/cureus.47502

Punekar et al. (2026)
Modified radical mastectomy + axillary dissection
T4–T5 TSSA + ipsilateral T4 ESPB
Case report. Stable haemodynamics during a 2-hour operation.
doi:10.31893/multiscience.2026059

TSSA + INTERMEDIATE CERVICAL PLEXUS BLOCK

Yılmaz & Bozok (2025)
Awake laparoscopic cholecystectomy
T7–T8 TSSA + intermediate cervical plexus block
Case series. The neck block targeted referred shoulder pain during pneumoperitoneum.
doi:10.20528/cjpm.2025.02.005

Forasassi et al. (2024)
Awake robot-assisted laparoscopic prostatectomy
T9 TSSA + intermediate cervical plexus block
Case report. Sacral ESPB was added at the end of surgery for postoperative analgesia.
doi:10.29011/2574-7754.102039

Why add a block?

ESPB supplemented chest wall or postoperative analgesia.

The cervical plexus block targeted referred shoulder pain during laparoscopy.

ORIGINAL ARTICLE | ASIAN JOURNAL OF MEDICAL SCIENCES

Evaluation of segmental thoracic spinal anesthesia for laparoscopic cholecystectomy: Perioperative hemodynamic, analgesic, and recovery outcomes

2026

Abhishek Bhaskar[1], Arvind Kumar[2], Sanjay Kumar[3], Pankaj Singh Patel[4], Shefali Anand[5]

[1]Assistant Professor, [2]Associate Professor, Department of Anesthesia, Autonomous State, Medical College Kaushambi, [3]Assistant Professor, Department of Surgery, [4]Assistant Professor, Department of Anesthesia, [5]Assistant Professor, Department of Paediatrics, Rani Durgavati Medical College, Banda, Uttar Pradesh, India

Prospective observational study | 50 adults | ASA I–II | Single center

1 100% COMPLETION



50/50 operations completed without conversion to general anesthesia.

2 STUDY SPINAL REGIMEN



T10–T11: 1.5 mL of 0.75% isobaric ropivacaine (11.25 mg). Study protocol, not an optimal-dose recommendation.

3 RAPID BLOCK ONSET



Adequate sensory block: 5 ± 2 min.
Mean surgery duration: 60 ± 18 min.

4 IV ADJUNCTS WERE USED



Fentanyl 50 µg + midazolam 1 mg; ketamine 30 mg at insufflation. Additional analgesia reported in 16%.

5 HEMODYNAMIC EVENTS



Bradycardia: 14% (7/50).
Hypotension: 4% (2/50).
Continuous monitoring remains essential.

6 SHOULDER DISCOMFORT



Intraoperative: 16%.
Postoperative: 6%.
Pneumoperitoneum pressure approximately 12 mmHg.

7 RESPIRATORY & NEUROLOGICAL FINDINGS



Transient desaturation: 2%.
No major respiratory or neurological events observed; rare harms cannot be excluded.

8 LOW POSTOPERATIVE PAIN



Mean VAS: 1.2/10 at 3 h; 0.9/10 at 24 h.
First rescue analgesia: 300 ± 85 min.

Thoracic segmental spinal anesthesia: rediscovering an "old but gold" regional technique for management of a high-risk patient

1 EXTREME COMORBIDITY BURDEN



A 64-year-old man had obesity (BMI 41.4), diabetes, coronary bypass surgery, prior TAVI, dialysis-dependent renal failure, and COPD requiring nocturnal CPAP.

2 MAJOR EMERGENCY ABDOMINAL SURGERY



Perforated colonic diverticulosis with diffuse peritonitis and sepsis required an urgent open Hartmann procedure. Surgery lasted 2 hours 35 minutes.

4 REPORTED INTRATHECAL REGIMEN



T9–T10 puncture: hyperbaric bupivacaine 5 mg, levobupivacaine 10 mg (reported concentration 0.27%), morphine 70 µg, and dexmedetomidine 10 µg.

Case-specific doses; not a validated protocol.

5 STABILITY REQUIRED VASOPRESSOR SUPPORT



Norepinephrine began immediately after the block at 0.15 µg/kg/min, then was titrated to 0.1 µg/kg/min. The authors aimed to limit fluid loading in renal failure.

6 SPONTANEOUS BREATHING WAS PRESERVED



The patient remained on his own CPAP, awake and cooperative, without reported respiratory compromise. Two IV fentanyl boluses of 50 µg each were still required.

7 ANALGESIA WAS MULTIMODAL



IV paracetamol 1 g plus bilateral rectus sheath and TAP blocks were given at the end of surgery. Fascial blocks used 60 mL of 0.25% levobupivacaine in total (150 mg).

8 EARLY RECOVERY WAS FAVORABLE



At postoperative ICU transfer, pain NRS was 2 and Bromage score was 0. No hemodynamic or respiratory complications were reported. Continuous ICU monitoring was used.

Thoracic Spinal Anesthesia for Laparoscopic Cholecystectomy: An Observational Feasibility Study

Richa Chandra [1] , Gaurav Misra [2] , Gopal Datta [3]

1. Anaesthesiology, Subharti Medical College , Meerut, Bareilly, IND 2. Anesthesia, Shri Ram Murti Smarak Institute of Medical Sciences (SRMS IMS), Bareilly, IND 3. Laparoscopic Surgery, GD Hospital, Bareilly, IND

All other patients were given subarachnoid block at T10-T11 intervertebral space with 26G Quincke needle and Inj. Bupivacaine Heavy (0.5%) 2.4 mL with 5µg of Dexmedetomidine.

Material and methods: The prospective observational study was conducted from April 2020 to March 2022, 2.146 patients with symptoms of cholelithiasis and planned for laparoscopic cholecystectomy were included in this study, and 44 patients from this study were excluded due to pre-defined exclusion criteria. The patients belonging to ASA lIl, lV, severe cardiovascular or renal disability, on beta blockers, coagulation anomaly, spinal deformities, or previous spine surgeries were not included in the study. The patients exhibiting allergy to local anesthetics, requiring more than two attempts for the procedure, patchy or inadequate effects after spinal anesthesia, or change in the plan of surgery intraoperatively were also excluded from the study. All other patients were given subarachnoid block at T10-T11 intervertebral space with 26G Quincke needle and Inj. Bupivacaine Heavy (0.5%) 2.4 mL with 5µg of Dexmedetomidine. Intraoperative parameters, number of attempts, the incidence of paresthesia during the procedure intraoperative and postoperative complications, and patient satisfaction were evaluated and recorded.

Original Article

Segmental thoracic spinal anesthesia versus general anesthesia for breast cancer surgery: A prospective randomized-controlled open-label trial

Naveen Paliwal, Neetu Maurya, Om Prakash Suthar[1], Sarita Janweja

Department of Anesthesiology and Critical Care, Dr. S. N. Medical College, Jodhpur, Rajasthan, India, [1]Department of Anesthesiology, Government Medical College, Pali, Rajasthan, India

Conclusion: Segmental thoracic spinal anesthesia technique provides better satisfaction with superior postoperative analgesia and fewer complications in patients undergoing breast cancer surgery compared to GA.

Prima *et al.*
Ain-Shams Journal of Anesthesiology (2023) 15:72
https://doi.org/10.1186/s42077-023-00369-9

Ain-Shams Journal of Anesthesiology

CASE REPORT

Open Access

Thoracic spinal anaesthesia for paediatric upper extremity surgery in limited-resource hospital: a case report

Agus Prima[1*], Tasrif Hamdi[2], John Frans Sitepu[2], Imam Ghozali[3] and Asmin Lubis[2]



The patient was placed supine position on the operating table and placed lead electrocardiography, pulse oximeter, and blood pressure cuff. His vital signs are stable. While the patient was held seated, a 27-gauge Quincke-Babcock spinal needle was inserted paramedian under aseptic conditions in the T3–T4 intervertebral spaces. After removing the obturator stylet, the Quincke-Babcock needle is advanced slowly until the cerebrospinal fluid appears (Fig. 2). Hyperbaric bupivacaine (0.75%; 5 mg) is injected in the subarachnoid space in 30 s with a barbotage one time. Hemodynamically stable and no hemodynamic changes after C4 block is achieved. After the sensory block is achieved, the patient can still move both hands, with muscle strength grading 3 (movement against gravity only), but the sensory is completely blocked. The patient is performed remove of implant and the duration of the procedure during 1 h. During surgery hemodynamically stable with SBP in the range 110–120, and HR 60–75 bpm.



CASE REPORT ASIAN JOURNAL OF MEDICAL SCIENCES

Thoracic segmental spinal anaesthesia for laparoscopic cholecystectomy in a case of birt-hogg-dube syndrome

Tushar Kanti Ghosh[1], Purbasha Roy[2]

[1]Senior Consultant, Department of Anaesthesiology, Manipal Hospital, Kolkata, West Bengal, India, [2]Senior Registrar, Department of Anaesthesiology, Manipal Hospital, Kolkata, West Bengal, India

Procedure was performed in sitting position. Epidural needle (18G Tuohy needle) was inserted at T9-T10 intervertebral space by paramedian approach. Catheter introduced and fixed at 9 cm. Spinal needle (26G Quincke needle) was inserted at T10-T11 intervertebral space by paramedian technique without any discomfort or paresthesia. After confirming free flow of CSF, 10 mg of Inj. Levobupivacaine 0.5% plus Inj. Fentanyl 25 mcg was injected and the patient was made supine. Sensory block was achieved from T4 to L2 dermatomes within 5 min with little weakness in the lower limbs.

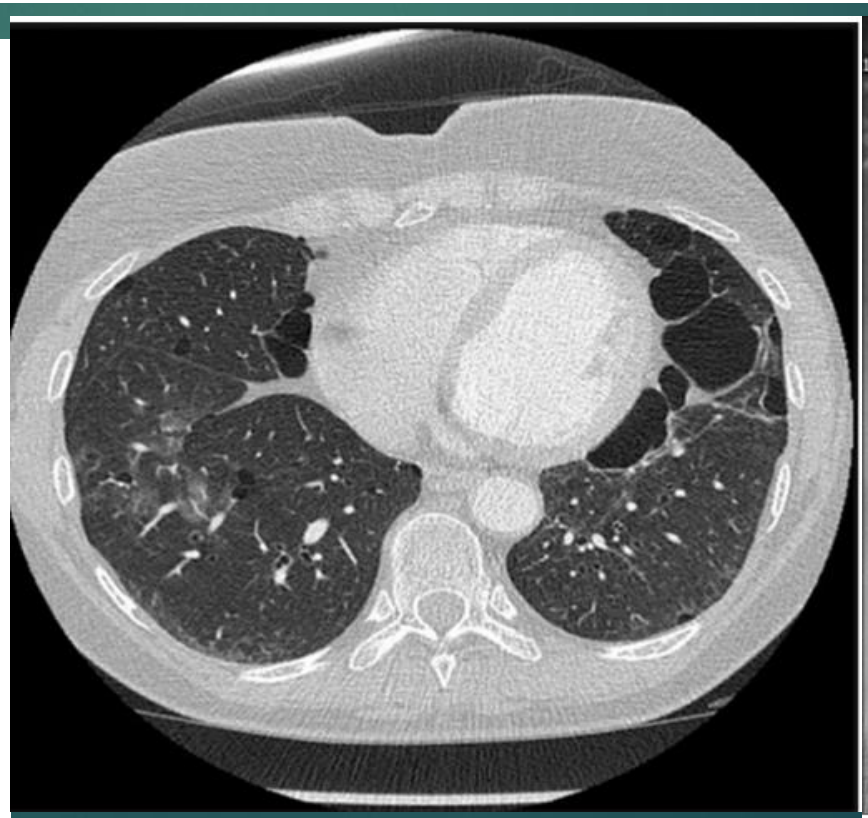



The novel use of spinal anesthesia at the mid-thoracic level: a feasibility study

Ahmed Abdelaal Ahmed Mahmoud[a], Hazem Abdelwahab Hussein[a], Karim Girgis[b], Ahmed Mostafa Kamal[b], Hesham Ahmed Nafady[a]

[a]Department of Anesthesiology, Faculty of Medicine, Beni Suef University [b]Department of Anesthesiology, Faculty of Medicine, Cairo University, Cairo, Egypt

Correspondence to Ahmed Abdelaal Ahmed Mahmoud, MD, Department of Anesthesiology, Faculty of Medicine, Beni Suef University, Flat 1103, 39 Mousa ebn Nousir Street, 7th District, Nasr City, Cairo 11471, Egypt

Background

Breast surgery is commonly performed in geriatric patients. In this age group, patients commonly suffer from comorbidities, making regional anesthesia the preferred option during surgery. Recently, segmental thoracic spinal anesthesia for laparoscopic cholecystectomy was tried successfully. Anatomical studies showed that the posterior dural–spinal cord distance is wider at the mid-thoracic region. This encouraged us to test the feasibility of performing spinal anesthesia at the mid-thoracic level for surgeries in the thoracic region, namely breast surgery.

We performed a prospective feasibility trial including 25 patients, American Society of Anesthesiologists-I (ASA-I), undergoing minor breast surgery (lumpectomy or simple mastectomy) under segmental thoracic spinal anesthesia at T5 level with 1 ml plain bupivacaine (5 mg/ml) and 0.3 ml fentanyl (50 μg/ml). We assessed the number of attempts required, paresthesia during needle insertion, sensory block level, need for supplemental analgesics or general anesthesia, and block-related complications. Hemodynamics as well as patient satisfaction were also recorded.

Table 3 Anesthetic outcome

Sensory block	
Adequate block level achieved (from T2 to T6)	25 (100)
Time to achieve adequate block level	
At 10 min	14 (56)
At 15 min	11 (44)
Upper level of block reached at 15 min	T1 (T1–T2)
Lower level of block reached at 15 min	T11 (T11–T12)
Motor block	
Number of patients with Bromage scale >0	
Before surgery	0 (0)
After surgery	0 (0)
Number of patients with ESSAM score >0	
Before surgery	4 (16)
After surgery	3 (12)
Duration of surgery (min)	61 (45–80)
Time to full block regression (min)	157 (140–190)
Need for intraoperative analgesia	0 (0)
Need for epidural injection	0 (0)
Need for general anesthesia	0 (0)
Complications	
Intraoperative	
Hypotension	4 (16)
Bradycardia	0 (0)

Korean J Anesthesiol 2009 Mar; 56(3): 330-3
DOI: 10.4097/kjae.2009.56.3.330

☐ Case Report ☐

Laparoscopic cholecystectomy performed under regional anesthesia in patient who had undergone pneumonectomy

— A case report —

Department of Anaesthesiology and Pain Medicine, East-West Neo Medical Center, College of Medicine, Kyung Hee University, Seoul, Korea

Jae-Woo Yi, Soo-Eun Choi, and **Jun-Young Chung**

Seventy-one years old, ASA physical status III, male patient underwent laparoscopic cholecystectomy due to acute cholecystitis with gall bladder (GB stone). He had undergone right pneumonectomy nine years ago. Moderate obstructive and restrictive pattern was found on PFT and hypokinesia of apical anterior and septum segments was seen on echocardiography. Due to patient's refusal of receiving general anesthesia, we decided to perform regional anesthesia. Epidural catheter was inserted at 10th thoracic intervertebral space and segmental spinal anesthesia was performed at L2-L3 intervertebral space with 5 mg of hyperbaric bupivacaine 0.5% and 20 ug of fentanyl. A segmental sensory block, extending from T3 through L2 dermatomes, was obtained. Surgery was performed smoothly and uneventfully. Patient discharged from hospital at 3 days after surgery. **(Korean J Anesthesiol 2009; 56: 330~3)**

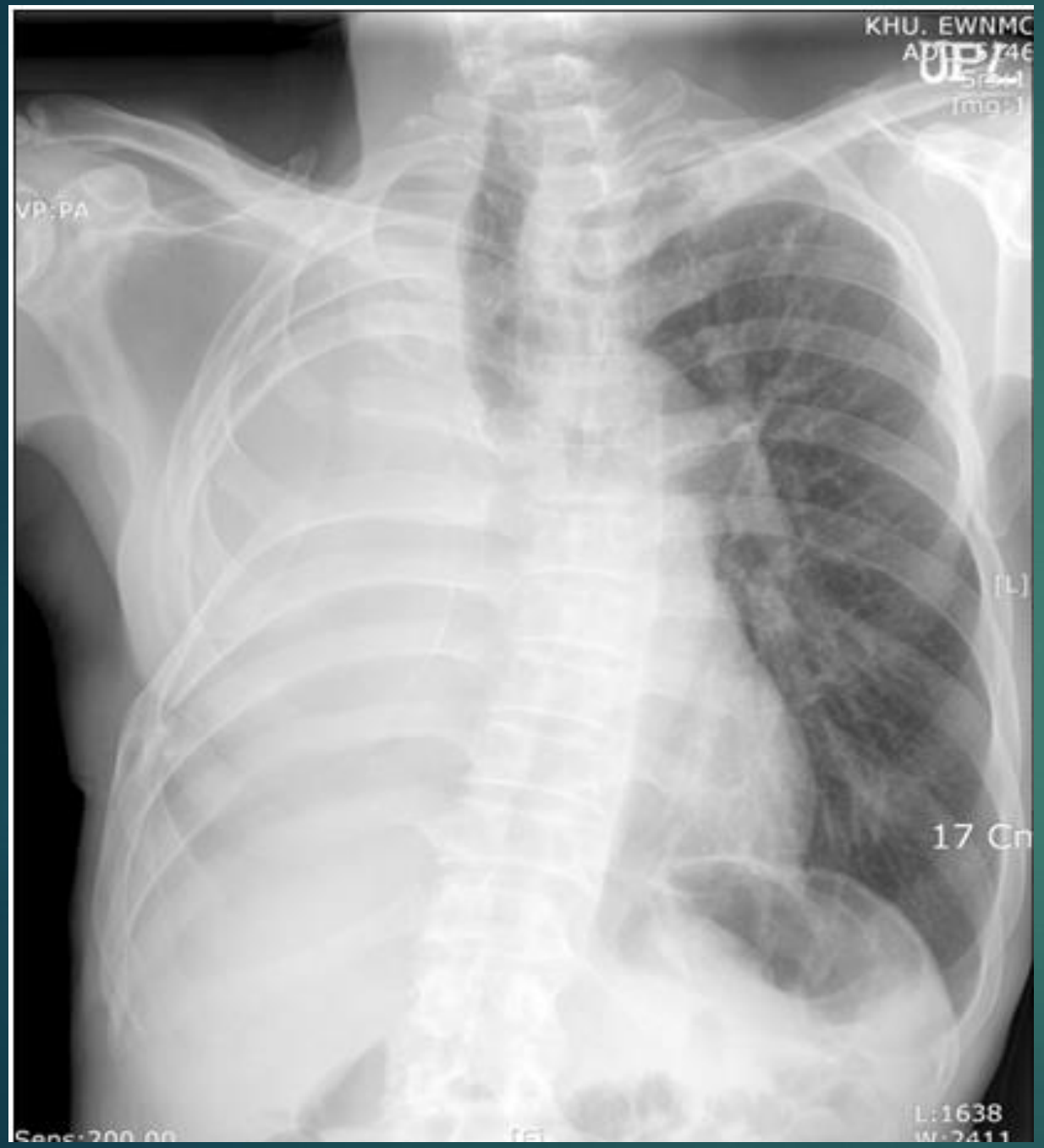
KHU. EWNMC
VP:PA
[L]
17 Cm
L:1638

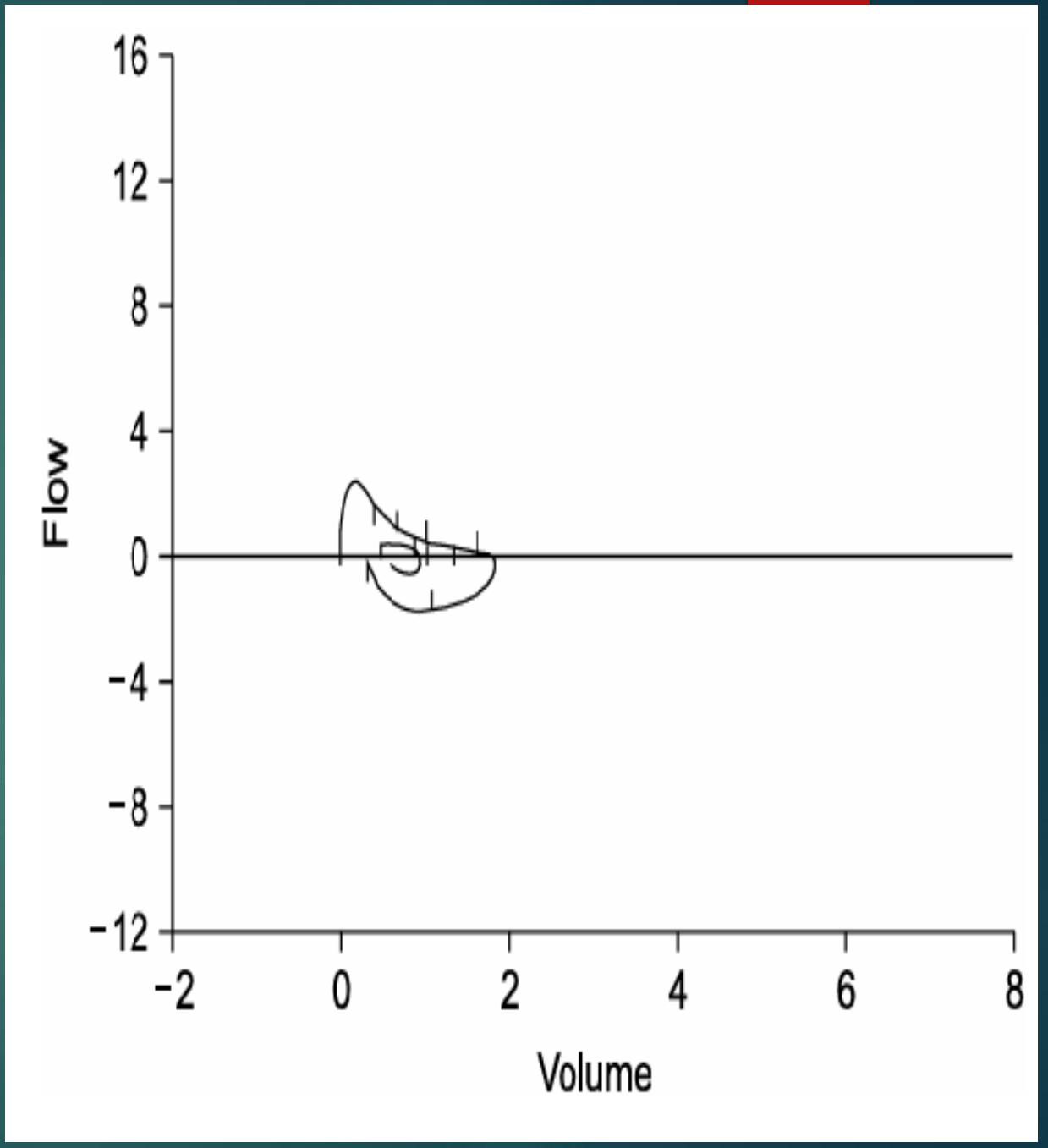
16
12
8
4
0
-4
-8
-12
Flow
-2
0
2
4
6
8
Volume



Thoracic Surgery: T5-T6			
Surgical procedure	**TSA needle insertion level**	**LA volume range**	**Sensory level**
Breast surgery[22, 51, 54]	T5-T6	1.1-1.4 ml	T1-T12

Upper Abdominal Surgery: T4-T11			
Surgical procedure	**TSA needle insertion level**	**LA volume range**	**Sensory level**
Colon resection[46]	T4-T5	1.7 ml	T3-L5
Gastrectomy[25]	T6-T8	0.9-1.2 ml	T4
Gastrostomy[18]	T8-T9	1 ml	T3-T12
Laparoscopic cholecystecto-my[20, 24, 26, 28, 31, 48, 49, 52, 56, 57]	T8-T11	1.5-2.5 ml	T2-L5
Laparotomy for other abdominal malignancies[23]	T9-T10	2 ml	T2-L3

Lower Abdominal Surgery: T8-T11			
Surgical procedure	**TSA needle insertion level**	**LA volume range**	**Sensory level**
Caesarean delivery[17]	T8-T9	1.4 ml	T4-L2
Cystectomy[29]	T10-T11	1 ml	T6-L2
Nephrectomy[30, 50]	T10-T11	1.3-2 ml	T3-T12

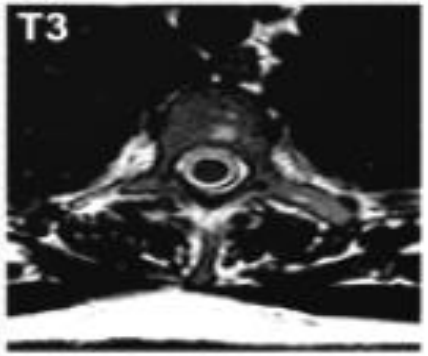

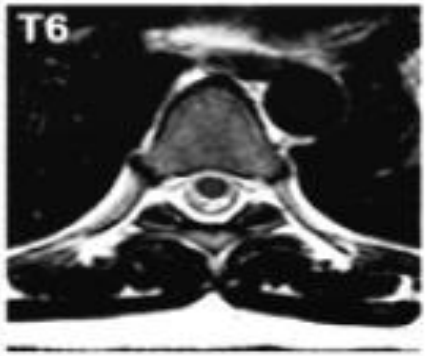



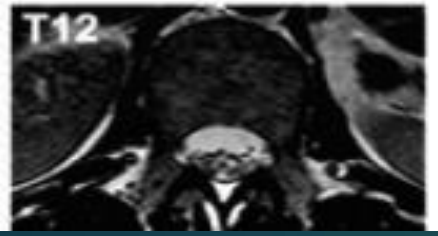



Supine	
T1	2.7 (0.85)mm
T6	3.75 (1.5)mm
T9	2.45 (0.6)mm

Lateral	
T1	4.27(1.8)mm
T6	4.45 (1.1)mm
T9	2.4(0.78)mm

Sitting	
T1	4.6 (1.3)mm
T6	5.95 (1.9)mm

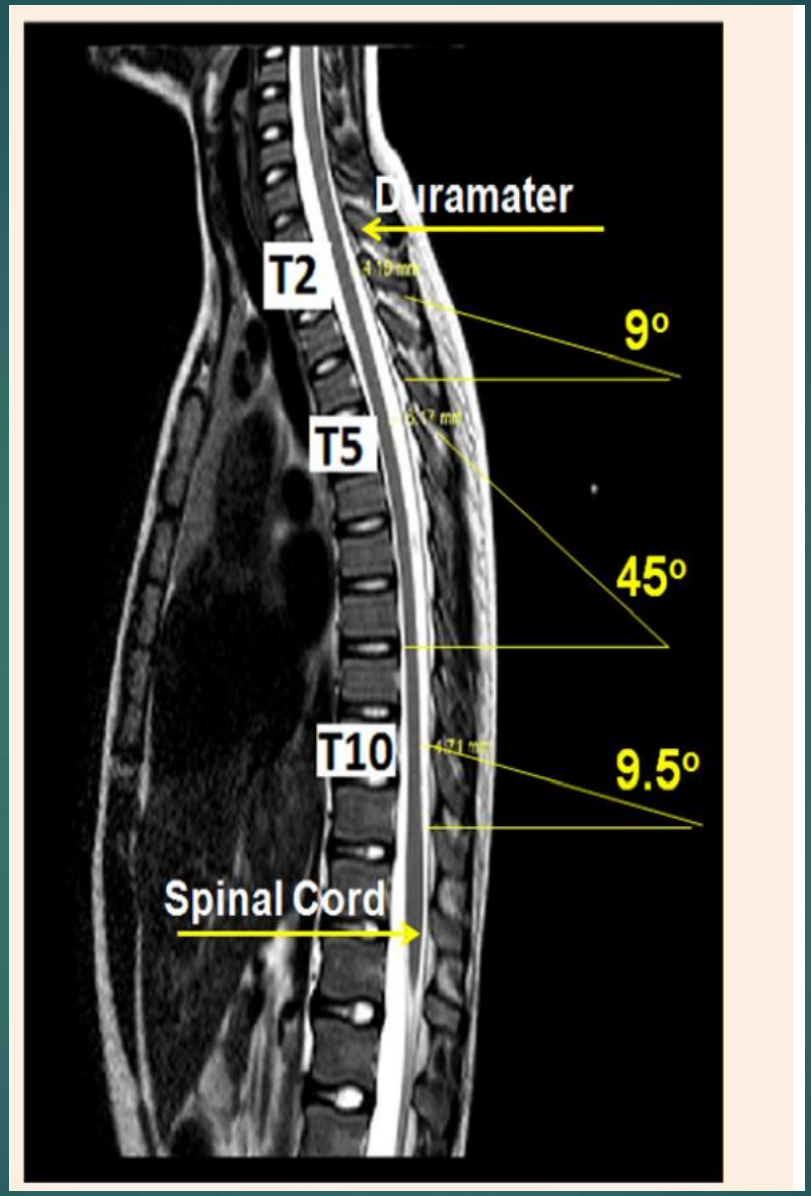
Duramater
T2
9°
T5
45°
T10
9.5°
Spinal Cord

Direct Spinal Cord Injury

- The incidence of direct needle-related spinal cord injury in TSSA remains unknown. The largest series identified reported no neurological sequelae in 1,406 lower-thoracic spinal anesthetics. Available studies are insufficient to quantify this risk



Thank You Very Much

For Your

Attention!!



Hamdi et al. — TSSA for Breast Surgery: A Systematic Review and Meta-analysis. Narra J, 2025.

Paliwal et al. — Segmental Thoracic Spinal Anesthesia versus General Anesthesia for Breast Cancer Surgery. J Anaesthesiol Clin Pharmacol, 2022

Verma et al. — Isobaric versus Hyperbaric Levobupivacaine in TSSA for Laparoscopic Cholecystectomy. Cureus, 2024