18TH INTERNATIONAL CONGRESS OF ANESTHESIOLOGY, CRITICAL CARE AND PAIN

Pediatric Airway Challenges: Modern Techniques in Difficult Airway Management

Amir Shafa. MD

Associate Professor, Isfahan University of Medical Sciences

18–20 November 2026 · Tehran, Iran · From Innovation to Resilience

About the Speaker



- Amir Shafa, MD
- Pediatric Anesthesiologist
- Associate Professor

  Isfahan University of Medical Sciences

Why the child's airway is different

- Anatomy:
- Large occiput and tongue; relatively small mandible
- Anterior, cephalad larynx; long, floppy, omega-shaped epiglottis
- Narrowest point at the cricoid ring: small tubes, small margin
- Obligate nasal breathing in neonates and young infants
- Small edema = large rise in resistance

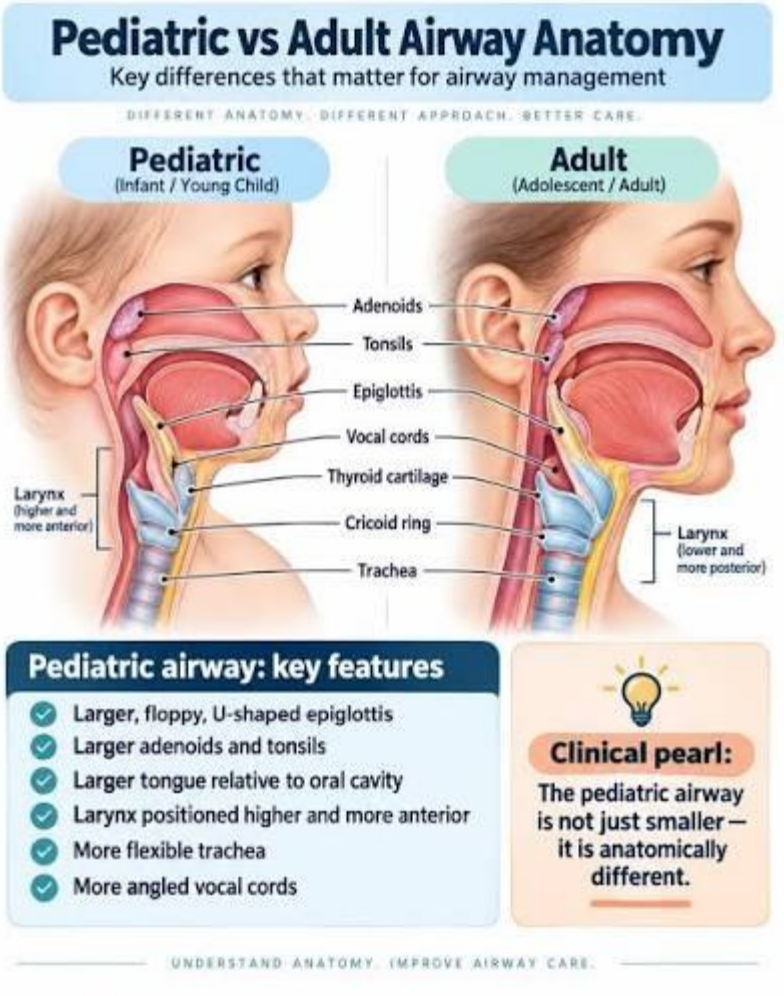

PHYSIOLOGY

• Less reserve, faster desaturation

- High oxygen consumption relative to body weight
- Low functional residual capacity
- early airway closure
- Desaturation within seconds of apnea, especially in infants
- Bradycardia is the first sign of hypoxia: oxygen before everything
- Laryngospasm and gastric insufflation worsen both

Poiseuille's law in airways

$$R = 8\eta L / \pi r^4$$

3.2×

Resistance, radius down 25%

16×

Resistance, radius down 50%

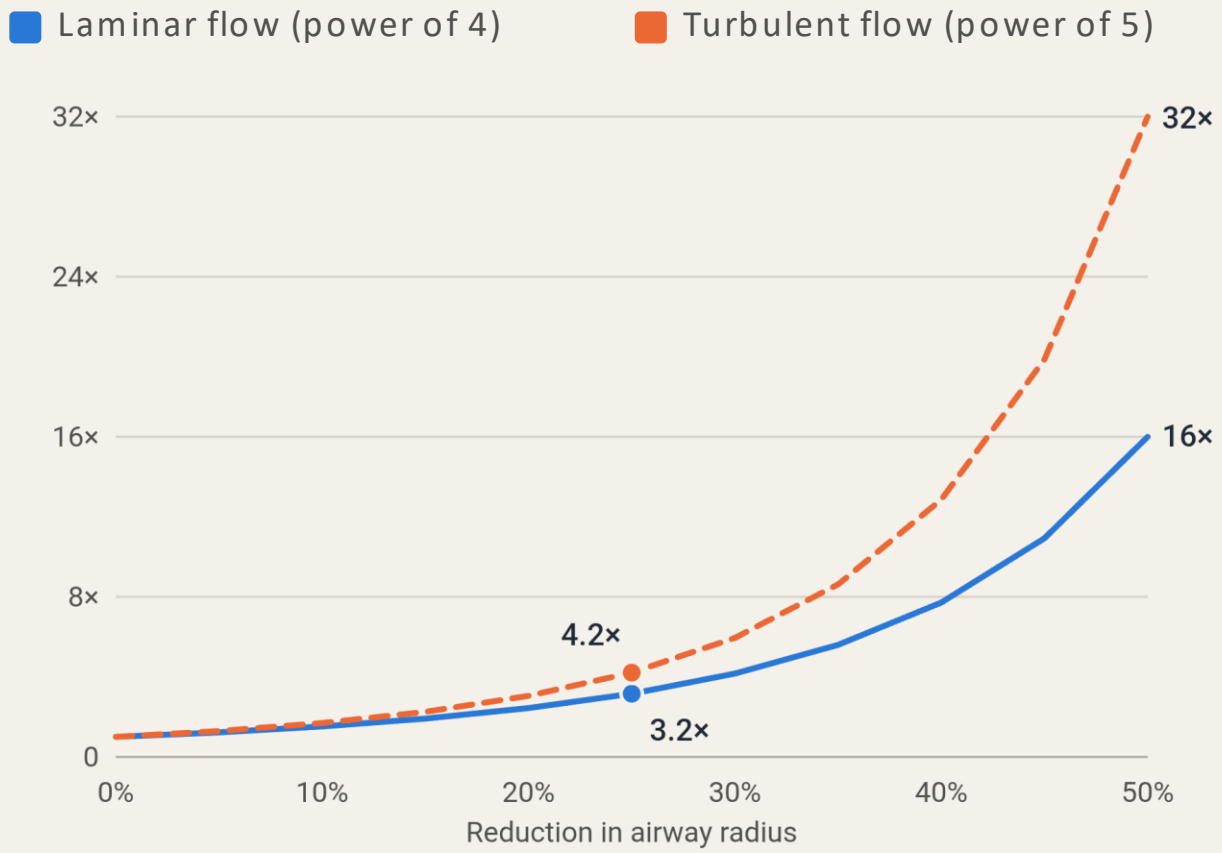

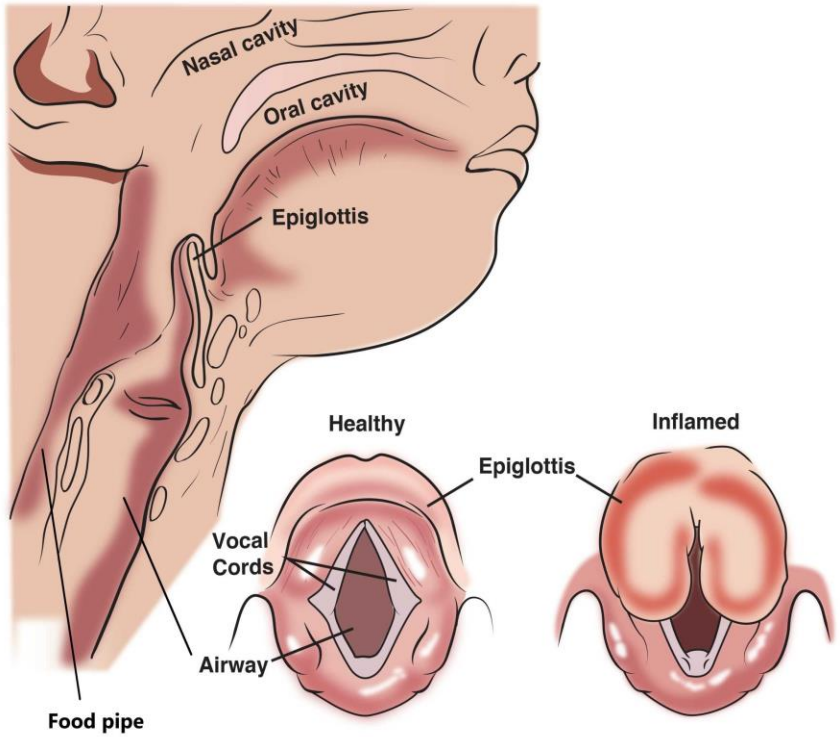

Croup
(Laryngotracheobronchitis)

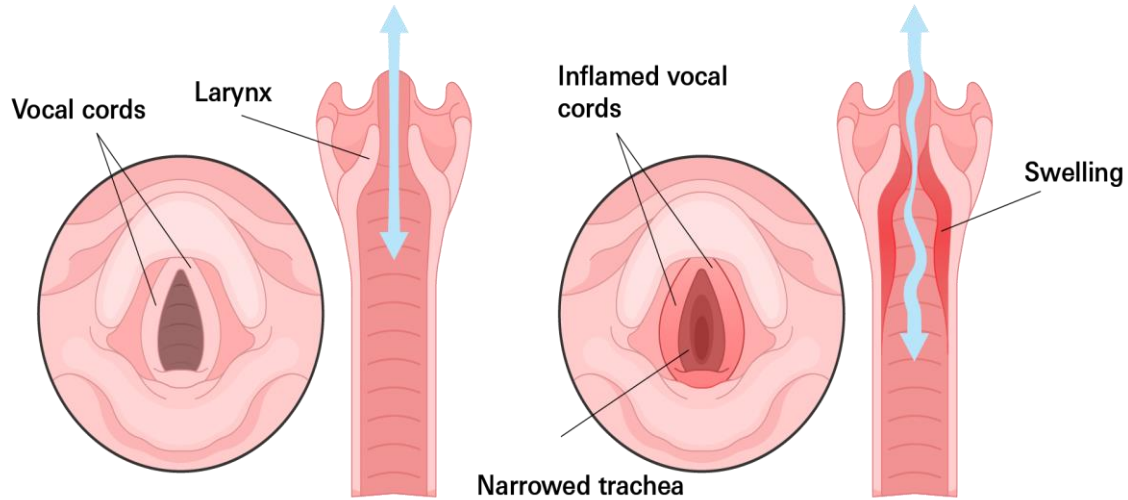

Predictors of Difficult Pediatric Airway

Congenital Syndromes

Pierre Robin, Treacher Collins, Goldenhar, Apert, Crouzon, Down syndrome

History Clues

Prior difficult intubation, OSA, snoring, recurrent croup, failed prior attempts

Acquired Conditions

Burns, trauma, infection (epiglottitis, croup), tumors, previous surgery

Red Flags

Stridor at rest, drooling, tripod posture, oxygen requirement, recent airway instrumentation

Physical Findings

Micrognathia, limited mouth opening, short neck, macroglossia, facial asymmetry

Situational

Emergency vs elective, full stomach, limited equipment, inexperienced team










VOICESURGEON.NET











What makes an airway difficult?

- Difficult mask ventilation
- Difficult laryngoscopy: poor view despite optimal technique
- Difficult intubation: multiple attempts or operators
- Failed airway: cannot intubate and cannot ventilate
- Many pediatric difficult airways are unanticipated

PLANNING

Before induction

- Explicit Plan A, B, C and D, stated aloud to the team
- Most experienced anesthesiologist and surgeon available
- Difficult airway cart and videolaryngoscope in the room
- ENT ready for front-of-neck access when risk is high
- Decide: awake-equivalent, spontaneous breathing or paralysis

Difficult Airway Cart — Pediatric Essentials



Airway Devices

- Age-appropriate VL blades
- Flexible scopes (2.2–4 mm)
- SGA sizes 1–3 (2nd gen)
- Stylets & bougies
- Optical stylets

Oxygenation

- High-flow nasal cannula
- Mapleson circuits
- Appropriate masks
- Oral/nasal airways
- Suction (Yankauer + catheters)

Surgical / Rescue

- Scalpel + bougie set
- Cricothyroidotomy kits
- Tracheostomy tubes
- Jet ventilation (if trained)
- Emergency drugs

Video Laryngoscopy in Children

C-MAC / GlideScope

Standard & hyperangulated blades; excellent for teaching and shared view



McGrath MAC

Lightweight; disposable blades; good for neonates to adolescents



Airtraq / King Vision

Channelled options; useful when stylet manipulation is difficult



Pediatric-specific

Storz C-MAC Miller, infant blades, and flexible tip designs












Airtraq



Flexible Fiberoptic / Video Bronchoscopy

Indications

- Known difficult airway (syndromes)
- Limited mouth opening
- Cervical spine instability
- Airway masses or stenosis
- Awake or sedated intubation
- Confirmation of tube position

Practical Tips

- Use appropriate scope size (2.2–4.0 mm)
- Lubricate and preload the ETT
- Maintain spontaneous ventilation when possible
- Have suction and oxygen ready
- Practice on manikins regularly
- Combine with video laryngoscopy (hybrid)

Supraglottic Airways (SGAs)

Second-generation devices preferred for rescue and planned use

i-gel



Cuffless; quick insertion; good seal; conduit for intubation

LMA ProSeal / Supreme



Gastric channel; higher seal pressures; pediatric sizes available

Air-Q / air-Qsp



Designed as intubation conduit; removable connector

Classic LMA



Still useful; first-generation; limited gastric protection

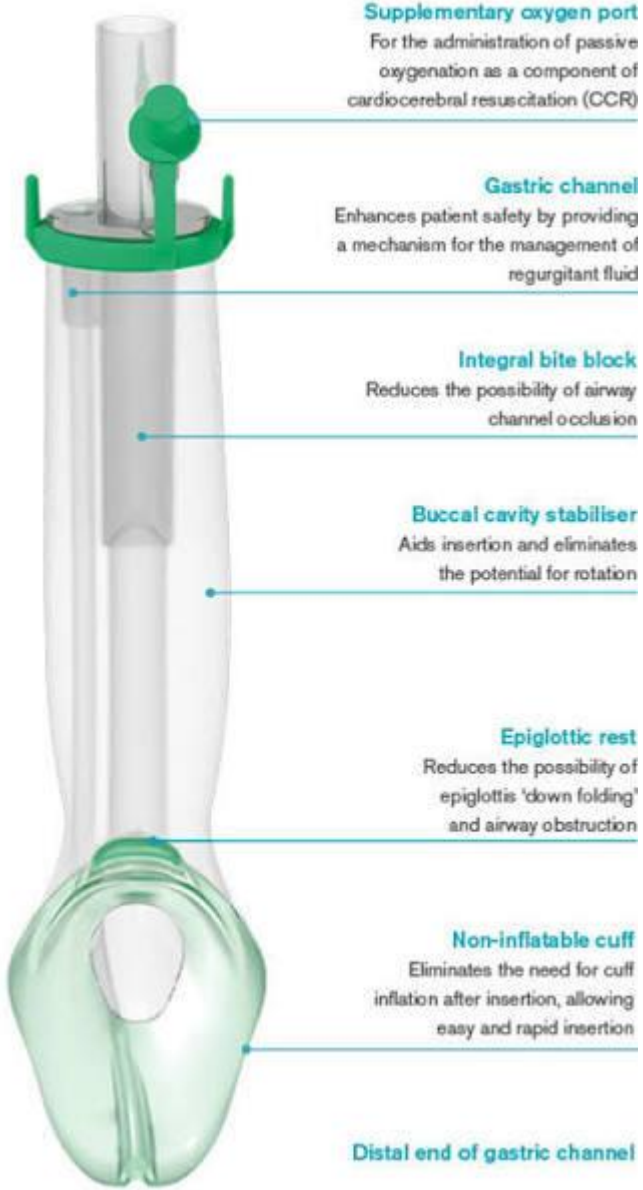

Supplementary oxygen port
For the administration of passive oxygenation as a component of cardiocerebral resuscitation (CCR)

Gastric channel
Enhances patient safety by providing a mechanism for the management of regurgitant fluid

Integral bite block
Reduces the possibility of airway channel occlusion

Buccal cavity stabiliser
Aids insertion and eliminates the potential for rotation

Epiglottic rest
Reduces the possibility of epiglottis 'down folding' and airway obstruction

Non-inflatable cuff
Eliminates the need for cuff inflation after insertion, allowing easy and rapid insertion

Distal end of gastric channel



ULTRASOUND

Point-of-care ultrasound in the airway

- Identify the cricothyroid membrane before induction in high-risk cases
- Estimate subglottic diameter and tube size
- Confirm tracheal versus esophageal placement
- Assess gastric content and volume

TECHNIQUE

Spontaneous breathing or neuromuscular blockade?

- Inhalational induction keeps ventilation and depth under control
- Maintain spontaneous breathing when obstruction is expected
- Rocuronium with sugammadex available lowers the stakes of paralysis
- Avoid repeated attempts at light anesthesia
- Choose, state, and share the decision with the team

Oxygenation First — Always

In children, the safe apnea time is measured in seconds, not minutes.
Prioritize continuous oxygenation over securing the definitive airway.

Preoxygenation

High-flow nasal cannula or tight mask; aim for EtO_2 > 90%

Apneic Oxygenation

Continue O_2 via nasal cannula or THRIVE during laryngoscopy

Two-Person Mask

Jaw thrust + oral airway; second operator bags

Limit Attempts

Maximum 2–3 intubation attempts before moving to next plan

Difficult mask ventilation (MV) – during routine induction of anaesthesia in a child aged 1 to 8 years

Difficult MV → **Give 100% oxygen** → **Call for help**

Step A Optimise head position

Consider:
- Adjusting chin lift/jaw thrust
- Inserting shoulder roll if <2 years
- Neutral head position if >2 years
- Adjusting cricoid pressure if used
- Ventilating using two person bag mask technique

Check equipment

Consider changing:
- Circuit
- Mask
- Connectors

If equipment failure is suspected, change to self-inflating bag and isolate from anaesthetic machine promptly

Depth of anaesthesia

Consider deepening anaesthesia
Use CPAP

Step B Insert oropharyngeal airway

Call for help again if not arrived

Assess for cause of difficult mask ventilation
- Light anaesthesia
- Laryngospasm
- Gastric distension – pass OG/NG tube

Maintain anaesthesia/CPAP
Deepen anaesthesia (Propofol first line)
- If relaxant given – intubate
- If intubation not successful, go to unanticipated difficult tracheal intubation algorithm

Step C Second-line: Insert SAD (e.g. LMA™)

- Insert SAD (e.g. LMA™) – **not > 3 attempts**
- Consider nasopharyngeal airway
- Release cricoid pressure

Good airway

Yes → **Continue**

No

SpO_2 >80%

Consider:
- SAD (e.g. LMA™) malposition/blockage
- Equipment malfunction
- Bronchospasm
- Pneumothorax

→ **Wake up patient**

SpO_2 <80%

Attempt intubation
- Consider paralysis

Succeed → **Proceed**

Fail → **Go to scenario cannot intubate cannot ventilate (CICV)**

Unanticipated difficult tracheal intubation – during routine induction of anaesthesia in a child aged 1 to 8 years

Difficult direct laryngoscopy → **Give 100% oxygen and maintain anaesthesia** → **Call for help**

Step A Initial tracheal intubation plan when mask ventilation is satisfactory

Ensure: Oxygenation, anaesthesia, CPAP, management of gastric distension with OG/NG tube

Direct laryngoscopy – **not > 4 attempts**

Check:

- Neck flexion and head extension
- Laryngoscopy technique
- External laryngeal manipulation – remove or adjust
- Vocal cords open and immobile (adequate paralysis)

If poor view – consider bougie, straight blade laryngoscope* and/or smaller ETT

→ **Succeed** → Tracheal intubation → Verify ETT position

- Capnography
- Visual if possible
- Ausculation

If ETT too small consider using throat pack and tie to ETT

If in doubt, take ETT out

→ **Failed intubation with good oxygenation**

Step B Secondary tracheal intubation plan

Call for help again if not arrived

- Insert SAD (e.g. LMA™) – **not > 3 attempts**
- Oxygenate and ventilate
- Consider increasing size of SAD (e.g. LMA™) once if ventilation inadequate

→ **Succeed** →

- Consider modifying anaesthesia and surgery plan
- Assess safety of proceeding with surgery using a SAD (e.g. LMA™)

→ **Unsafe** → **Postpone surgery Wake up patient**

→ **Safe** → **Proceed with surgery**

→ **Safe** →

- **Consider 1 attempt at FOI via SAD (e.g. LMA™)**
- Verify intubation, leave SAD (e.g. LMA™) in place and proceed with surgery

→ **Succeed** → **Proceed with surgery**

→ **Failed intubation via SAD (e.g. LMA™)** → **Postpone surgery Wake up patient**

→ **Failed oxygenation e.g. SpO_2 <90% with FiO_2 1.0**

- Convert to face mask
- Optimise head position
- Oxygenate and ventilate
- Ventilate using two person bag mask technique, CPAP and oro/nasopharyngeal airway
- Manage gastric distension with OG/NG tube
- Reverse non-depolarising relaxant

→ **Succeed** → **Postpone surgery Wake up patient**

→ **Failed ventilation and oxygenation** → **Go to scenario cannot intubate cannot ventilate (CICV)**

B

Following intubation attempts, consider • Trauma to the airway • Extubation in a controlled setting

*Consider using indirect larygoscope if experienced in their use

SAD = supraglottic airway device

Cannot intubate and cannot ventilate (CICV) in a paralysed anaesthetised child aged 1 to 8 years

Failed intubation inadequate ventilation → **Give 100% oxygen** → **Call for help**

Step A Continue to attempt oxygenation and ventilation

- FiO_2 1.0
- Optimise head position and chin lift/jaw thrust
- Insert oropharyngeal airway or SAD (e.g. LMA™)
- Ventilate using two person bag mask technique
- Manage gastric distension with an OG/NG tube

Step B Attempt wake up if maintaining SpO_2 >80%

If rocuronium or vecuronium used, consider sugammadex (16mg/kg) for full reversal

Prepare for rescue techniques in case child deteriorates

Step C Airway rescue techniques for CICV (SpO_2 <80% and falling) and/or heart rate decreasing

Call for help again if not arrived

Call for specialist ENT assistance

ENT available → Consider:
- Surgical tracheostomy
- Rigid bronchoscopy + ventilate / jet ventilation (pressure limited)

ENT not available → Percutaneous cannula cricothyroidotomy / transtracheal jet ventilation (pressure limited)

- **Succeed** → Continue jet ventilation set to lowest delivery pressure until wake up or definitive airway established
- **Fail** → Perform surgical cricothyroidotomy / transtracheal and insertion of ETT / tracheostomy tube*
  - Consider passive O_2 insufflation while preparing

C

*Note: Cricothyroidotomy techniques can have serious complications and training is required – only use in life-threatening situations and convert to a definitive airway as soon as possible

Cannula cricothyroidotomy

- Extend the neck (shoulder roll)
- Stabilise larynx with non-dominant hand
- Access the cricothyroidotomy membrane with a dedicated 14/16 gauge cannula
- Aim in a caudad direction
- Confirm position by air aspiration using a syringe with saline
- Connect to either:
  - adjustable pressure limiting device, set to lowest delivery pressure

  or
  - 4Bar O_2 source with a flowmeter (match flow l/min to child's age) and Y connector
- Cautiously increase inflation pressure/flow rate to achieve adequate chest expansion Wait for full expiration before next inflation
- Maintain upper airway patency to aid expiration

SAD = supraglottic airway device

Thank You for Your Attention

amir_shafa@med.mui.ac.ir